



ELSEVIER

Contents lists available at ScienceDirect

Pediatric Neurology

journal homepage: www.elsevier.com/locate/pnu

Clinical Observations

Moyamoya Syndrome in a Patient With Noonan-like Syndrome With Loose Anagen Hair



Jin-Ho Choi MD^{a,1}, Moon-Yeon Oh MD^{a,1}, Mi-Sun Yum MD^a, Beom Hee Lee MD^a,
Gu-Hwan Kim PhD^b, Han-Wook Yoo MD, PhD^{a,b,*}

^a Department of Pediatrics, Asan Medical Center Children's Hospital, University of Ulsan College of Medicine, Seoul, Korea

^b Medical Genetics Center, Asan Medical Center Children's Hospital, University of Ulsan College of Medicine, Seoul, Korea

ABSTRACT

BACKGROUND: Noonan-like syndrome with loose anagen hair is one of the RASopathies characterized by Noonan syndrome-like features with unique ectodermal abnormalities. This syndrome is caused by mutations in the *SHOC2* gene. We encountered a patient with moyamoya syndrome associated with Noonan-like syndrome with loose anagen hair presenting with transient ischemic attacks. **PATIENT DESCRIPTION:** A 6-year-old girl was diagnosed with Noonan-like syndrome with loose anagen hair because of profound short stature and ectodermal anomalies such as sparse and easily pluckable hair. A heterozygous mutation of c.4A>G (p.S2G) in the *SHOC2* gene was identified, and recombinant human growth hormone therapy was initiated at 8 years of age. At age 10, she manifested recurrent left hemiplegia. Moreover, cerebrovascular imaging revealed occlusion or narrowing of both internal carotid arteries and both middle cerebral arteries with distal moyamoya-like vessels. She is treated with aspirin and calcium channel blocker. **CONCLUSIONS:** We describe the first case of Noonan-like syndrome with loose anagen hair associated with moyamoya syndrome, although it has been reported to be associated with a few cases of other RASopathies, including Noonan, cardiofaciocutaneous, and Costello syndromes. This report emphasizes the associations between cerebrovascular anomalies and Noonan-like syndrome with loose anagen hair.

Keywords: Noonan-like syndrome with loose anagen hair, Moyamoya syndrome, Noonan syndrome, *SHOC2*

Pediatr Neurol 2015; 52: 352-355

© 2015 Elsevier Inc. All rights reserved.

Introduction

Since Noonan syndrome was first described by Noonan in 1968,¹ great advances in molecular technology have enabled the identification of the genetic etiologies of Noonan syndrome and its related disorders.² These pathologies are caused by germline mutations in genes involved in the RAS/mitogen-activated protein kinase (MAPK) signaling cascade. Thus, these disorders are referred to as "RASopathies."³ In 2003, Mazzanti et al.⁴

reported Noonan-like syndrome with loose anagen hair (NS/LAH) (Online Mendelian Inheritance in Man 60772) characterized by Noonan-like features, including retarded growth, neurocognitive deficit, and cardiac defects as well as a unique pattern of ectodermal abnormalities, such as easily pluckable, slow-growing, thin, and sparse hair. The LAH syndrome (Online Mendelian Inheritance in Man 600628) is a distinctive hair disorder that usually occurs as an isolated disorder or rarely in association with other genetic conditions.⁵ Patients with NS/LAH have short, blond, fine-textured, sparse, easily pluckable, and slow-growing hair in the anagen phase that lacks inner and outer root sheaths.⁴ LAH is characterized by the complete absence of telogen hair and a high prevalence of anagen hair, the strands of which are mostly in the anagen phase, the active growth phase, when the hair follicles are in a resting state because the hair shafts are lost during the anagen phase.^{4,5} All affected individuals with NS/LAH share the same missense mutation [c.4A>G (p.S2G)] in *SHOC2*.⁶

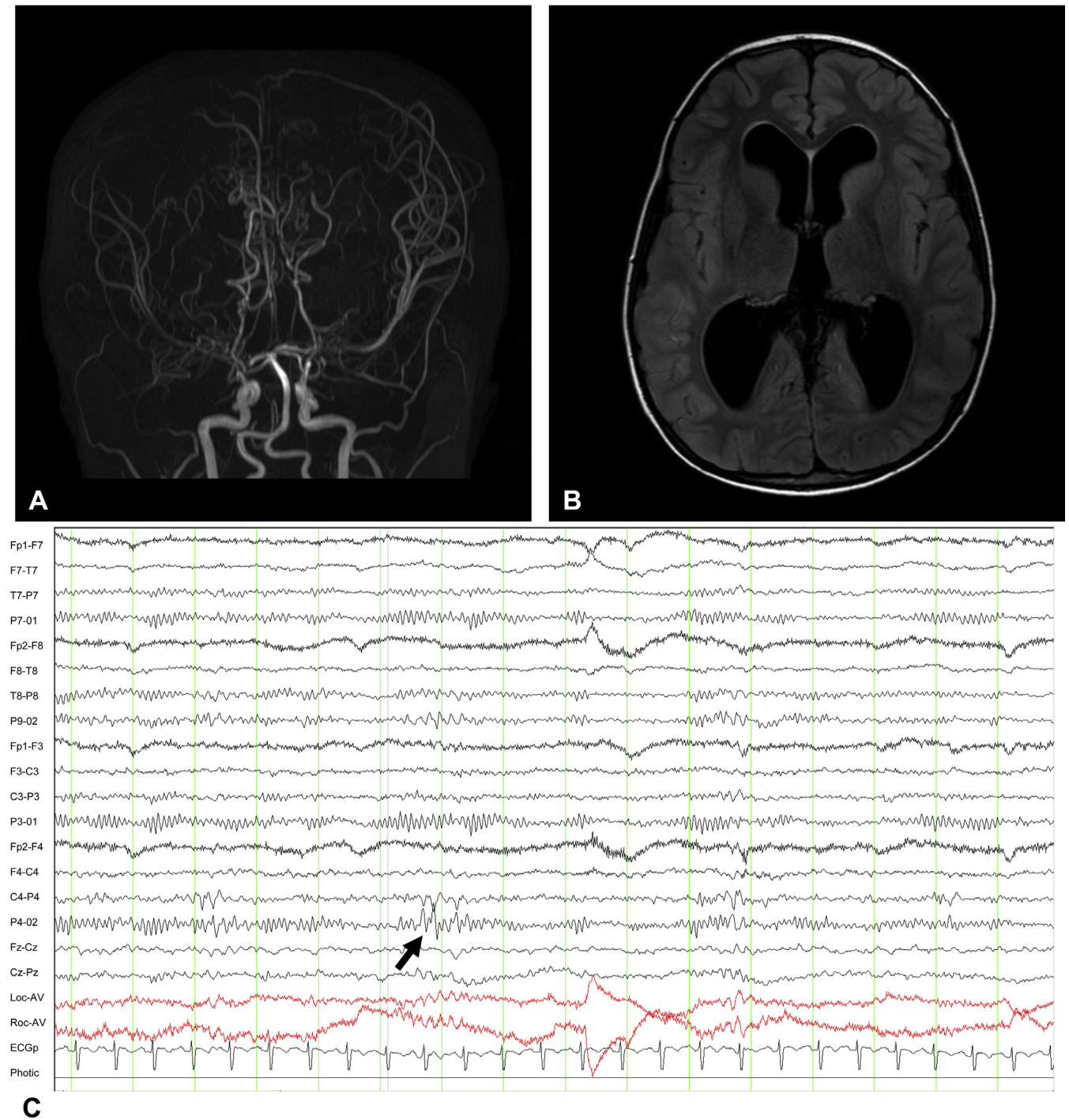
Article History:

Received August 26, 2014; Accepted in final form November 28, 2014

* Communications should be addressed to: Yoo; Department of Pediatrics, Asan Medical Center Children's Hospital; University of Ulsan College of Medicine; 88; Olympic-Ro 43-Gil; Songpa-Gu; Seoul 138-736; Korea.

E-mail address: hwyyoo@amc.seoul.kr

¹Jin-Ho Choi and Moon-Yeon Oh contributed equally to this work.

**FIGURE.**

Findings of brain magnetic resonance (MR) angiography (A) and MR imaging (B). (A) Brain MR angiography showed short segmental nonvisualization of bilateral terminal internal carotid arteries, bilateral proximal middle cerebral arteries, and anterior cerebral arteries, suggesting the narrowing or occlusion of proximal cerebral arteries. Moyamoya-like vessels were evident in the area of the basal perforators and leptomeningeal collateral vessels. (B) Brain MR imaging findings revealed diffuse ventriculomegaly involving both lateral, third, and fourth ventricles. (C) Encephalographic findings of the patient at the time of diagnosis showed several sharp waves from the right parietal area during waking (arrow). (The color version of this figure is available in the online edition.)

Moyamoya syndrome is a progressive occlusive cerebrovascular disease characterized by the bilateral stenosis of the distal internal carotid arteries or their proximal branches, with the eventual development of compensatory collateral vessels.⁷ The idiopathic form of moyamoya vasculopathy is classified as moyamoya disease.⁷ These

features can lead to ischemic stroke, intracranial hemorrhage, headache, seizures, and transient ischemic attacks. Although some cases have been associated with genetic factors in autosomal dominant moyamoya disease, the pathogenesis of moyamoya syndrome remains poorly understood.⁸

TABLE.
Previously Reported Patients With RASopathies and Moyamoya Syndrome

References	Diagnosis	Gene	Age	Sex	Symptoms	Other Features	Medical Treatment	Surgical Treatment	Outcome
This report	NS/LAH	<i>SHOC2</i> p.S2G	10	F	Transient ischemic attacks	ASD, VSD, macrocephaly	Low-dose aspirin	Not yet	Recurrent transient ischemic attacks
Ganesan and Kirkham, 1997 ¹¹	Noonan syndrome	Unknown	9	M	Transient limb weakness, dysarthria	Hydrocephalus, factor V Leiden deficiency, supraaortic stenosis, pulmonary valvular stenosis	Low-dose aspirin → warfarin	Bilateral EDAS	Resolution of symptoms after warfarin
Schuster and Roberts, 1999 ¹²	Noonan syndrome	Unknown	7	F	Transient right-sided weakness, dysarthria	Aortic coarctation	None	Bilateral EDAS	Resolution of symptoms (2 years' follow-up)
Tang et al., 1999 ¹³	Noonan syndrome	Unknown	5	F	Repeated transient ischemic attack	ASD, VSD, pulmonary stenosis	Flunarizine	Not done	Resolution of symptoms
Yamashita et al., 2004 ¹⁴	Noonan syndrome	Unknown	12	F	Headache, right-sided chorea and hypotonia, dysarthria	Antiphospholipid syndrome	Pimozide, aspirin	Not done	Resolution of symptoms (2 years' follow-up)
Hung et al., 2011 ⁹	Noonan syndrome	<i>PTPN11</i> p.G503 R	9	F	Recurrent headache with nausea	ASD	Low-dose aspirin, flunarizine	Not done	Resolution of symptoms (6 months' follow-up)
Ishiguro et al., 2002 ¹⁰	CFC syndrome	Unknown	6.5	M	Transient left hemiplegia, right-sided eye deviation	ASD	Low-dose aspirin	Not done	Resolution of symptoms
Shiihara et al., 2005 ¹⁵	Costello syndrome	Unknown	2	M	No symptoms	Patent ductus arteriosus	Not mentioned	Not mentioned	Not mentioned

Abbreviations:

ASD	= Atrial septal defect
CFC syndrome	= Cardio-facio-cutaneous syndrome
EDAS	= Encephalo-duro-arterio-synangiosis
F	= Female
M	= Male
NS/LAH	= Noonan-like syndrome with loose anagen hair
VSD	= Ventricular septal defect

We recently encountered a child with moyamoya syndrome associated with NS/LAH who presented with transient ischemic attacks. Here, we describe the clinical features, radiological findings, molecular characteristics, and clinical course of this girl and review the previously reported cases.

Patient Description

A 10-year-old girl presented with a transient ischemic attack. She was born at term with a birth weight of 4.0 kg and with no perinatal problems to healthy nonconsanguineous parents. In the neonatal period, small atrial and ventricular septal defects, which later closed spontaneously, were detected by echocardiography. When she reached 1.4 years of age, she presented to an outpatient clinic because of facial dysmorphism, including macrocephaly, hypertelorism, shallow orbital ridge, bitemporal narrowing, and exotropia. Her height, weight, and head circumference were 78.5 cm (−0.72 standard deviation score [SDS]), 12 kg (0.99 SDS), and 52.8 cm (3.74 SDS), respectively. She could sit alone, walk with support, and speak some words. Chromosome analysis and brain magnetic resonance (MR) imaging were normal. She was not followed after age 1.8 years.

At 6.4 years of age, she presented to our institute again because of profoundly short stature (104.9 cm; −2.62 SDS) and macrocephaly (56 cm; 3.44 SDS). Several ectodermal abnormalities, such as sparse, fine textured, blond hair and erythematous papular skin, became evident. By direct sequencing of the *SHOC2* gene, we identified a heterozygous mutation, c.4A>G (p.S2G).

At age 10.2 years, our patient experienced recurrent transient left hemiplegia. Laboratory findings, including complete blood count, chemical battery, and coagulation battery, as well as protein C, protein S, and autoimmune antibodies were all normal. Brain MR angiography demonstrated short, segmental nonvisualization of the bilateral terminal internal carotid arteries and both proximal middle cerebral arteries and anterior cerebral arteries at the circle of Willis. Moreover, moyamoya-like vessels in the area of the basal perforators and leptomeningeal collateral vessels were evident (Figure A). Diffuse ventriculomegaly was also noted by brain MR imaging (Figure B). However, a

ventriculoperitoneal shunt was not required to relieve the hydrocephalus. Electroencephalograph revealed several sharp wave discharges from the right parietal areas (Figure C). The patient was diagnosed with moyamoya syndrome and has since been treated with aspirin and calcium channel blockers. However, encephalo-duro-arterio-synangiosis surgery is planned because of recurrent transient ischemic attacks. Other vascular anomalies such as renal stenosis were not investigated because she did not have hypertension or arterial bruits.

Discussion

Only a few examples of RASopathies associated with moyamoya syndrome have been reported to date, including five individuals with Noonan syndrome and one with Costello and cardio-facio-cutaneous syndromes (Table).^{9–15} Here we describe the first patient with NS/LAH associated with moyamoya syndrome. NS/LAH was first described by Mazzanti et al.⁴ It is characterized by NS-like clinical features and LAH; this condition is also known as Mazzanti syndrome. Our patient had clinical features similar to those of the previously reported NS/LAH cases, such as growth retardation, a cardiac defect, macrocephaly, and LAH.^{2,4,6} In 2009, Cordeddu et al.⁶ sequenced the *SHOC2* gene in 410 subjects with Noonan syndrome or Noonan-related disorders who did not have mutations in the genes that encode the known components of the RAS-MAPK pathway. They identified 21 patients (5.1%) who harbored the p.S2G mutation in the *SHOC2* gene. These patients showed clinical features similar to those of the Mazzanti syndrome, such as growth retardation, cardiac anomalies, cognitive deficits, hyperactive behavior, dark pigmented skin with eczema, and LAH.

In previous studies, cerebrovascular anomalies, such as cavernous malformations, aneurysms, arteriovenous malformations, and intracerebral occlusive artery diseases,

have been reported in patients with Noonan syndrome.⁹ The pathophysiology of cerebrovascular anomalies in RASopathies is unclear. However, previous reports have suggested that alternations in the RAS-MAPK pathway may lead to abnormal cerebrovascular formations, such as moyamoya vessels caused by the disruption of RAF1. Because RAF1 can be activated by the gene product of *SHOC2*, it is a regulatory factor that can play an important role in vascular endothelial cell proliferation and migration, which are the first steps in angiogenesis.¹⁶ During embryogenesis, the origin of the internal carotid arteries and the aortic outlet are closely related. Disrupted vascular development in this region during the prenatal period accounts for both aortic and carotid abnormalities.⁹

Our patient exhibited hydrocephalus without periventricular edema from foramen magnum stenosis. She also had moyamoya syndrome, which has been rarely reported among RASopathies. In a previous report of hydrocephalus with moyamoya syndrome, hydrocephalus with Chiari malformation type I was present before the moyamoya syndrome developed.¹⁶ This finding suggests no direct relationship between moyamoya syndrome and hydrocephalus. The limitations of this report are that the causal relationship between hydrocephalus and moyamoya syndrome was not distinct and that the long-term course was not described.

In conclusion, moyamoya syndrome can be associated with RASopathies such as NS/LAH. Although the relationship between NS/LAH and moyamoya syndrome remains to be elucidated, this syndrome should be considered in patients with RASopathies that present with neurological symptoms such as stroke or transient ischemic attacks.

This study was supported by a grant from the Ministry for Health, Welfare and Family Affairs, Republic of Korea (2011-0019674). None of the authors has conflict of interest to disclose. The authors confirm that they have read the journal's position on issues relating to ethical publication and affirm that this report is consistent with those guidelines.

References

1. Noonan JA. Hypertelorism with Turner phenotype. A new syndrome with associated congenital heart disease. *Am J Dis Child.* 1968;116:373-380.
2. Tartaglia M, Gelb BD, Zenker M. Noonan syndrome and clinically related disorders. *Best Pract Res Clin Endocrinol Metab.* 2011;25:161-179.
3. Tidyman WE, Rauen KA. The RASopathies: developmental syndromes of Ras/MAPK pathway dysregulation. *Curr Opin Genet Dev.* 2009;19:230-236.
4. Mazzanti L, Cacciari E, Cicognani A, Bergamaschi R, Scarano E, Forabosco A. Noonan-like syndrome with loose anagen hair: a new syndrome? *Am J Med Genet A.* 2003;118A:279-286.
5. Tosti A, Piraccini BM. Loose anagen hair syndrome and loose anagen hair. *Arch Dermatol.* 2002;138:521-522.
6. Cordeddu V, Di Schiavi E, Pennacchio LA, Ma'ayan A, Sarkozy A, Fodale V, et al. Mutation of *SHOC2* promotes aberrant protein N-myristoylation and causes Noonan-like syndrome with loose anagen hair. *Nat Genet.* 2009;41:1022-1026.
7. Sébire G, Fullerton H, Riou E, deVeber G. Toward the definition of cerebral arteriopathies of childhood. *Curr Opin Pediatr.* 2004;16:617-622.
8. Scott RM, Smith ER. Moyamoya disease and moyamoya syndrome. *New Engl J Med.* 2009;360:1226-1237.
9. Hung PC, Wang HS, Wong AM. Moyamoya syndrome in a child with Noonan syndrome. *Pediatr Neurol.* 2011;45:129-131.
10. Ishiguro Y, Kubota T, Takenaka J, et al. Cardio-facio-cutaneous syndrome and moyamoya syndrome. *Brain Dev.* 2002;24:245-249.
11. Ganesan V, Kirkham FJ. Noonan syndrome and moyamoya. *Pediatr Neurol.* 1997;16:256-258.
12. Schuster JM, Roberts TS. Symptomatic moyamoya disease and aortic coarctation in a patient with Noonan's syndrome: strategies for management. *Pediatr Neurosurg.* 1999;30:206-210.
13. Tang KT, Yang W, Wong J, Lee KY. Noonan syndrome associated with moyamoya disease: report of one case. *Acta Paediatr Taiwan.* 1999;40:274-276.
14. Yamashita Y, Kusaga A, Koga Y, Nagamitsu S, Matsuishi T. Noonan syndrome, moyamoya-like vascular changes, and antiphospholipid syndrome. *Pediatr Neurol.* 2004;31:364-366.
15. Shiihara T, Kato M, Mitsuhashi Y, Hayasaka K. Costello syndrome showing moyamoya-like vasculopathy. *Pediatr Neurol.* 2005;32:361-363.
16. Zarate YA, Lichty AW, Champion KJ, Clarkson LK, Holden KR, Matheus MG. Unique cerebrovascular anomalies in Noonan syndrome with *RAF1* mutation. *J Child Neurol.* 2013;29:NP13-NP17.