



Case Reports

Agraphia caused by acute right parietal infarction

Manyong Lee^a, Mee Kyung Suh^b, Myung Hyun Lee^a, Jin Soo Lee^a, So Young Moon^{a,*}^a Department of Neurology, Ajou University, School of Medicine, San 5, Woncheon-dong, Yeongtong-gu, Suwon, Kyungki-do 443-721, Republic of Korea^b Department of Neurology, Samsung Medical Center, Seoul, Republic of Korea

ARTICLE INFO

Article history:

Received 20 May 2014

Accepted 21 September 2014

Keywords:

Agraphia
Angular gyrus
Hangul
Parietal
Right
Spatial

ABSTRACT

Injury in the dominant language hemisphere typically leads to agraphia, however we report a patient with agraphia after injury to the right angular gyrus. A 71-year-old Korean woman presented with the complaint of an inability to write for the last 7 days. The patient had been illiterate for most of her life, but had started learning to write Hangul, the Korean alphabet, at a welfare center 3 years ago. On language screening she was unable to write although she could read, and other language functions showed no abnormalities. Brain MRI showed acute infarction in the right angular gyrus. Her writing patterns displayed features of surface agraphia, indicative of phoneme-to-grapheme conversion with phonetic writing of targets. Additionally, she manifested visual errors. A functional MRI indicated that her left hemisphere was language dominant. This patient experienced agraphia resulting from pure impairment of visuo-constructive function after acute infarction in the right angular gyrus.

© 2014 Elsevier Ltd. All rights reserved.

1. Introduction

Agraphia is defined as an acquired spelling and writing disability and may be due to various diseases. Generally, injury in the dominant language hemisphere leads to agraphia, however we report a patient with agraphia after injury to the right angular gyrus.

2. Case report

A 71-year-old Korean woman visited our facility with the complaint of an inability to write (Fig. 1A), which had started 7 days prior. The patient was originally illiterate but had started learning to write Hangul, the Korean alphabet, at a welfare center 3 years prior to presentation. Her abilities were progressing and she was capable of writing without any difficulty up to the time of symptom onset. She was right-handed. Her initial neurologic examination showed alert mental status, normal motor and sensory function, normal cerebellar function, and no focal abnormalities of cranial nerve function. There were no signs of a neglect syndrome. Language screening indicated that she could not write although she was able to read, and other language functions showed no abnormalities. Brain MRI showed acute infarction in the right angular gyrus (Fig. 1B).

Neuropsychological testing revealed disabilities in visuo-constructive function, including visual memory. Detailed language evaluation determined that she was suffering from agraphia alone, without abnormalities in the other language domains, including reading. A presumptive diagnosis of crossed agraphia, due to a dominant right-sided language hemisphere, or visuo-constructive

dysfunction was made since writing Hangul, the Korean alphabet, requires visuo-constructive function. We performed a diagnostic writing test to evaluate the linguistic and visual aspects of writing Hangul, and also determined the patient's dominant hemisphere through functional MRI (fMRI).

Her writing patterns displayed features of surface agraphia, and were indicative of phoneme-to-grapheme conversion with targets written as they sound. The patient displayed visual errors as well as an untidy style of writing post-infarction. The fMRI results clearly indicated that her language dominant hemisphere was the left hemisphere (Supp. Fig. 1).

3. Discussion

We report a patient with agraphia resulting from pure impairment of visuo-constructive function after an acute infarction in the right angular gyrus. The patient, whose left hemisphere was language dominant, showed no other language disorders except for writing problems characterized by visual errors and reduced neatness in handwriting. Hence, we concluded that the agraphia symptoms were caused by visuo-spatial/constructive dysfunction following right parietal lobe injury, rather than crossed agraphia.

Agraphia occurs in many forms because writing involves many cognitive processes, including language processing, spelling, visual perception, visuo-spatial orientation for graphic symbols, motor planning, and motor control of handwriting. The patient's agraphia could be classified as spatial dysgraphia, which refers to the spatial organization of writing [1,2]. A previous study showed that writing impairments are typically more noticeable in retro-Rolandic damage, although right frontal damage may reveal motor-associated deficits (such as iterations of features and letters) [3]. Detailed

* Corresponding author. Tel.: +82 31 219 5175; fax: +82 31 219 5178.

E-mail address: symoon.bv@gmail.com (S.Y. Moon).

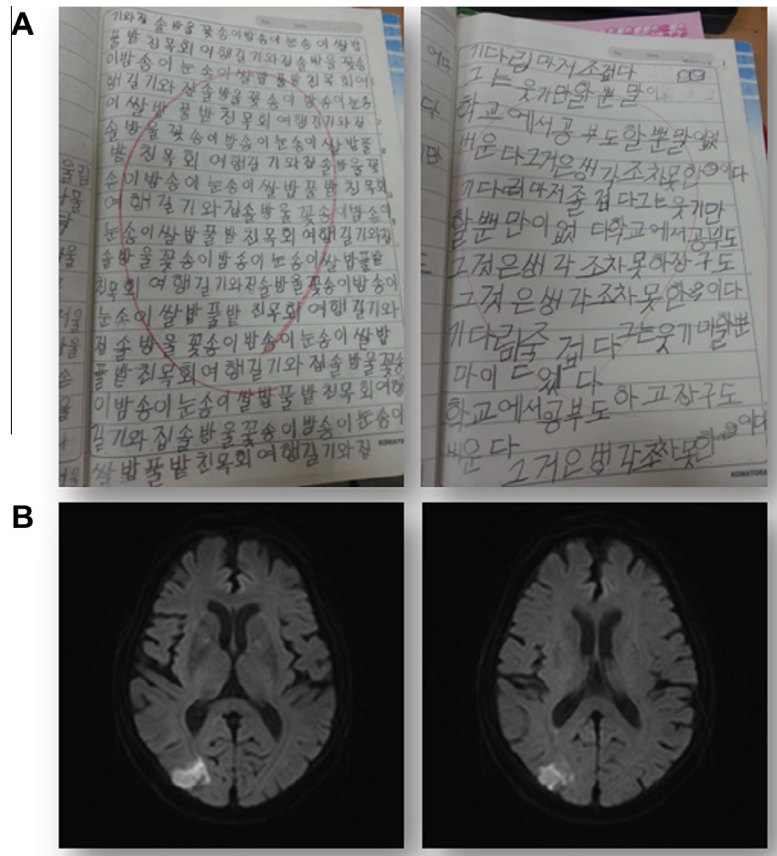


Fig. 1. (A) Hangul writing before (left) and after (right) infarct. The patient used the phoneme-to-grapheme conversion and wrote the targets as they sound. Visual errors as well as untidiness characterized her post-infarction writing style. (B) Axial diffusion-weighted brain MRI showed an acute infarct in the right angular gyrus.

neuropsychological tests showed our patient had impairment in visuo-constructive function, however the only effect on her daily activities were writing difficulties, and the lesion was restricted to the right angular gyrus.

Unlike alphabetic writing systems, Hangul includes the arrangement of strokes and graphemes within a square syllabic form according to dimensional and spatial rules (for example, 권). The component consonant(s) and vowel(s) must be arranged from top-to-bottom and/or left-to-right within the form of a square, in visuo-spatial construction of a syllable. Therefore, it involves language-specific linguistic and visuo-spatial/constructive processes. The patient showed features of surface agraphia with regard to the linguistic aspects of writing performance. Although Hangul is a phonogram that is usually read according to the phoneme-to-grapheme conversion rule, there are some exceptions (for example, the written form “값어치” is read as “가벼치” [gab[^]chi]). This type of error normally indicates that the patient is not able to access the lexical or lexical-semantic route in writing. Our patient’s relatively short period of learning Hangul as an adult may have resulted in this type of error. Irregular words are considered more difficult and are learned later in the writing process. Similar errors also occur occasionally in healthy adults who have received less education. The fact that the patient applied the phoneme-to-grapheme conversion rule in writing supports our interpretation that the linguistic aspect of her writing was relatively preserved. A previous study on Korean stroke patients showed that while the left hemisphere lesion group produced primarily linguistic errors, visuo-spatial/constructive errors predominated in the group with right hemisphere lesions [4]. Another positron emission tomography study demonstrated that impaired

performance in Hangul writing among Korean Alzheimer’s disease patients was closely related to a functional decline in both the right and left hemispheres [5]. Previous studies showed that Hangul is more dependent on the right hemisphere than alphabetic writing systems. Our patient started learning to write Hangul in her later years, and possibly relied on her fully developed visuo-spatial/visuo-constructive skills in learning, in turn manifesting agraphia after the right parietal lesion. This patient’s case is suggestive that the right angular gyrus functions as a core area for the unique visuo-constructive characteristics of Korean writing.

Conflicts of Interest/Disclosures

The authors declare that they have no financial or other conflicts of interest in relation to this research and its publication.

Acknowledgements

This study was supported by a grant of the Korea Healthcare technology R&D Project, Ministry of Health and Welfare, Republic of Korea (HI10C2020).

Appendix A. Supplementary material

Supplementary data associated with this article can be found, in the online version, at <http://dx.doi.org/10.1016/j.jocn.2014.09.023>.

References

- [1] Rode G, Klos T, Courtois-Jacquin S, et al. Neglect and prism adaptation: a new therapeutic tool for spatial cognition disorders. *Restor Neurol Neurosci* 2006;24:347–56.
- [2] Rode G, Pisella L, Marsal L, et al. Prism adaptation improves spatial dysgraphia following right brain damage. *Neuropsychologia* 2006;44:2487–93.
- [3] Ardila A, Rosselli M. Spatial agraphia. *Brain Cogn* 1993;22:137–47.
- [4] Yoon JH, Suh MK, Kim H. Language-specific dysgraphia in Korean stroke patients. *Cogn Behav Neurol* 2010;23:247–55.
- [5] Yoon JH, Kim H, Seo SW, et al. Dysgraphia in Korean patients with Alzheimer's disease as a manifestation of bilateral hemispheric dysfunction. *J Neurosci* 2012;320:72–8.

<http://dx.doi.org/10.1016/j.jocn.2014.09.023>

A novel mechanism of toxic injury to the Papez circuit from chemotherapy



Benjamin Yin Ming Kwan^{a,c}, Timo Krings^a, Mark Bernstein^b, Daniel M. Mandell^{a,*}

^aDivision of Neuroradiology, Toronto Western Hospital and the University of Toronto, 399 Bathurst Street 3 MCL-426, Toronto, Ontario M5T2S8, Canada

^bDivision of Neurosurgery, Toronto Western Hospital and the University of Toronto, Toronto, Ontario, Canada

^cDepartment of Medical Imaging, Western University, London, Ontario, Canada

ARTICLE INFO

Article history:

Received 2 October 2014

Accepted 17 October 2014

Keywords:

Ommaya reservoir

Papez circuit

Toxic leukoencephalopathy

ABSTRACT

Toxic effects of chemotherapy delivered via Ommaya reservoir include pericatheter necrosis and toxic leukoencephalopathy. Imaging evidence of toxicity is often asymptomatic, but can be clinically consequential. A young patient, treated for cerebrospinal fluid relapse of acute lymphoblastic leukemia with methotrexate and cytarabine via Ommaya reservoir, presented with acute deterioration of short-term memory. MRI demonstrated extra-ventricular Ommaya catheter position and typical methotrexate-induced changes in the deep white matter, but also signal alteration in the fornical columns and mammillary bodies, components of the Papez circuit. This case presents a novel mechanism of chemotherapy-induced neurotoxicity associated with extra-ventricular Ommaya catheter position. Specifically, the clinical and imaging findings suggest that extra-ventricular Ommaya catheter position may lead to a direct methotrexate-induced toxicity to the Papez circuit. This provides further clinical evidence of the function of the circuit. The possibility that this patient received a supratherapeutic dose of methotrexate may explain why this presentation with profound memory impairment is not more common. However, this case also provides a potential explanation for patients who receive standard dose chemotherapy via extra-ventricular Ommaya catheter and develop milder memory loss.

© 2014 Elsevier Ltd. All rights reserved.

1. Introduction

The Ommaya reservoir is an implanted subcutaneous port connected to an indwelling ventricular catheter [1–3]. Ommaya reservoirs are used to deliver chemotherapeutic drugs for cancer treatment, and antibiotics for meningitis, and are used for ventricular drainage [1–3]. Neurotoxicity due to Ommaya reservoir-delivered methotrexate is well known [1,2–4]. Imaging evidence of toxicity is often transient and clinically asymptomatic, but patients may develop an acute stroke-like syndrome, transverse myelopathy, or symptomatic aseptic meningitis [4]. Histopathologically, the typical finding is demyelination, and there may be necrosis [1,2]. Methotrexate inhibits the enzyme dihydrofolate reductase and the subsequent formation of tetrahydrofolate, which is involved in the synthesis of myelin proteins and lipids [4]. Transependymal diffusion of methotrexate or catheter malposition may lead to brain parenchymal toxicity [1,2]. Pericatheter predominance of toxicity may occur, and results from retrograde flow of cerebrospinal fluid around the catheter as it is the path of least resistance out of the ventricular system [2].

2. Case report

A young patient presented with acute deterioration of short-term memory, with no recollection of date, time, or events in the preceding 24–48 hours. Past medical history was significant for acute lymphoblastic leukemia diagnosed at age 3, treated with systemic and intrathecal chemotherapy and craniospinal radiation. There was central nervous system relapse at age 16, which was treated similarly, and central nervous system relapse again approximately 3 months before presentation with memory loss. Following the most recent relapse, an Ommaya reservoir was placed for administration of intrathecal chemotherapy. This was performed using a frame-based stereotactic navigation system (BrainlabAG, Munich, Germany). The ventricles were accessed on the first pass, and cerebrospinal fluid backflow confirmed intra-ventricular catheter position. The patient was treated with intra-Ommaya chemotherapy (methotrexate 12 mg and cytarabine 40 mg) twice each week for 4 weeks, after which the cerebrospinal fluid was negative for blasts. Three weeks later, the cerebrospinal fluid revealed blasts, and twice-weekly chemotherapy was restarted. This was stopped two weeks later due to the development of typhlitis with gastrointestinal bleeding, and acute memory loss.

At the time of presentation with memory impairment, MRI (Fig. 1) demonstrated the Ommaya reservoir in the right frontal

* Corresponding author. Tel.: +1 416 603 5800x4933; fax: +1 416 603 4257.

E-mail address: danny.mandell@uhn.ca (D.M. Mandell).