

CASE REPORT

Atrio-oesophageal fistula after transcatheter radiofrequency ablation

Caroline E Moss,¹ Sandra Fernandez-Caballero,² David Walker¹¹Department of ICM/ Anaesthetics, UCLH, London, UK²Department of ICM, UCLH, London, UK**Correspondence to**

Dr Caroline E Moss, drcarolinemoss@gmail.com

Accepted 15 December 2014

SUMMARY

A 68-year-old woman presented 3 weeks following unsuccessful transcatheter radiofrequency ablation (TcRFA) for treatment of her chronic atrial fibrillation. Neurological signs manifested on day 2 of admission with generalised tonic-clonic seizures and reduced Glasgow Coma Score. She was treated for presumed central nervous system (CNS) infection, intubated and transferred to the intensive care unit. CT of the head showed bilateral oedema secondary to acute embolic stroke. Blood cultures grew *Streptococcus viridans*, and lumbar puncture findings were consistent with CNS infection. Echocardiography showed only a septostomy puncture from the atrial fibrillation ablation procedure. Thoracic CT demonstrated air in the left atrium, consistent with the diagnosis of atrio-oesophageal fistula, a rarely reported iatrogenic complication of TcRFA. MRI of the head showed significant neurological injury with innumerable embolic infarcts. After discussion with her family regarding the significant neurological insult, and with no signs of any clinical improvement, the patient died on day 8 of admission.

BACKGROUND

Transcatheter radiofrequency ablation (TcRFA) for the treatment of atrial fibrillation (AF) is considered a safe and now commonly performed procedure. Rare complications do occur, and as the procedure becomes more commonplace, so these complications will increasingly present. Given the potentially lethal outcome, as in this case, we felt it important to highlight the diagnosis as a potential differential to be considered early in all patients presenting with signs of infection following this procedure. By doing so, hopefully early intervention will significantly improve the prognosis for this diagnosis, which is currently extremely poor.

CASE PRESENTATION

A 68-year-old anticoagulated female patient underwent unsuccessful TcRFA therapy for treatment of chronic AF. She was otherwise fit and well. Immediately postprocedure, the patient experienced transient chest pain, which was not associated with haemodynamic instability or ECG abnormality. It resolved spontaneously without treatment prior to her discharge home the same day.

Three weeks after this procedure, the patient presented to our hospital non-specifically unwell and feverish (39°C), but with no identifiable source of infection. Warfarin therapy had been held and an international normalised ratio of 9 was recorded on admission. On the second day of admission, the

patient suffered two generalised tonic-clonic seizures, was intubated and transferred to the intensive care unit. Ceftriaxone and acyclovir were started empirically, before proceeding with further investigation.

INVESTIGATIONS

CT of the head was performed (figure 1), showing findings consistent with acute, likely embolic, stroke.

Admission blood cultures grew α -haemolytic streptococci (*Streptococcus viridans*). A later lumbar puncture demonstrated clear colourless cerebrospinal fluid, with no organisms identified, but an elevated white cell count of 224/mm³ (4% polymorphs, 96% mononuclear cells), consistent with partially treated bacterial meningitis or a viral meningitis.

Both transthoracic and transoesophageal echocardiography confirmed no valvular vegetations or intracardiac air, but evidence of a haemodynamically insignificant septostomy puncture associated with the AF ablation procedure.

A CT chest was performed and revealed gas in the left atrium (LA; figure 2).

MRI of the brain later confirmed innumerable foci consistent with embolic infarcts, although some not appearing to conform to conventional vascular territories. In addition, petechial cortical

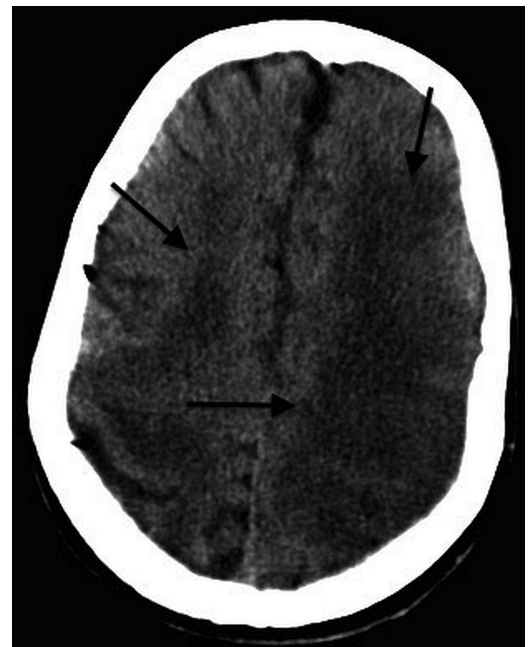


Figure 1 CT of the head showing severe bilateral oedema secondary to acute stroke likely of embolic origin.



CrossMark

To cite: Moss CE, Fernandez-Caballero S, Walker D. *BMJ Case Rep* Published online: [please include Day Month Year] doi:10.1136/bcr-2014-204998

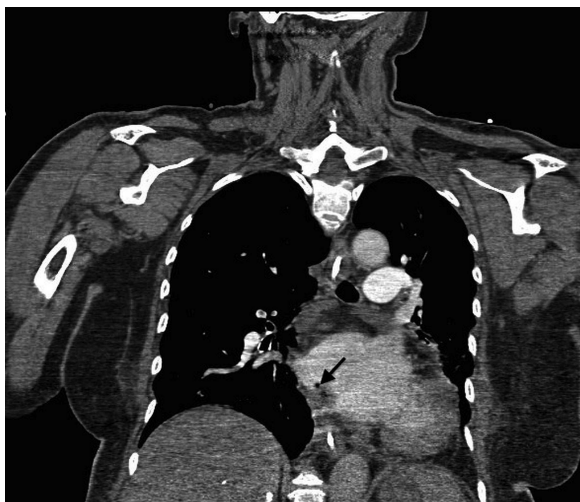


Figure 2 Coronal thoracic CT images demonstrating air in the left atrium (see arrow).

haemorrhagic transformation was evident throughout much of the left frontal and parietal lobes with several other smaller lesions also exhibiting minor haemorrhage (figure 3).

DIFFERENTIAL DIAGNOSIS

The patient's presentation with systemic signs of sepsis and accompanying neurological involvement, investigation findings consistent with an infective process and the history of a recent invasive cardiac procedure led us to a differential diagnosis of infective endocarditis, paradoxical embolus via the iatrogenic septostomy, thromboembolic stroke or atrio-oesophageal fistula (AOF). Thromboembolic stroke and paradoxical embolus are less likely to account for both the preceding signs of systemic infection, and the diffuse neurological insult (which does not conform to a specific vascular territory on neuroimaging). Both infective endocarditis and AOF are rare diagnoses, which could account for the patient's presentation. Significantly, however,

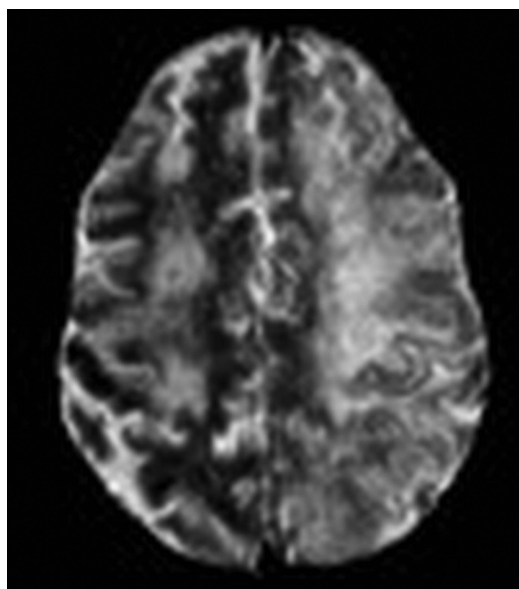


Figure 3 MRI fluid-attenuated inversion recovery sequence showing changes consistent with acute stroke (see arrows).

the investigation of choice to diagnose infective endocarditis would be a transoesophageal echocardiogram, which is contraindicated in cases of AOF because of the risk of catastrophic air embolus.

TREATMENT

Treatment was supportive with no definitive therapy indicated.

OUTCOME AND FOLLOW-UP

Over the 24 h following the MRI result, there was no change in conscious level and the patient became cardiovascularly unstable. On day 7, with no apparent neurological improvement and after full discussion with all family members, further escalation of treatment was withheld. The patient died on day 8 of her admission.

DISCUSSION

Radiofrequency ablation for the management of AF is an increasingly commonly performed procedure. Arrhythmogenic foci have been found to predominantly originate in the posterior LA, and in longitudinal fibres of the muscular sleeve of atrial tissue that can extend for several centimetres from the LA into the ostia of the four pulmonary veins. The aim of TcRFA is to map and subsequently ablate these foci with radiofrequency energy to create electrically inactive scar tissue.

Prior to AF ablation, a transoesophageal echocardiography (TOE) is commonly performed to ensure the LA is free of thrombus. Vascular access to the femoral vein is obtained via three sheaths. Two of the sheaths are used to access the LA using a trans-septal (right atrium (RA) to LA) puncture technique, and the third can be used for coronary sinus cannulation. To perform the trans-septal punctures, a long sheath and dilator are inserted over a guidewire into the superior vena cava. A trans-septal needle is then inserted into the sheath with the needle tip kept a few millimetres inside the dilator, and this assembled unit is guided into the fossa ovalis in the RA using continuous pressure monitoring and direct imaging. The needle is then advanced to puncture the septum and access the LA, and the sheath is advanced over the needle. The needle can then be removed. Through one sheath a mapping catheter is placed to allow pulmonary vein identification, and recording of ECGs from within the pulmonary veins and throughout the LA to identify the abnormal conducting pathways. Through the other sheath the ablation catheter is placed, which has a 4 mm tip irrigated continuously with 17 mL/min saline to cool the tip during the ablation process, and delivers high-frequency energy to the target sites. Power levels of 20–50 W can be used depending on the area being targeted. Once the sheaths are in place, the patient must be heparinised to an activated clotting time of 300 s, and the system must be meticulously kept free of air.

Up to 60 000 ablations are performed in Europe each year,¹ and common complications are recognised (box 1).

In this case systemic features of sepsis at presentation corroborated by positive biochemical and microbiological markers supported an early diagnosis of central nervous system (CNS) infection. Positive *S. viridans* blood cultures and lumbar puncture findings consistent with CNS infection were important early findings. This facultative anaerobe is a coagulase negative organism most commonly responsible for bacteraemia after any procedure in the oesophagus, but is responsible for less than 25% of cases of infective endocarditis. They are abscess forming in a variety of tissues, including the myocardium, valvular structures and brain. Transoesophageal echocardiography was useful in excluding a primary cardiac focus of infection or residual

Box 1 Common complications of TcRFA

Complications following transcatheter radiofrequency ablation

- ▶ Failure of the procedure;
- ▶ Pain/bleeding at catheter insertion point;
- ▶ Pulmonary vein stenosis;
- ▶ Cardiac tamponade;
- ▶ Stroke.

thrombus, but with hindsight this intervention may have been contraindicated if AOF had been considered. The thoracic CT imaging pointed towards oesophageal pathology and a potential diagnosis of AOF, which was supported by the finding of *S. viridans* sepsis. AOF complicating surgical ablations has a reported incidence as high as 1–1.5%.² The now more common TcRFA technique first reported a case of AOF in 2004.³ AOF is currently reported to occur in between 0.01% and 0.2%⁴ cases, with 49 reported cases in the medical literature since 2004.

In practice, a diagnosis of AOF may be difficult to make, as the clinical presentation may be non-specific or may be diagnostically confusing. The published time from ablation to symptoms onset has varied from 2 to 41 days. One of the most consistent signs is a fever (in up to 75% cases), and can occur from as early as 3 days postprocedure. As in this case, neurological manifestations usually dominate the presentation, and result from cardiac embolism of thrombi, transgressed oesophageal contents or air.⁵ Neurological manifestations, being identified in 69% patients with clinical signs, include embolic strokes, seizures, transient ischaemic attacks, coma or psychiatric abnormalities. Neurological deficits tend to be a late finding associated with significant mortality or residual morbidity. Other less frequent findings included leucocytosis, chest pain and bacteraemia (4 of 49 patients). Endocarditis must be considered in the diagnosis differential (although the incidence postablation is very low). Transoesophageal echocardiography, along with all invasive oesophageal procedures (gastroscopy, oesophageal stenting), is contraindicated because of the risk of catastrophic air embolus. Although performed in this case prior to the diagnosis of AOF being considered, fortunately no clinical deterioration occurred at the time of the TOE, and the catastrophic neurological insult had already been sustained, so it is unlikely that having performed this procedure altered the patient's outcome.

The aetiology of AOF has been shown to arise from the high susceptibility of the intestinal mucosa to thermal injury in comparison to the relative resistance of the cardiac muscle, with the tissue damage originating in the oesophagus and progressing to the LA.⁶ Oesophageal injuries are believed to be precursors of fistula formation, and reported to occur in 47% of all patients undergoing TcRFA. The oesophagus is in close anatomical proximity to the posterior wall of the LA, separated only by a thin 1 mm layer of fat. Strategies to avoid oesophageal injury include: limiting the power and temperature settings used when ablating at the posterior LA wall (limitation of oesophageal temperature to 40°C is associated with the lowest incidence of oesophageal lesion formation, keeping ablative power to less than 25 W and minimising continuous diathermy time to less than 60 s), visualisation of the oesophagus by barium swallow, tagging the course of the oesophagus by electroanatomical

mapping and oesophageal irrigation/cooling. The most reliable tool for diagnosis is thoracic CT with contrast media confirming pneumomediastinum or intra-atrial air, although this remains non-diagnostic in a minority of cases.

CT and MRI detected the presence of multiple CNS emboli. Peri-procedural anticoagulation therefore is an important consideration during catheter ablation therapy, because of the potential thromboembolic risk. This may be due to early arrhythmia recurrences and the thromboembolic potential of ablation-induced left atrial lesions. This risk is reported to be 0.4% for clinically apparent stroke, and up to 14% silent cerebral embolism rate detected on MRI the day after the procedure.⁷ Other aetiological factors may contribute to embolic risk. Dislodged pre-existing thrombus in the left atrial appendage or radiofrequency-induced lesions providing a nidus for new thrombus formation are important factors. Both intracardiac sheaths and catheters themselves provide a focus for thrombus formation, and there exists a small risk of paradoxical emboli via the procedural trans-septal puncture.⁸

In our case, thoracic CT imaging confirmed air in the LA, although no pneumomediastinum (figure 2), leading to the diagnosis of AOF. The mortality rate for this condition is high, reported as 67% for the 49 cases seen in the literature to date,⁹ though in some cases series it is as high as 100%. Early diagnosis, prompt surgical assessment and prolonged antibiotics all positively influence survival, with no patient surviving without definitive surgical closure of the fistula to date.

Learning points

- ▶ Atrial fibrillation ablation is a relatively commonly performed procedure.
- ▶ Resulting atrio-oesophageal fistula (AOF) is uncommon but should be suspected where the procedure is followed by fever of unknown origin and signs of sepsis, which may have a latency period of days to months.
- ▶ It is an important differential to consider along with infective endocarditis.
- ▶ Prompt diagnosis may be aided with early CT and avoidance of TOE until AOF has been excluded.

Contributors CEM authored the first draft of the report and performed the initial literature review, as well as being involved in subsequent revisions. SF-C was involved in draft revision. DW obtained signed consent from the patient's next of kin, as well as providing supervision and guidance with revisions of the report. All the listed authors were involved in the clinical management of the patient.

Competing interests None.

Patient consent Obtained.

Provenance and peer review Not commissioned; externally peer reviewed.

REFERENCES

- 1 D'Silva M, Wright M. Advances in imaging for atrial fibrillation ablation. *Radiol Res Pract* 2011;2011:714864.
- 2 Mohr FW, Nikolaus D, Falk V, et al. Curative treatment of atrial fibrillation: acute and midterm results of intraoperative radiofrequency ablation of atrial fibrillation in 150 patients. *J Thorac Cardiovasc Surg* 2002;123:919–27.
- 3 Pappone C, Oral H, Santinelli V, et al. Atrio-oesophageal fistula as a complication of percutaneous transcatheter ablation of atrial fibrillation. *Circulation* 2004;109:2724–6.

Reminder of important clinical lesson

- 4 Dagnes N, Hindricks G, Kottkamp H, *et al.* Complications of atrial fibrillation ablation in a high-volume center in 1000 procedures: still a cause for concern? *J Cardiovasc Electrophysiol* 2009;20:1014–19.
- 5 Dagnes N, Kottkamp H, Piorkowski C, *et al.* Rapid detection and successful treatment of oesophageal perforation after radiofrequency ablation of atrial fibrillation: lessons from 5 cases. *J Cardiovasc Electrophysiol* 2006;17:1213–15.
- 6 Gilcrease GW, Stein JB. A delayed case of fatal atrio-oesophageal fistula following radiofrequency ablation for atrial fibrillation. *J Cardiovasc Electrophysiol* 2010;21:708–11.
- 7 Gaita F, Caponi D, Pianelli M, *et al.* Radiofrequency catheter ablation of atrial fibrillation: a cause of silent thromboembolism? Magnetic resonance imaging assessment of cerebral thromboembolism in patients undergoing ablation of atrial fibrillation. *Circulation* 2010;122:1667–73.
- 8 Sommer P, Hindricks G. Iatrogenic atrial septal defect after catheter ablation of atrial fibrillation: do we have to worry? *Europace* 2010;12:301–2.
- 9 Siegel M, Parenti D, Simon G. Atrial-esophageal fistula after atrial radiofrequency catheter ablation. *Clin Infect Dis* 2010;51:73–6.

Copyright 2015 BMJ Publishing Group. All rights reserved. For permission to reuse any of this content visit <http://group.bmj.com/group/rights-licensing/permissions>.
BMJ Case Report Fellows may re-use this article for personal use and teaching without any further permission.

Become a Fellow of BMJ Case Reports today and you can:

- ▶ Submit as many cases as you like
- ▶ Enjoy fast sympathetic peer review and rapid publication of accepted articles
- ▶ Access all the published articles
- ▶ Re-use any of the published material for personal use and teaching without further permission

For information on Institutional Fellowships contact consortiasales@bmjgroup.com

Visit casereports.bmj.com for more articles like this and to become a Fellow