

# “Paradoxical” EEG response to propofol may differentiate post-cardiac arrest non-convulsive status epilepticus from diffuse irreversible cerebral anoxia

Michalis Koutroumanidis<sup>1,2</sup>, Dimitris Sakellariou<sup>1</sup>,  
Vasiliki Tsirka<sup>1,2</sup>

<sup>1</sup> Department of Clinical Neurophysiology, Epilepsy,  
Guys, St Thomas’ NHS Foundation Trust

<sup>2</sup> Department of Academic Neurosciences, Kings College London, UK

Received June 25, 2014; Accepted September 23, 2014

**ABSTRACT** – Current EEG criteria for the diagnosis of non-convulsive status epilepticus in critically ill patients with repetitive generalised or focal epileptiform discharges primarily rely on a widely accepted low cut-off frequency limit of 2.5-3 Hz for non-evolving patterns, or on discharge evolution of frequency, location or morphology. The secondary criterion is a significant clinical or EEG improvement following acute administration of a rapidly acting antiepileptic drug, such as lorazepam.

We describe a comatose patient after out-of-hospital cardiac arrest, in whom very slow (1-Hz), non-evolving generalised periodic epileptiform discharges against an almost completely depressed background would suggest substantial anoxic damage and poor neurological outcome. Yet, reloading with propofol for diagnostic purposes completely dispersed generalised periodic epileptiform discharges and revealed previously absent biological activity, raising the possibility of non-convulsive status epilepticus that was subsequently confirmed. Brain MRI showed no significant anoxic brain damage and EEG improved, but the patient died from severe cardiopulmonary complications. These observations suggest that in rare cases, slow, non-evolving generalised periodic epileptiform discharges may reflect non-convulsive status epilepticus rather than diffuse irreversible cerebral anoxia, while reloading with propofol can be used as an additional secondary diagnostic criterion.

**Key words:** slow non-evolving GPED, diagnostic criteria for NCSE, continuous EEG monitoring, hypnospectrogram



**Correspondence:**

Michalis Koutroumanidis  
Department of Clinical Neurophysiology  
and Epilepsy,  
Lambeth Wing, 3rd Floor, St Thomas’  
Hospital,  
London SE1 7SS, UK  
<michael.koutroumanidis@gstt.nhs.uk>  
<michalis.koutroumanidis@kcl.ac.uk>

The main concern in comatose post-cardiac arrest patients is the misinterpretation of a potential non-convulsive status epilepticus (NCSE) for anoxia, leading to under-treatment with anti-seizure agents or even their withdrawal when they are needed; ongoing NCSE is associated with poor outcome and increased mortality (Nielsen *et al.*, 2011; Rittenberger *et al.*, 2012), but worse, false positive prediction of a poor outcome may influence decision about continuation of treatment or withdrawal of life support. The risk of misdiagnosis is particularly increased in comatose patients with generalised periodic *non-evolving* epileptiform discharges (GPEDs), where a low cut-off discharge frequency limit is currently widely accepted as a foremost criterion (table 1). Indeed, non-evolving GPEDs at low ( $\leq 2.5$ -Hz) frequencies against an attenuated or suppressed background after hypoxic-ischaemic brain insults are almost invariably associated with severe and irreversible cortical damage (Zandbergen *et al.*, 1998; Koenig *et al.*, 2006). We report a patient with out-of-hospital cardiac arrest, whose first acute video-EEG (vEEG) showed non-evolving GPEDs at  $\leq 1$  Hz, that were associated with axial myoclonus when propofol was temporarily stopped, a pattern typically associated with severe cerebral anoxia and poor neurological outcome. However, a “paradoxical” EEG response to propofol reinstatement suggested the possibility of NCSE, which was subsequently confirmed and eventually shown to be the principal underlying cause for the initial “malignant” EEG pattern.

## Case study

A 60-year-old bus driver collapsed at work and received basic life support by colleagues. Paramedics identified inferior ST elevation myocardial infarction on ECG

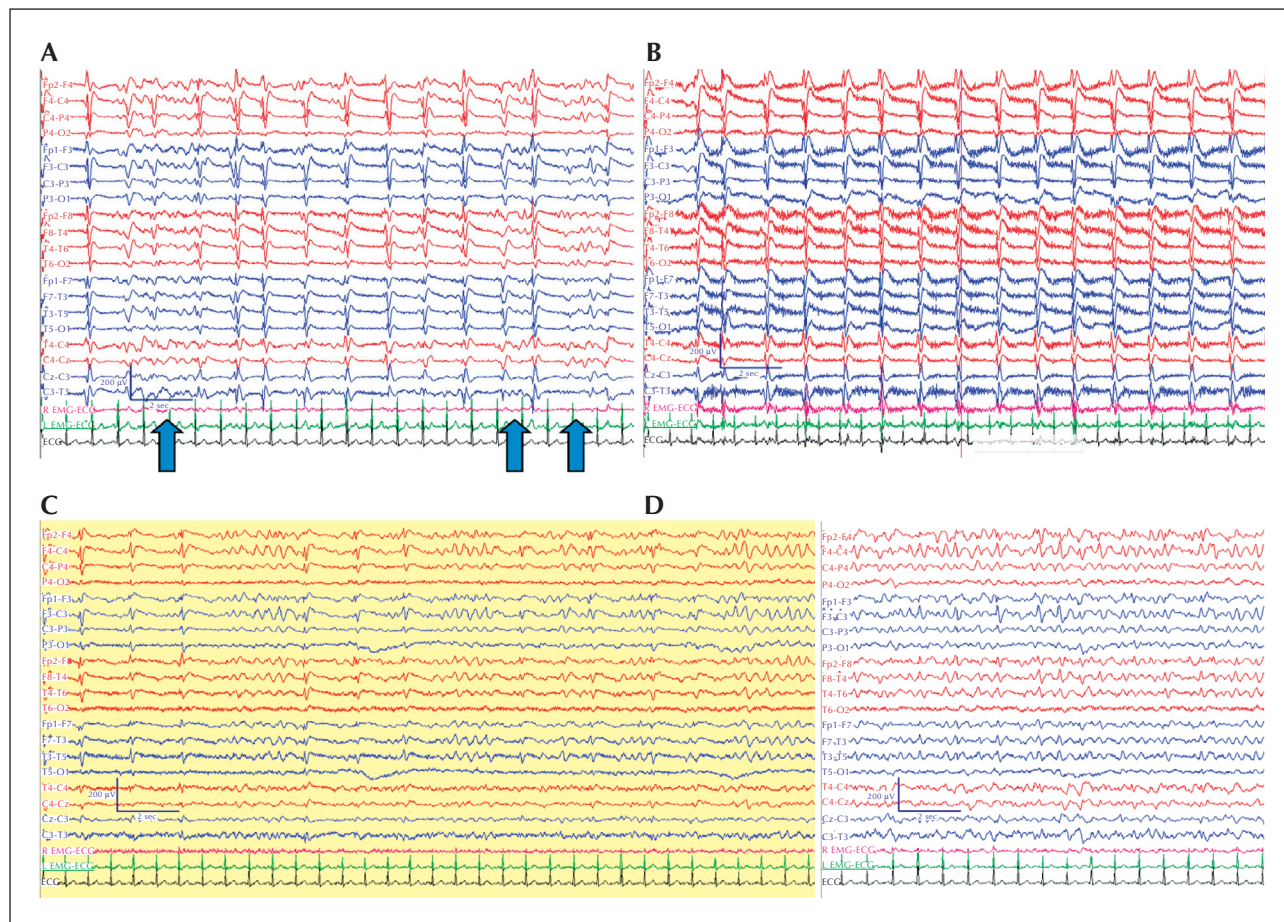
and loss of cardiac output, and treated him with five cycles of cardiopulmonary resuscitation (CRP), three boluses of 1 mg adrenaline and 300 mg amiodarone in 20-30 cc 5% dextrose solution. Return of spontaneous circulation was recorded after about 40 minutes. On arrival to the emergency department, Glasgow Coma Scale was 3/15, but he was breathing spontaneously and pupils were reactive to light. He was intubated and treated with aspirin at 300 mg and Ticagrelor at 180 mg. In the coronary care unit, an angiogram showed right coronary artery (RCA) stenosis and balloon angioplasty was attempted, during which he had pulseless electrical activity; he had further CPR and responded to adrenaline and isoprenaline, returning to sinus rhythm. Drug-eluting stent was eventually deployed for his RCA stenosis, while no other coronary vessel was found compromised. He was transferred to the intensive care unit (ICU), underwent therapeutic cooling for 24 hours, and remained sedated on propofol and remifentanyl. Upon temporary reduction of sedation, he presented axial myoclonus and generalised convulsions and was treated with phenytoin (PHT) at 300 mg/day.

The first acute vEEG (XLTEK natus) in the ICU was performed after the period of therapeutic hypothermia, about 36 hours post-insult and while the patient was on propofol, 2% at 7 ml/h, and fentanyl at 2 ml/h. A baseline recording showed GPEDs at  $\leq 1$  Hz against an almost completely suppressed background with only occasional brief diffuse bursts of delta activity at 3-4 Hz, and up to 100  $\mu$ V over the anterior areas (figure 1A). In accordance with the vEEG recording protocol at our ICU, propofol was gradually stopped and auditory and noxious stimulations in the upper and the lower limbs were performed bilaterally, and also suction. Withdrawal of propofol was associated with the emergence of repetitive axial myoclonus associated with the GPEDs and complete suppression of the

**Table 1.** Current proposed EEG criteria for the diagnosis of NCSE.

<b>An EEG pattern lasting for at least 30 min and satisfying any one of the following three primary criteria:</b>
<p>Primary criteria:</p> <ol style="list-style-type: none"> <li>1. Repetitive Generalised or focal epileptiform discharges (ED) at <math>\geq 3.0</math> Hz (<math>\geq 2.5</math> Hz*).</li> <li>2. Repetitive Generalised or focal ED at <math>&lt; 3.0</math> Hz (or <math>&lt; 2.5</math> Hz*) and the secondary criterion.</li> <li>3. Sequential rhythmic, periodic or quasi-periodic waves at <math>\geq 1</math> Hz with unequivocal evolution in a) frequency, gradually increasing or decreasing by at least 1 Hz (i.e. from 2 to 3 Hz or vice-versa), b) location, gradually spreading into or out of a region involving at least two electrodes, or c) morphology. Change of amplitude or sharpness only is not sufficient to satisfy evolution of morphology.</li> </ol>
<p>Secondary criterion:</p> <p>Significant improvement in clinical state or appearance of previously absent normal EEG patterns, temporarily coupled to acute administration of a rapidly acting antiepileptic drug. Resolution of the “epileptiform” discharges leaving diffuse slowing, without normal EEG patterns or clinical improvement, does not satisfy this criterion.</p>

(Adapted from Jirsch and Hirsch, 2008; \*modifications on frequency criteria proposed by Drislane and Kaplan [2009]; See also Review Article by Cheng (2014) published in this issue of *Epileptic Disorders*)

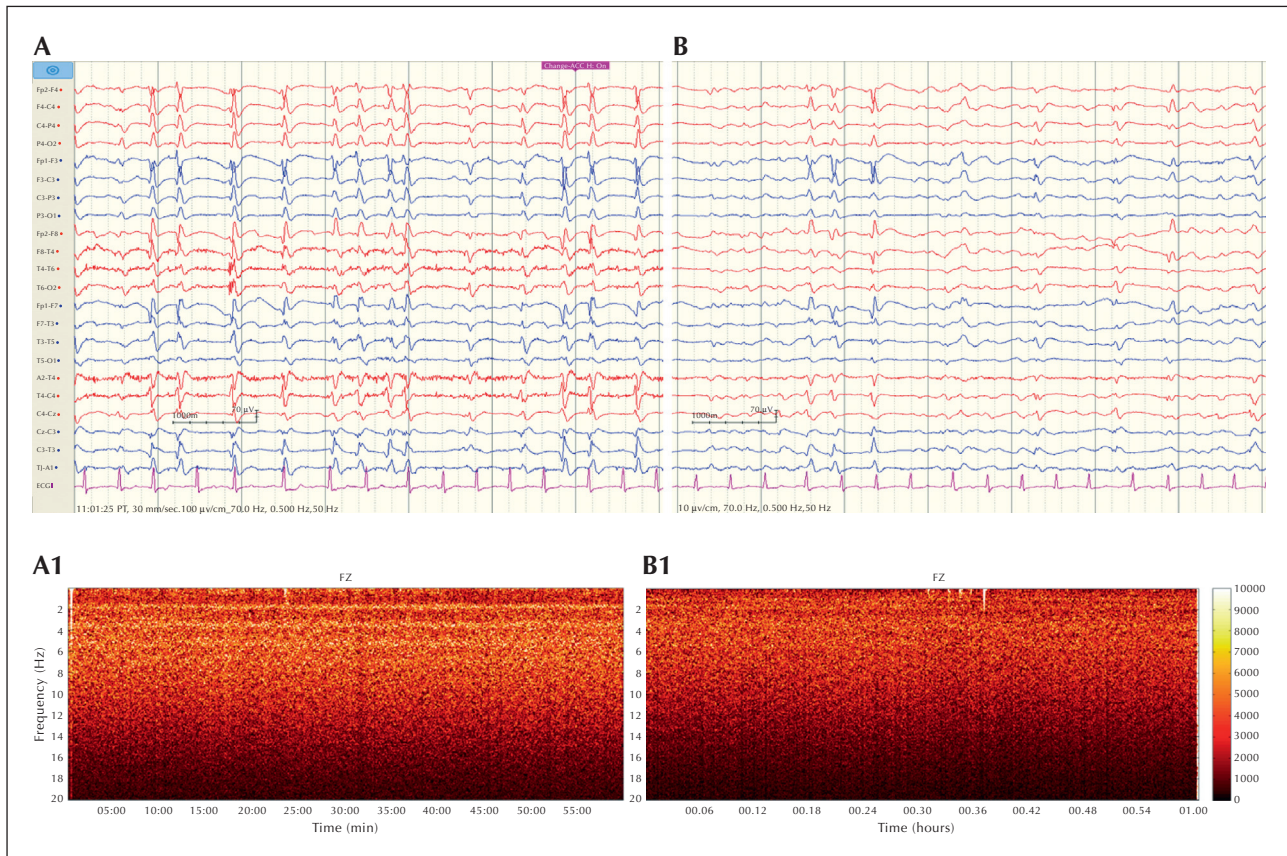


**Figure 1.** First acute vEEG on Day 2 post-insult, while the patient was on PHT. (A) Baseline recording on propofol showed unremitting GPEDs at around 1 Hz with infrequent and brief diffuse bursts of biological delta activity in between some discharges (arrows). Both GPEDs and delta activity were maximal in the frontal region. The amount of biological delta activity before propofol was withdrawn did not exceed 20% of the recording time. (B) Propofol discontinuation resulted in the electroclinical picture of anoxic status myoclonus; the few, brief and far between bursts of delta completely disappeared, while GPEDs became associated with axial myoclonus (note the time-locked muscle artefacts in the two EMG channels) with concurrent opening of the eyes. (C) Gradual disappearance of GPEDs and emergence of biological activity 50 seconds after propofol infusion was reinstated. Note the occurrence of faster activities over the central and frontal areas (mainly in the bottom four channels). (D) Two minutes later, biological activities were continuous with only "hints" of the previous GPEDs.

background (*figure 1B*). Infusion of propofol was reinstated 13 minutes later. As expected, axial myoclonus soon subsided, but 50 seconds into infusion, GPEDs progressively became less frequent, while the bilateral frontal delta activity re-emerged in far greater amounts relative to the time prior to propofol withdrawal, along with low-voltage faster rhythms over the central areas (*figure 1C*). Biological activities soon became continuous and GPEDs disappeared (*figure 1D*). GPEDs reappeared 7 minutes later, associated with brief periods of diffuse attenuation. EEG recording was stopped at that point. Apart from coughing upon suction, no other clinical reaction or any EEG changes in response to external stimuli were observed at any point. Because of the unexpected continuous occurrence of biological rhythms upon restarting propofol,

and despite the initial clinical/EEG picture that was in keeping with anoxic status myoclonus (*figure 1B*), an hypothesis of NCSE masking surviving biological activities was put forward and more intense antiseizure treatment was recommended by adding IV sodium valproate (VPA).

A second vEEG was recorded on Day 4 post-insult after 500 mg bd VPA (with levels at 33 mg/l) had been added to PHT (levels at 15 mg/l). The frequency of GPEDs had increased to 1.5-2 Hz with clear biological rhythms in between the paroxysms. Temporary discontinuation of propofol resulted in slightly more frequent (up to 2.5-3 Hz) and more robust GPEDs, associated with moderate axial jerking. Findings were interpreted as confirmatory of the initial hypothesis of NCSE.

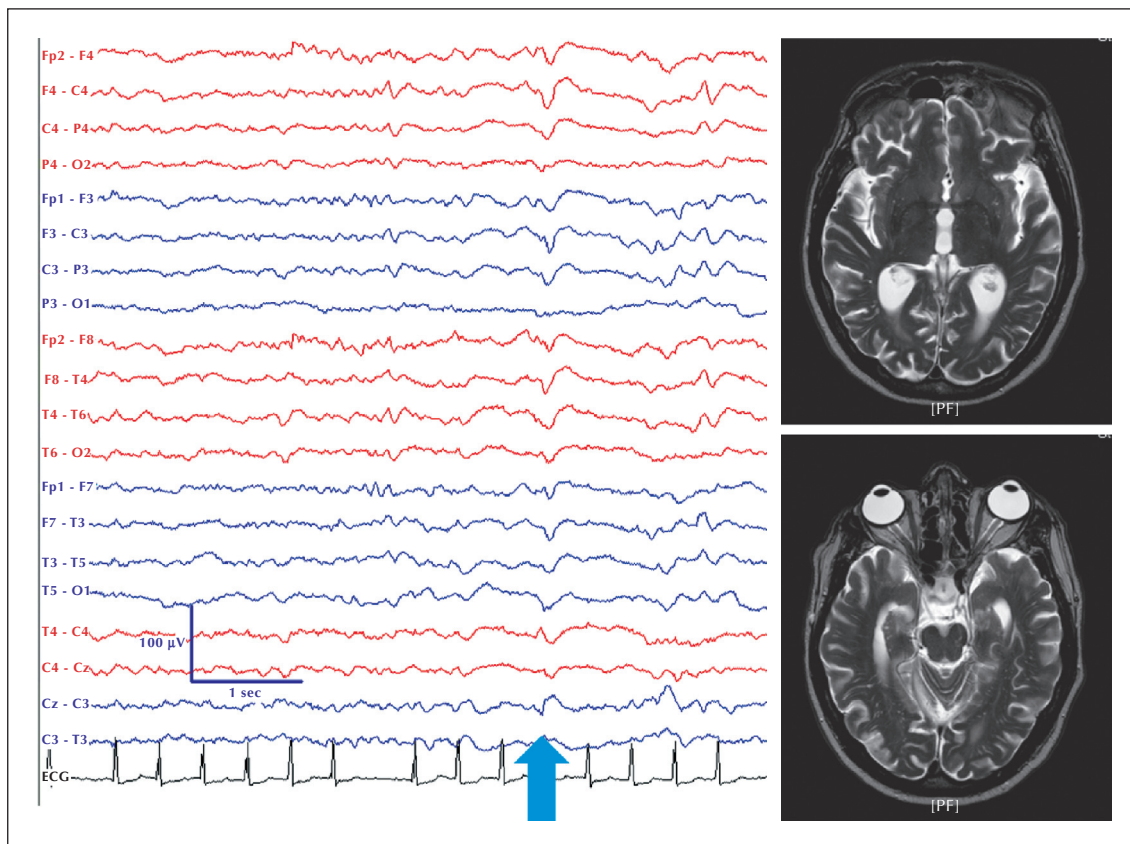


**Figure 2.** Third recording; c-vEEG monitoring over 24 hours starting on Day 7 post-insult. The patient was off propofol for two days and on triple anti-seizure treatment (see text). (A and B) Raw EEG data from the first and last hour of the monitored period; the respective one-hour hypnospectrograms, derived from the EEG activity recorded from Fz, are shown in (A1) and (B1). Note the attenuation of the 2-Hz signal in (B1) at the end of the 24-hour period of monitoring. The hypnospectrogram was developed to explore the entire night-time frequency plot based on the Fast Fourier Transformation (FFT), for the 0.05-20-Hz range with a step frequency of 0.05 Hz (Kokkinos *et al.*, 2009). No filter was applied to the processed electrophysiological data.

A 24-hour continuous vEEG (c-vEEG) was performed on Day 7 post-insult to assess the patient's rate of progress, using a Nicolet carefusion machine (*figure 2*). He was still comatose but stable without concurrent infections and had been off sedation for the last two days. Anti-seizure medication included PHT at 300 mg od and VPA was increased to 400 mg tds with levetiracetam at 1500 mg bd, added the day before c-vEEG commenced. In the beginning of the monitored period, the EEG showed GPEDs at 1.5-4 Hz without evolution of frequency or clear biological activity in between the discharges (*figure 2A*), while towards the end, GPEDs were less frequent and low-voltage theta/delta biological rhythms had emerged (*figure 2B*). Progression, however, was gradual; hour-to-hour changes were imperceptible to the trained eye, and even short periods of more robust GPEDs and less biological activity were observed even in the later parts of the monitored period. The tenuous visual impression of remitting NCSE was confirmed when

hypnospectrograms from the first and the last hour were compared (*figure 2A1 and 2B1*).

By Day 17, he was transferred to the ward and remained in a minimally conscious state. He was self-ventilating with minimal oxygen assistance and had spontaneous eye opening, but did not appear to follow instructions. Brainstem reflexes were intact, there was no hypertonía, and plantars were mute. There were no abnormal movements. When left undisturbed without any stimulation, he appeared restful with eyes closed, but would wake upon auditory stimulation and responded to deep pain with grimacing and head movements. Anti-seizure medication included PHT at 300 mg od, VPA at 2500 mg od, and levetiracetam at 1500 mg bd. Despite the increase of VPA dose, blood levels had remained low, up to 23 mg/l; PHT levels were low too, below 10 mg/l, but there was no clinical evidence of seizure activity. A follow-up vEEG showed infrequent spontaneous interictal epileptic discharges, but no subclinical seizure activity. During



**Figure 3.** Left: fourth EEG on Day 17 post-insult; the patient appeared to be sleeping and the EEG pattern appeared to be appropriate, with fast oscillations over the frontocentral areas, akin to sleep spindles and a phasic midline response to a single brief noise (blue arrow). Right: T2-weighted MRI on Day 45 post-insult showed no significant anoxic brain damage.

periods of low vigilance, cerebral rhythms showed a sleep-like pattern with few traces of fast bilateral frontocentral oscillations, akin to sleep spindles (*figure 3*). Spontaneous and induced arousals were associated with bilateral synchronous paroxysms of spike-wave. Brain MRI on Day 45 post insult showed no evidence of significant cortical injury, including laminar necrosis (*figure 3*), and intracranial MRA was unremarkable. Unfortunately, further recovery was repeatedly hindered by cardiac arrhythmias and chest and kidney infections, and the patient finally succumbed two and a half months after the initial insult during the course of severe pneumonia.

## Discussion

NCSE in this patient was remarkable regarding the slow, non-evolving GPED frequency (*figure 1A and B*) and the unexpected EEG response to reloading with propofol that raised the suspicion of NCSE (*figure 1C and D*). The lack of clear ischaemic changes on brain MRI one month and a half post-insult and the EEG improvement (*figure 3*) strongly suggest that

the slow GPED pattern represented epileptic activity associated with largely reversible hypoxia rather than an epiphenomenon of cerebral anoxia. Although a degree of residual hypoxic encephalopathy was likely (explaining also the minimal conscious state shortly after his discharge from the ICU), the MRI and the improved EEG would suggest that cognitive improvement could be possible in the longer term had his cardio-pulmonary functions allowed survival.

### “Paradoxical” effect of propofol

The first electrographic evidence for underlying epileptic activity was the complete disappearance of the slow GPEDs upon reinstatement of propofol and the concurrent appearance of biological activity that remained continuous for 7 minutes.

Propofol is a short-acting anaesthetic, also used in the ICU for termination of convulsive status epilepticus (Parviainen *et al.*, 2006). The appearance of biological activity when propofol infusion was restarted 13 minutes after its complete discontinuation was “paradoxical” with regard to its anaesthetic properties, as one would expect suppression rather than

emergence of cerebral rhythms, but was explicable on account of propofol's anti-seizure action. Such anti-seizure reloading after an "off-treatment" period long enough to outlast propofol's short elimination half time, might also explain its increased effectiveness expressed by the emergence of continuous biological activity instead of the brief fragments seen before its discontinuation (*figure 1A*). It follows that the slow GPEDs were interpretable as reflecting epileptic activity in the setting of cerebral hypoxia-ischaemia, the degree of which was impossible to determine at that time. *A posteriori*, the brief fragments of frontal delta activity in *figure 1A* may have provided a hint of biological activity, being masked by the slow GPEDs, but they would certainly be insufficient to suggest NCSE in their own right had the "paradoxical" reaction to propofol not have occurred.

By virtue of its pharmacokinetic properties, propofol's major advantages include fast seizure control and fast recovery from anaesthesia that may allow meaningful neurological assessment soon after the agent is stopped (Marik, 2004). Based on the latter, its temporary discontinuation is part of our routine ICU vEEG clinical practice, particularly in patients with GPEDs. We have to emphasize that this was the first time we witnessed propofol's anti-seizure action prevailing so clearly over its anaesthetic effect. It is possible that the net effect may chiefly depend on the GPED substrate; in the post-hypoxic state, it is conceivable that a degree of cerebral anoxia and epileptic activity usually co-exist, and emergence of biological activity is perhaps only to be expected when the former is minimal. Similar mechanisms may also account for the relatively infrequent occurrence of both the clinical and EEG endpoints of the secondary diagnostic criterion of NCSE (*table 1*); a clear clinical improvement after administration of a rapidly acting antiepileptic drug, such as lorazepam, is rare in comatose patients (Treiman *et al.*, 1998). Additional reasons for incomplete responses to both IV administration of lorazepam and propofol reloading may include possible co-existent confounding conditions (for instance, a septic encephalopathy), or simply, high resistance of the NCSE to the anti-seizure drugs used.

### The role of vEEG in the diagnosis of NCSE

Several studies of patients with post-cardiac arrest NCSE have clearly indicated that c-vEEG is superior to vEEG because:

- i) It captures significantly more seizures that satisfy the diagnostic criteria in *table 1* which may not occur during vEEG;
- ii) A diagnosis of NCSE is made faster;
- iii) It can better monitor response to antiepileptic treatment.

On the other hand, by providing a detailed vEEG "snapshot", and allowing focused "magnifying glass" electroclinical analysis of the patterns and their reactivity, a vEEG has rightly been recommended as the test of choice for the evaluation of specific clinical signs, suspected as seizure manifestations (Koenig and Kaplan, 2013).

This report demonstrates that, despite the aforementioned diagnostic limitations, there is certainly more to vEEG. Based on its strategic use, it may be possible to detect diagnostic clues that are difficult to appreciate by c-vEEG monitoring when it is only analyzed using quantitative EEG trending algorithms that compress time and simplify reading, and does not contain a "window of sedation" (temporary withdrawal of anesthesia) under video monitoring. Our sequential recordings of D2, D4, and the 24-hour c-vEEG on D7 indicate that the GPED frequency changed gradually from  $\leq 1$  Hz to 1.5-4 Hz within a week, probably without evolution of frequency (*figures 1 and 3*) to satisfy the current NCSE diagnostic criteria. Interestingly, we observed a non-evolving GPED pattern of similar frequency (1.5-6 Hz), also on Day 7 post-insult, in another patient, who ultimately had meaningful neurological outcome (Sreedharan *et al.*, 2012). These observations indicate that an inflexible low cut-off frequency for non-evolving GPEDs as a primary diagnostic criterion for NCSE may lead to a minority of patients with NCSE not being diagnosed as such (see also Fernández-Torre *et al.*, 2012a, Fernández-Torre *et al.*, (2012a, 2012b)), and suggest that propofol withdrawal and reloading after a suitable time may be an additional useful diagnostic manoeuvre.

### Slow or non-evolving GPEDs and NCSE; how can this be possible?

In the post-cardiac arrest coma, GPEDs are understood as paroxysmal activity related to the hypoxic neuronal dysfunction. At one end of the spectrum, GPEDs may express epileptic activity in the reversibly hypoxic brain, while at the opposite end may reflect the last gasps of the irreversibly anoxic, expiring brain. The relatively limited EEG phenomenology does not allow assessment of the severity of the underlying hypoxic-ischaemic damage and navigation through the continuum between the two ends relies primarily on GPED frequency and temporal evolution. In our patient, the non-evolving and very slow GPEDs would erroneously shift diagnosis from possible NCSE to irreversible cerebral anoxia, yet, the pattern reflected NCSE, but how?

In contrast to the robust ictal patterns observed in the epilepsy surgery telemetry unit, ictal EEG changes in comatose patients may appear understated, analogous to the generally subtle clinical seizure signs.

Ictal periodic electrographic patterns may show slower frequencies and lower voltage, hesitant evolution, or both, as they arise from a depressed brain, due to the induced hypoxia-ischaemia and the concurrent anaesthesia. Indeed, we do know that slower discharge repetition rates may reflect an epileptic state, for instance, late in the transition from the overt generalised convulsive status to subtle status (Treiman *et al.*, 1990; Sutter and Kaplan, 2013). Such uncertainties may explain the relatively low inter-observer agreement of the EEG diagnosis of NCSE, particularly when GPEDs are concerned (Ronner *et al.*, 2009) and the wide variation in the reported incidence of NCSE in the ICU environment. GPED frequency is certainly an important diagnostic criterion, and probably the core, but one may have to rely on other diagnostic features too, including possible effects of manoeuvred anaesthesia or the hesitant appearance of some theta or delta activity between the bursts (figure 1), as also reported by Milani *et al.* (2014) for the only survivor of their five patients with GPEDs. Diagnostic criteria proposed before the widespread use of therapeutic hypothermia, and perhaps henceforth of controlled normothermia (Nielsen *et al.*, 2013), need to become more flexible and versatile. The American Clinical Neurophysiology Society recently published a comprehensive list of EEG descriptors and important modifiers to improve identification of NCSE through clinical research (Hirsch *et al.*, 2013). This report may be a small contribution to this end. □

### Acknowledgements and disclosures.

This study was supported by the ARMOR EU research project (European Commission under the Seventh Framework Program [FP7/2007-2013] agreement number 287720).

None of the authors have any conflict of interest to disclose.

### References

Cheng S. Non-convulsive status epilepticus in the elderly. *Epileptic Disord* 2014; 16: 385-94.

Drislane FW, Kaplan PW. Non convulsive seizures and status epilepticus. In: Fisch BJ, ed. *Epilepsy and Intensive Care Monitoring*. New York: Demos Medical Publishing, 2009, p. 287-307.

Fernández-Torre JL, Rebollo M, Gutiérrez A, López-Espadas F, Hernández-Hernández MA. Nonconvulsive status epilepticus in adults: Electroclinical differences between proper and comatose forms. *Clin Neurophysiol* 2012a; 123: 244-51.

Fernández-Torre JL, Kaplan PW, Rebollo M, Gutiérrez A, Hernández-Hernández MA, Vázquez-Higuera JL. Ambulatory non-convulsive status epilepticus evolving into a malignant form. *Epileptic Disord* 2012b; 14(1): 41-50.

Hirsch LJ, LaRoche SM, Gaspard N, et al. American Clinical Neurophysiology Society's Standardized Critical Care EEG Terminology: 2012 version. *J Clin Neurophysiol* 2013; 30: 1-27.

Jirsch J, Hirsch LJ. Nonconvulsive status epilepticus in critically ill and comatose intensive care unit patients. In: Kaplan PW, Drislane FW, eds. *Nonconvulsive status epilepticus*. New York: Demos Medical Publishing, 2008, p. 175-86.

Koenig MA, Kaplan PW, Thakor NV. Clinical neurophysiologic monitoring and brain injury from cardiac arrest. *Neurol Clin* 2006; 24: 89-106.

Koenig MA, Kaplan PW. Clinical neurophysiology in acute coma and disorders of consciousness. *Semin Neurol* 2013; 33: 121-32.

Kokkinos V, Koupparis A, Stavrinou ML, Kostopoulos GK. The hypnospectrogram: An EEG power spectrum based means to concurrently overview the macroscopic and microscopic architecture of human sleep. *J Neurosci Methods* 2009; 185: 29-38.

Marik PE. Propofol: Therapeutic indications and side-effects. *Curr Pharm Des* 2004; 10: 3639-49.

Milani P, Malissin I, Tran-Dinh YR, et al. Prognostic EEG patterns in patients resuscitated from cardiac arrest with particular focus on Generalized Periodic Epileptiform Discharges (GPEDs). *Neurophysiol Clin* 2014; 44: 153-64.

Nielsen N, Sunde K, Hovdenes J, et al. Hypothermia network. Adverse events and their relation to mortality in out-of-hospital cardiac arrest patients treated with therapeutic hypothermia. *Crit Care Med* 2011; 39: 57-64.

Nielsen N, Wetterslev J, Cronberg T, et al. Targeted temperature management at 33°C versus 36°C after cardiac arrest. *N Engl J Med* 2013; 369: 2197-206.

Parviainen I, Uusaro A, Kälviäinen R, Mervaala E, Ruokonen E. Propofol in the treatment of refractory status epilepticus. *Intensive Care Med* 2006; 32: 1075-9.

Rittenberger JC, Popescu A, Brenner RP, Guyette FX, Callaway CW. Frequency and timing of nonconvulsive status epilepticus in comatose post-cardiac arrest subjects treated with hypothermia. *Neurocrit Care* 2012; 16: 114-22.

Ronner HE, Ponten SC, Stam CJ, Uitdehaag BM. Inter-observer variability of the EEG diagnosis of seizures in comatose patients. *Seizure* 2009; 18: 257-63.

Sreedharan J, Gourlay E, Evans MR, Koutroumanidis M. Falsely pessimistic prognosis by EEG in post-anoxic coma after cardiac arrest: The borderland of nonconvulsive status epilepticus. *Epileptic Disord* 2012; 14: 340-4.

Sutter R, Kaplan PW. The neurophysiologic types of non-convulsive status epilepticus: EEG patterns of different phenotypes. *Epilepsia* 2013; 54(6): 23-7.

Treiman DM, Meyers PD, Walton NY, et al. A comparison of four treatments for generalized convulsive status epilepticus. *N Engl J Med* 1998; 339: 792-8.

Treiman DM, Walton NY, Kendrick C. A progressive sequence of electroencephalographic changes during generalized convulsive status epilepticus. *Epilepsy Res* 1990; 5: 49-60.

Zandbergen EGJ, de Haan RJ, Stoutenbeek CP, Koelman JH, Hijdra A. Systematic review of early prediction of poor outcome in anoxic ischaemic coma. *Lancet* 1998; 352: 1808-12.

**TEST YOURSELF**

The following questions are based on the secondary criterion for non-convulsive status epilepticus, as adapted from Jirsch and Hirsch, 2008. This states:

*“Significant improvement in clinical state or appearance of previously absent normal EEG patterns temporary coupled to acute administration of a rapidly acting antiepileptic drug. Resolution of the “epileptiform” discharges leaving diffuse slowing, without normal EEG patterns or clinical improvement does not satisfy this criterion”.*

(1) Does the disappearance of epileptiform / paroxysmal activity after IV AED *per se* strongly suggest NCSE and why? (Or why not if it doesn't?)

(2) Does the absence of clinical response in the presence of clear EEG improvement (but not return of normal patterns) rule out NCSE? If your answer is no, state at least 2 reasons for this.

*Note: Reading the manuscript provides an answer to all questions. You can check for the correct answer by visiting the Educational Centre section of [www.epilepticdisorders.com](http://www.epilepticdisorders.com)*