

# A stroke of ill-fortune: an unexpected diagnosis following a stroke-like event

## Introduction

With the advent of intravenous thrombolysis for the treatment of acute ischaemic stroke, it has become increasingly apparent that many patients suspected of acute stroke, from 5% to 30% in some units, in fact have another diagnosis. Well-recognized causes of stroke mimic include epileptic seizures, migraine, toxic and metabolic disorders, and psychogenic disorders. Neurodegenerative disorders, generally considered to be slowly progressive conditions, are unlikely to be mistaken for stroke. Nevertheless, they can on occasion be stroke mimics, as shown by the following case.

## Discussion

This patient had a stroke-like presentation which initially defied exact diagnosis, but clinical progression and brain biopsy established a diagnosis of sporadic Creutzfeldt–Jakob disease. Creutzfeldt–Jakob disease should be included among known stroke mimics, albeit a rare cause thereof.

Although vascular disorders, including cerebral vasculitis, and sporadic Creutzfeldt–Jakob disease both feature in the differential diagnosis of patients with rapidly progressive cognitive decline who undergo brain biopsy (Schott et al, 2010; Wong et al, 2010; Newey et al, 2013), nonetheless stroke-like presentations of Creutzfeldt–Jakob disease have rarely been reported (Panagariya et al, 1999; Kamogawa et al, 2009). This is perhaps surprising in view of the frequency of visual complaints in Creutzfeldt–Jakob disease, said to be present in about 10% of patients at disease presentation (Armstrong, 2006) and including homonymous visual field defects (Vargas et al, 1995). However, it is perhaps easy to

understand why a new onset visual field defect in a patient with prior stroke history, as in the reported case, might be considered likely to be of vascular origin (common) rather than Creutzfeldt–Jakob disease (rare).

The differential diagnosis of stroke-like episodes and cognitive decline in the 6th decade should also include mitochondrial disorder (e.g. mitochondrial encephalomyopathy, lactic acidosis and stroke-like episodes; MELAS) and cerebral autosomal dominant arteriopathy with subcortical infarcts and leukoencephalopathy (CADASIL).

This case illustrates the difficulty of early Creutzfeldt–Jakob disease diagnosis – it was unsuspected before the brain biopsy. The diagnosis of Creutzfeldt–Jakob disease is often unexpected, not least because of the frequency of ‘atypical’ or unusual variants (Jacquin et al, 2014). Use of internationally agreed diagnostic criteria for Creutzfeldt–Jakob disease may sometimes help in establishing the diagnosis although this may not be the case in such unusual presentations (Ali et al, 2013). Clearly such delayed diagnosis has profound implications for early

## Case Report

A 56-year-old right-handed woman presented with difficulty identifying objects in her left visual field. Onset was within the past few weeks although she could not recall a clear ictus. More recently she had also noticed some slurring of speech and unsteadiness when walking. Ten years earlier she had a stroke causing left facial drop and hemiparesis from which she had largely recovered. At the time she smoked but had abstained since, and had no other vascular risk factors. Her only medication was aspirin.

Salient findings on neurological examination were left homonymous hemianopia, dysarthria, mild left-sided weakness (longstanding), global hyperreflexia with bilateral upgoing plantar responses, and ataxic gait with left-sided past-pointing and dysidiadochokinesia. Because of the subacute onset of new symptoms and the previous history of stroke, a vascular mechanism was suspected, possibly vertebral artery dissection with showers of emboli, multiple territory strokes or cerebral vasculitis.

Initial investigation with routine blood tests, including autoantibodies and syphilis serology, was completely negative. Magnetic resonance imaging of the brain showed small vessel ischaemic change in pontine and periventricular areas, but on diffusion-weighted imaging no acute changes were seen. Mild global brain atrophy was noted. Computed tomography angiography showed no dissection. Transthoracic echocardiogram showed no evidence of endocarditis or patent foramen ovale. CSF analysis showed normal protein and cell count, and CSF and serum-matched oligoclonal IgG bands.

Despite the normality of these investigations, the patient’s condition deteriorated rapidly over the first month of admission, with episodes of confusion and apparent blindness (she could not cooperate with visual field testing). Cognitive testing showed impairments in all domains (Mini-Mental State Examination score 18/30, Addenbrooke’s Cognitive Examination-Revised score 44/100). Electroencephalography showed some non-specific slowing but no other features.

In light of relentlessly progressive clinical deterioration, which left the patient bed bound and unable to follow commands, and the absence of a diagnosis, a brain biopsy was deemed to be appropriate. A right frontal biopsy was undertaken without complication. It showed neuronal loss and grey matter microvacuolar spongiform change. There was no evidence of ischaemia, vasculitis or intravascular lymphoma. There were no amyloid plaques. Immunohistochemistry for prion protein showed a granular/synaptic pattern of staining. The combination of clinical and pathological findings was consistent with a diagnosis of sporadic Creutzfeldt–Jakob disease.

Subsequently available test results showed weakly positive CSF 14-3-3 protein and elevated levels of CSF S100b (0.58 ng/ml, normal <0.41 ng/ml), and repeat electroencephalography showed triphasic waves. The patient also developed myoclonic jerks. These findings were consistent with the tissue diagnosis of Creutzfeldt–Jakob disease.

**Dr M Ghadiri-Sani** is Specialist Registrar in Neurology, **Dr A Sekhar** is Consultant Neurologist and **Dr AJ Larner** is Consultant Neurologist in the Walton Centre for Neurology and Neurosurgery, Liverpool L9 7LJ

Correspondence to: Dr AJ Larner (a.larner@thewaltoncentre.nhs.uk)

intervention. Early diagnosis of dementia syndromes is now thought to represent the best hope for the future, through use of disease-modifying medications whenever these become available. This will be a significant challenge in Creutzfeldt–Jakob disease, hence the need to consider the possibility of this diagnosis even if remote, for example as an unusual form of stroke mimic. Both stroke physicians and general physicians should therefore be aware of this possible presentation of a rare diagnosis. **BJHM**

Ali R, Barborie A, Larner AJ, White RP (2013) Psychiatric presentation of sporadic Creutzfeldt–Jakob disease: a challenge to current diagnostic criteria. *J Neuropsychiatry Clin Neurosci* **25**: 335–8 (doi: 10.1176/appi.neuropsych.13020025)

Armstrong RA (2006) Creutzfeldt–Jakob disease and vision. *Clin Exp Optom* **89**: 3–9

Jacquin A, Deramecourt V, Bakchine S, Muraige

CA, Pasquier F (2014) Unusual features of Creutzfeldt–Jakob disease followed up in a memory clinic. *J Neurol* **261**: 696–701 (doi: 10.1007/s00415-014-7246-6)

Kamogawa K, Toi T, Okamoto K, Okuda B (2009) A case of Creutzfeldt–Jakob disease with stroke-like episode as an initial symptom [in Japanese]. *Nihon Ronen Igakkai Zasshi* **46**: 458–61

Newey CR, Sarwal A, Wisco D, Alam S, Lederman RJ (2013) Variability in diagnosing Creutzfeldt–Jakob disease using standard and proposed diagnostic criteria. *J Neuroimaging* **23**: 58–63 (doi: 10.1111/j.1552-6569.2012.00763.x)

Panagariya A, Jain RS, Sharma AK (1999) Stroke like presentation of Creutzfeldt–Jakob disease: an unusual variant. *J Assoc Physicians India* **47**: 548–50

Schott JM, Reinger L, Thom M et al (2010) Brain biopsy in dementia: clinical indications and diagnostic approach. *Acta Neuropathol* **120**: 327–41 (doi: 10.1007/s00401-010-0721-y)

Vargas ME, Kupersmith MJ, Savino PJ, Petito F, Frohman LP, Warren FA (1995) Homonymous field defect as the first manifestation of Creutzfeldt–Jakob disease. *Am J Ophthalmol* **119**: 497–504

Wong SH, Jenkinson MD, Faragher B, Thomas S,

Crooks D, Solomon T (2010) Brain biopsy in the management of neurology patients. *Eur Neurol* **64**: 42–5 (doi: 10.1159/000315032)

## LEARNING POINTS

- Stroke mimics are common, including epilepsy and migraine.
- Neurodegenerative disorders are usually slowly progressive and hence unlikely to be confused with stroke in most instances.
- The clinical features of Creutzfeldt–Jakob disease may on occasion present subacutely, for example with visual field defect, and hence be mistaken for stroke, especially in those with a prior history of stroke.
- Awareness of Creutzfeldt–Jakob disease as a possible, if infrequent, stroke mimic should be raised.

## IMAGES IN MEDICINE

# Littoral cell angioma in the spleen

Littoral cell angioma is a rare splenic vascular tumour first reported by Falk et al in 1991. This article presents a 37-year-old man who was diagnosed with littoral cell angioma in the spleen following an abdominal B-mode ultrasound examination. His past medical history showed epidemic jaundice hepatitis A. There were no positive findings on physical examination. Results of haematology laboratory tests were unremarkable. A contrast computed tomography scan of the superior and middle abdomen confirmed an enlarged spleen with an isolated hypodense and heterogeneous mass suggestive of haemangioma or hamartoma (*Figure 1*).

Given the atypical nature of the findings, the preoperative diagnosis was a benign splenic space-occupying lesion. The patient underwent splenectomy without any complications. Postoperative pathology studies with haematoxylin and eosin (*Figure 2*) and immunohistochemistry staining confirmed the diagnosis of littoral cell angioma. His postoperative course was asymptomatic and uneventful, without clinical or radiological evidence of recurrence at 2 years follow up.

It is very difficult to differentiate littoral cell angioma preoperatively from other splenic tumours as they lack specific clinical symptoms and imaging features. The

final diagnosis of littoral cell angioma mainly depends on postoperative pathological examination. Some cases depict littoral cell angioma as being related to malignant tumours of multiple organs (Bisceglia et al, 1998), so continued surveillance and postoperative follow up of littoral cell angioma patients is very important. **BJHM**

Bisceglia M, Sickel JZ, Giangaspero F, Gomes V, Amini M, Michal M (1998) Littoral cell angioma of the spleen: an additional report of four cases with emphasis on the association with visceral organ cancers. *Tumori* **84**: 595–9

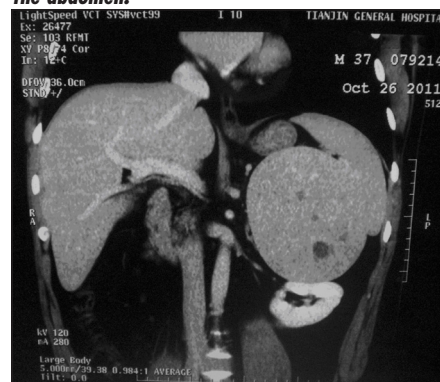
Falk S, Stutte HJ, Frizzera G (1991) Littoral cell angioma. A novel splenic vascular lesion demonstrating histiocytic differentiation. *Am J Surg Pathol* **15**: 1023–33

**Mr Chao Gao\*** is Senior Resident Doctor,  
**Dr Ya-Chen Li\*** is Resident Doctor,  
**Dr Xiang-Ming Xiao** is Resident Doctor,  
**Professor Feng Qi** is Professor of General Surgery and Associate Chief Surgeon and  
**Professor Tong Liu** is Professor of General Surgery in the Department of General Surgery, Tianjin Medical University General Hospital, Tianjin, China

Correspondence to: Professor F Qi  
(qf@medmail.com.cn)

\*These authors contributed to this work equally

**Figure 1. Contrast computed tomography scan of the abdomen.**



**Figure 2. Haematoxylin and eosin staining histopathology examination shows that the neoplasm was composed mainly of anastomosing vascular channels lined by low columnar or cuboidal epithelial cells or histiocyte.**

