

## Mixed transcortical aphasia: a case report

Elena Cecilia Rosca · Mihaela Simu

Received: 10 November 2014 / Accepted: 8 January 2015  
© Springer-Verlag Italia 2015

Dear Editor,

Mixed transcortical aphasia (MTCA) is a rare language disorder, accounting for 1.3–3 % of aphasic syndromes. It is characterized by reduced or absent spontaneous speech, severely impaired language comprehension, and preserved repetition. The most prominent characteristic is echolalia, the preserved ability to repeat automatically, without understanding the spoken language [1]. MTCA was reported in watershed infarcts involving the area between 2 major vascular territories, with significant decrease of cerebral perfusion due to cardiac arrest, hypoxia, hypotensive shock, carbon monoxide poisoning, and as a postictal epileptic phenomenon [2]. The syndrome was rarely documented in patients with internal carotid artery (ICA) occlusion [3, 4].

We report the case of BC, a 67-year-old right-handed man with 5 years of formal education and premorbid average language abilities. On admission, the patient was alert, with spontaneous verbal output confined to a few stereotyped phrases (“Oh God”); he responded to the examiner’s questions with short, poorly intelligible propositions (“Yes” “No”, “don’t know”). The neurological assessment revealed only a right Babinski sign and a right homonymous hemianopia. Assessment of sensory impairments was impossible due to severe language disturbances.

The language was tested 5 days later with Western Aphasia Battery (WAB). Repetition was additionally assessed for words (20 items), non-words (20 items), sentences of 3–9 words (10 items grammatically correct, 10 items grammatically incorrect), and foreign language propositions of maximum 7 words (3 items of each: English, French, German, Hungarian, Ukrainian). Series speech and praxis were also tested.

BC presented a severe language disorder. His spontaneous speech was limited to some utterances (“Ooh, Oooh”). The comprehension was severely affected; even to simple yes/no questions or commands, BC responded by echolalia. He gave no answers on naming subtests. On WAB repetition tasks, his performance was relatively preserved, with 4 phonemic paraphasias, 2 non-related repetitions (unrecognizable words because of the substitution of several letters), and good articulation. On additional tasks, the repetition of words and non-words was preserved with only 2 non-related repetitions; there were 5 phonemic paraphasias and 4 non-related words on sentence repetition. BC never corrected grammatically erroneous phrases when repeating. On repetition of 15 foreign language propositions, he made only 8 phonemic paraphasias and 8 non-related repetitions. The patient’s repetition errors occurred with longer words (6–8 letters) with similar performance for words (86.3 % correct) and non-words (81.8 % correct; the foreign language phrases being considered non-words). When the examiner initiated series, he continued counting (up to 6) and recited the days of the week (to Friday or Saturday).

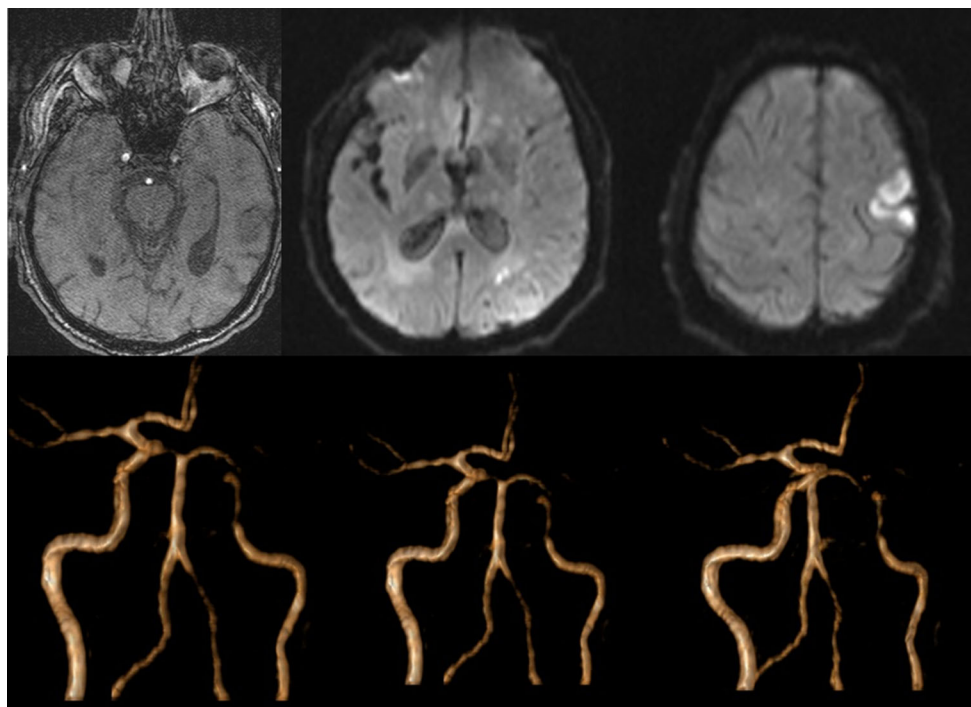
His abilities to read aloud, to comprehend written language, and to write were totally impaired. He was unable to reproduce the examiner’s movements or to use tools. The spontaneous gesturing was diminished and he was unable to perform unaided the daily living tasks such as dressing, washing, or using the toothbrush, the comb, the spoon, and

---

**Electronic supplementary material** The online version of this article (doi:10.1007/s10072-015-2069-5) contains supplementary material, which is available to authorized users.

---

E. C. Rosca (✉) · M. Simu  
Department of Neurology II, Clinical Emergency County  
Hospital, University of Medicine and Pharmacy “Victor Babes”  
Timisoara, Bd. Iosif Bulbuca nr. 10, Timisoara 300736, Romania  
e-mail: roscacecilia@yahoo.com



**Fig. 1** Multiple infarcts sparing the Broca's and Wernicke's areas in left internal carotid artery occlusion

the fork. Other cognitive functions could not be assessed due to the severe comprehension deficit.

The brain MRI revealed multiple acute left frontal and parietal ischemic lesions, varying between a few millimeters and 2.5 cm, but sparing the Broca's and the Wernicke's areas and some old lacunar infarcts in the frontal lobes. The magnetic resonance angiography demonstrated a 95 % occlusion of the left ICA (Fig. 1).

Up to date, only a few well demarcated, pure cases of MTCA have been studied in detail. Berthier, analyzing and comparing the previous cases from the literature, postulated that MTCA can be divided in at least 2 different types [1]: MTCA due to speech area isolation, where the spared perisylvian language areas support intact repetition and other linguistic abilities (such as applying syntactic rules) and MTCA due to perisylvian lesions where the patients present some paraphasias and have impaired syntactic processing, with repetition being supported by the right hemisphere, due to a relative sparing of the verbal phonological store [5].

BC's neuropsychological picture is similar to other MTCA patients with perisylvian lesions. The MRI showed no lesions of the language areas, but the presence of apraxia and hemianopia point to a more extensive cerebral dysfunction, affecting the left parietal and premotor areas possibly due to the hypoperfusion caused by ICA occlusion.

The present case supports the idea that isolation of speech area is not the unique anatomical mechanism for

MTCA and the terms of "isolation of the speech area" and "mixed transcortical aphasia" should not be used interchangeably. Although similarities are evident among MTCA patients, there are also some subtle differences in the pattern of impairments suggesting that there may be different subtypes of MTCA resulting from distinct linguistic mechanisms (Supplementary Material 1).

**Acknowledgments** The family gave its informed consent on behalf of the patient to participate in the study.

**Conflict of interest** The authors report no conflict of interests.

## References

- Berthier ML (1999) Mixed transcortical aphasia. In: Berthier ML (ed) *Transcortical aphasias*. Psychology Press, New York, pp 119–150
- Benson DF, Ardila AA (1996) *A clinical perspective*. Oxford University Press, Oxford
- Bogousslavsky J, Regli F, Assal G (1988) Acute mixed transcortical aphasia: a carotid occlusion syndrome with pial and watershed infarcts. *Brain* 11:631–641
- Mendez M (2002) Proeminent echolalia from isolation of the speech area. *J Neuropsychiatry Clin Neurosci* 14:3
- Grossi D, Trojano L, Chiacchio L, Soricelli A, Mansi L, Postiglione A, Salvatore M (1991) Mixed transcortical aphasia: clinical features and neuroanatomical correlates. A possible role of the right hemisphere. *Eur Neurol* 31(4):204–211