

# Recurrent amaurosis fugax and hemichorea: limb-shaking TIA

Edward T Littleton,<sup>1</sup> Nicholas Glover,<sup>2</sup> Alok Tiwari<sup>3</sup>

<sup>1</sup>Department of Neurology, University Hospitals Birmingham NHS Foundation Trust, Queen Elizabeth Hospital, Birmingham, UK

<sup>2</sup>Department of Ophthalmology, University Hospitals Birmingham NHS Foundation Trust, Queen Elizabeth Hospital, Birmingham, UK

<sup>3</sup>Department of Vascular Surgery, University Hospitals Birmingham NHS Foundation Trust, Queen Elizabeth Hospital, Birmingham, UK

## Correspondence to

Dr Edward T Littleton, University Hospitals Birmingham NHS Foundation Trust, Queen Elizabeth Hospital, Mindelsohn Way, Edgbaston, Birmingham B15 2WB, UK; littletonedward@aol.com

Accepted 3 January 2015

## THE CASE

A 61-year-old woman gave a 4-month history of abnormal movements of the left arm and of episodic visual disturbance in the right eye. Each symptom would last a few seconds, and would occur when sitting, though at separate times from one another. There were involuntary twisting movements of the left elbow and wrist, followed by immediate return to normal function. There was no altered consciousness. The visual symptoms manifested as a shadow coming across her right eye, with loss of the lower half of the visual field in the right eye only (proven by covering either eye). The symptoms, both ocular and choreiform, though initially infrequent, increased during the first 6 weeks to 12 times per day. Three months after symptom onset, when she first attended the neurology clinic, their frequency had reduced to three times per day.

She had hypertension, chronic obstructive pulmonary disease and she smoked cigarettes. She took simvastatin, indapamide, losartan and Symbicort and Ventolin inhalers but had not taken antiemetic or neuroleptic drugs.

On examination between episodes, the reflexes in the left arm were brisker than on the right with no tremor or abnormal movements. Ophthalmic examination was normal, with no retinal, vascular or optic disc abnormalities. Cardiac examination was normal. She was in sinus rhythm and her blood pressure was 100/66 mm Hg.

## INVESTIGATIONS

MR scan of brain (axial fluid-attenuated inversion recovery (FLAIR)) showed a single 9×6 mm area of high signal within the right centrum semiovale posteriorly, probably an infarct (figure 1). The lesion was not bright on diffusion-weighted images and was not seen on apparent diffusion coefficient images; hence it was probably several months old at the time of the scan, 5 months after symptom

onset. There was little evidence of cerebral small vessel ischaemia. Ultrasound scan of the carotids showed an 80–90% right internal carotid artery stenosis, caused by atherosclerotic plaque just above the carotid bifurcation. On the left, there was 20% stenosis at the same level. MR angiogram showed that the Circle of Willis was normal.

## DIFFERENTIAL DIAGNOSIS

Transient involuntary limb movements can be due to focal seizures or may represent a hyperkinetic movement disorder, perhaps of autoimmune or neurodegenerative aetiology. The strictly unilateral distribution of the movements made autoimmune or neurodegenerative causes unlikely and suggested an underlying structural or ischaemic cause. However, it was the co-occurrence of the limb movements with amaurosis fugax in the contralateral eye that clearly implicated two spatially distinct anatomical areas, both within the carotid vascular territory, and suggested a vascular cause.

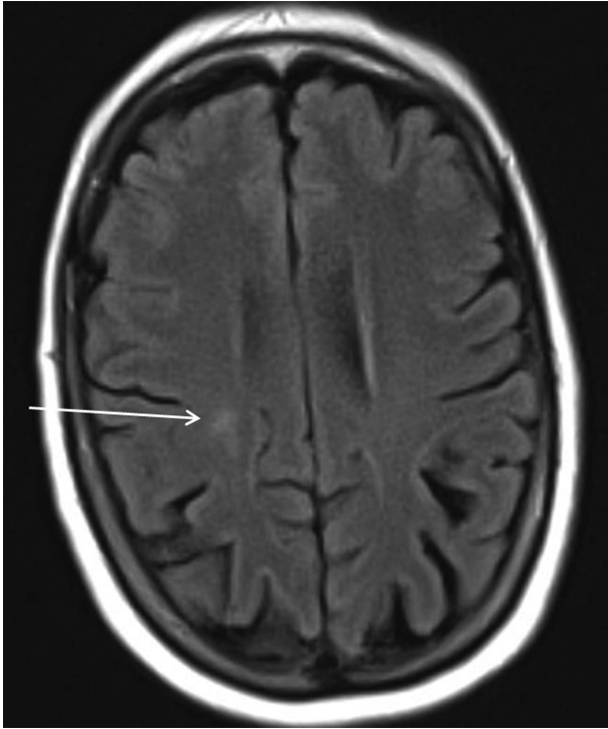
## MANAGEMENT

Within days of starting aspirin 75 mg daily her left upper limb symptoms stopped. However, the right eye visual loss episodes continued—even after adding clopidogrel 75 mg daily—until she underwent a right carotid endarterectomy 6 months after symptom onset. This was performed using a retrojugular approach to remove a calcified plaque with a very friable centre. The arteriotomy was closed with a pericardial patch, with excellent Doppler signals post procedure, indicating good right internal carotid artery flow. She has had no further symptoms in the year since; an ultrasound scan has confirmed no re-stenosis.

## DISCUSSION

In a series of studies published in the 1950s and onwards, Miller Fisher

**To cite:** Littleton ET, Glover N, Tiwari A. *Pract Neurol* Published Online First: [please include Day Month Year] doi:10.1136/practneurol-2014-000961



**Figure 1** MRI fluid-attenuated inversion recovery image demonstrating probable infarct in right centrum semiovale.

recognised that monocular visual symptoms in the eye ipsilateral to a stenotic carotid artery often heralded imminent hemispheric stroke.<sup>1</sup> He formed the opinion that recurrent transient ischaemic attacks (TIAs) with the same pattern of clinical features were associated with arterial stenosis and were flow-related. In the same report he provided an early description of limb-shaking TIAs, reporting cases where the affected limb was described as “trembling, shaking, twisting, drawing up or moving irregularly”, and reported the occurrence of brief episodes of hemiballismus preceding stroke.

There have been case reports of sustained, rather than intermittent, movement disorders related to hypoperfusion. Parées *et al*<sup>2</sup> described a patient presenting with continuous choreiform movement of an arm and leg, and severe stenosis of the contralateral extracranial internal carotid artery. MR scan of brain showed no infarcts, but technetium<sup>99m</sup>-single photon emission computed tomography scanning showed hypoperfusion of the contralateral thalamus and putamen. The movement disorder gradually resolved over 3 months—following carotid stenting—and the perfusion deficit had improved at follow-up. Similarly, Morigaki *et al*,<sup>3</sup> and Galea *et al*,<sup>4</sup> described patients with continuous hemichorea, with resolution of symptoms being either immediate or delayed by up to 6 months following endarterectomy.

Unfortunately, our patient did not undergo transcranial Doppler and MR perfusion studies. Finding microemboli in the middle cerebral artery would have favoured thromboembolism as the mechanism of

these neurological events. Finding a reduction of cerebral blood volume and delayed mean transit time in the hemisphere ipsilateral to the carotid stenosis would have been additional circumstantial evidence favouring hypoperfusion as the mechanism.

The large number of discrete events and the brief and transient nature of her chorea were unusual. The time course of the choreiform movements was in keeping with descriptions of limb-shaking TIAs, which usually last less than 5 min, with about a third of patients experiencing the symptoms upon standing up.<sup>5</sup> Usually the affected limb feels weak during or following the shaking attack. There is an association with severe cervical carotid artery stenosis. The pathophysiology of the shaking is undetermined, but may result from cortical or subcortical ischaemia. Yoon and Kim<sup>6</sup> performed electromyography on a patient with brief episodes of arm shaking upon standing and found that the recorded muscle activity was consistent with negative myoclonus (asterixis).

For choreiform TIAs, the thalamus and subthalamic nuclei tend to be implicated. Chorea can be generated by disruption at a variety of sites in an interlinked circuit of structures, which also include the putamen and caudate nucleus, within the anterior circulation. However, observations in patients with moyamoya disease indicate that the differentiation between choreiform and limb-shaking TIAs and their relative anatomical correlates may not be so clear-cut.<sup>7 8</sup> Our patient had an infarct in the white matter of the centrum semiovale, although this may simply reflect her state of carotid hypoperfusion and risk of further watershed territory infarction, rather than being the actual site of generation of the chorea.

Her episodes of hemichorea and amaurosis fugax occurred often while sitting, rather than upon rising or after prolonged standing, the circumstances normally associated with transient hypotension. She did not have postural hypotension and the cause seems most likely to be the critically narrowed cervical internal carotid artery, with hypoperfusion of the right middle cerebral artery and right ophthalmic artery. It is perhaps counterintuitive that the motor and ocular symptoms should occur separately. However, Miller Fisher described patients with numerous episodes of transient monocular visual loss, who also had episodes of transient contralateral hemiparesis, and he noted that the two phenomena often occurred at separate times. This may be because the different collateral supplies to the cerebral hemisphere and retina differentially modify the effects of impaired carotid perfusion.

The co-occurrence of hemichorea and amaurosis fugax is most unusual. Knoflach *et al*,<sup>9</sup> performed a questionnaire study on patients with known TIA or stroke and extracranial internal carotid artery occlusion. In this already highly selected group, 29% reported limb shaking (defined as ‘trembling’ or ‘jerking’) only, 10% amaurosis fugax only and 3%

reported both. Patients were not specifically questioned for hemichorea. Their study likely overestimates the occurrence of these phenomena in the wider patient population, with less severe degrees of stenosis.

**Contributors** ETL wrote the majority of the text and revisions. NG wrote the text concerning the ophthalmological findings in the patient and AT wrote the text concerning the vascular surgical treatment of this patient. All three authors reviewed the original text and made amendments.

**Competing interests** None.

**Patient consent** Obtained.

**Ethics approval**

**Provenance and peer review** Not commissioned, externally peer reviewed. This paper was reviewed by David Werring, London, UK.

## REFERENCES

- 1 Fisher CM. Concerning recurrent transient cerebral ischemic attacks. *Can Med Assoc J* 1962;86:1091–9.
- 2 Pareés I, Pujadas F, Hernández-Vara J, *et al.* Reversible hemichorea associated with extracranial carotid artery stenosis. *J Neurol Sci* 2011;300:185–6.
- 3 Morigaki R, Uno M, Suzue A, *et al.* Hemichorea due to hemodynamic ischemia associated with extracranial carotid artery stenosis. Report of two cases. *J Neurosurg* 2006;105:142–7.
- 4 Galea I, Norwood F, Phillips MJ, *et al.* Pearls & Oysters: resolution of hemichorea following endarterectomy for severe carotid stenosis. *Neurology* 2008;71:e80–2.
- 5 Persoon S, Kappelle LJ, Klijn CJ. Limb-shaking transient ischaemic attacks in patients with internal carotid artery occlusion: a case-control study. *Brain* 2010;133(Pt 3): 915–22.
- 6 Yoon Y, Kim JS. Limb-shaking TIA: an asterixis. *Neurology* 2013;81:931–2.
- 7 Im SH, Oh CW, Kwon OK, *et al.* Involuntary movement induced by cerebral ischemia: pathogenesis and surgical outcome. *J Neurosurg* 2004;100:877–82.
- 8 Lyoo CH, Kim DJ, Chang H, *et al.* Moyamoya disease presenting with paroxysmal exercise-induced dyskinesia. *Parkinsonism Relat Disord* 2007;13:446–8.
- 9 Knoflach M, Matosevic B, Meinhart M, *et al.* Prognostic relevance of limb shaking in symptomatic carotid artery occlusion. *Cerebrovasc Dis* 2011;32:35–40.