




ELSEVIER

Contents lists available at ScienceDirect

## Neuropsychologia

journal homepage: [www.elsevier.com/locate/neuropsychologia](http://www.elsevier.com/locate/neuropsychologia)

## Holmes and Horrax (1919) revisited: Impaired binocular fusion as a cause of “flat vision” after right parietal brain damage – A case study



Anna-Katharina Schaadt<sup>a,b,\*</sup>, Stephan A. Brandt<sup>c</sup>, Antje Kraft<sup>c,d</sup>, Georg Kerkhoff<sup>a,b,\*</sup>

<sup>a</sup> Clinical Neuropsychology Unit & Neuropsychological Outpatient Service, Saarland University, Campus, Building A.1.3., 66123 Saarbruecken, Germany

<sup>b</sup> International Research and Training Group “Adaptive Minds” (IRTG 1457), Saarland University, Saarbruecken, Germany

<sup>c</sup> Campus Charité Mitte, CC 15: Neurology, Neurosurgery and Psychiatry, Vision and Motor System Group, Department of Neurology with Experimental Neurology, Charité Universitaetsmedizin Berlin, Charitéplatz 1, 10117 Berlin, Germany

<sup>d</sup> Berlin Institute of Health, Charité Universitaetsmedizin Berlin, Berlin, Germany

## ARTICLE INFO

## Article history:

Received 23 September 2014

Received in revised form

15 January 2015

Accepted 21 January 2015

Available online 22 January 2015

## Keywords:

Binocular vision

Stereopsis

Fusion

Depth perception

Parietal lobe

V6/V6A

## ABSTRACT

The complete loss of binocular depth perception (“flat vision”) was first thoroughly described by [Holmes and Horrax \(1919\)](#), and has been occasionally reported thereafter in patients with bilateral posterior-parietal lesions. Though partial spontaneous recovery occurred in some cases, the precise cause(s) of this condition remained obscure for almost a century. Here, we describe a unique patient (EH) with a large right-sided occipito-parietal hemorrhage showing a complete loss of visual depth perception for several months post-stroke. EH could well simultaneously describe multiple visual objects – hence did not show simultanagnosia – but at the same time was completely unable to estimate their distance from him. In every 3-D visual scene objects appeared equidistant to him, thus experiencing a total loss of depth perception (“flat vision”). Neurovisual assessments revealed normal functions of the eyes. EH showed bilateral lower field loss and a severely impaired binocular convergent fusion, but preserved stereopsis. Perceptual re-training of binocular fusion resulted in a progressive and finally complete recovery of objective binocular fusion values and subjective binocular depth perception in a far-to-near-space, gradient-like manner. In parallel, visual depth estimation of relative distances improved, whereas stereopsis remained unchanged. Our results show that a complete loss of 3-D depth perception can result from an isolated impairment in binocular fusion. On a neuroanatomical level, this connection could be explained by a selective lesion of area V6/V6A in the medial occipito-parietal cortex that has been associated with the integration of visual space coordinates and sustained eye-positions into a cyclopean visual 3-D percept.

© 2015 Elsevier Ltd. All rights reserved.

### 1. Introduction

The three-dimensional (3-D) percept we perceive as our visual world requires the continuous unification of the two disparate images provided by our eyes (binocular fusion). Binocular fusion depends on a widespread neural network ranging from the frontal eye fields and brain stem oculomotor nuclei for proper eye alignment (convergence and divergence eye movements) to striate and extrastriate visual areas in order to merge the monocular images

into a refined 3-D percept ([Skelton and Kertesz, 1991](#); [Alkan et al., 2011](#); [Anzai and DeAngelis, 2010](#)). A loss of single components in this neurocomputational system may cause distinct deficits in visual space perception, like diplopia or astereopsis, among others ([Hart, 1969](#), [Kraft et al., 2014](#)). Probably, the most severe sequel is a total loss of binocular depth perception, resulting in a completely “flat” visual world, like on a picture.

This condition was first reported by [Holmes and Horrax \(1919\)](#) in their description of patient WF who suffered from a full loss of 3-D vision following a bilateral posterior head-wound caused by a gunshot in World War I. WF showed a complete lack of stereoscopic vision, manifesting in an inability to estimate and recognize any spatial depth between visual stimuli. Besides his full depth perception loss, he showed additional neurovisual and neuropsychological impairments, e.g. bilateral homonymous scotomas in the lower quadrants, simultanagnosia and reduced visual working memory capacities. With regard to his binocular functions, WF displayed severe difficulties in “bringing [visual stimuli]

*Abbreviations:* FU, follow up; SD, standard deviation; Mdn, median; IQR, interquartile range

\* Corresponding authors at: Clinical Neuropsychology Unit & Neuropsychological Outpatient Service, Saarland University, Campus, Building A.1.3., 66123 Saarbruecken, Germany.

E-mail addresses: [annakatharina.schaadt@uni-saarland.de](mailto:annakatharina.schaadt@uni-saarland.de) (A.-K. Schaadt), [stephan.brandt@charite.de](mailto:stephan.brandt@charite.de) (S.A. Brandt), [antje.kraft@charite.de](mailto:antje.kraft@charite.de) (A. Kraft), [kerkhoff@mx.uni-saarland.de](mailto:kerkhoff@mx.uni-saarland.de) (G. Kerkhoff).

<http://dx.doi.org/10.1016/j.neuropsychologia.2015.01.029>

0028-3932/© 2015 Elsevier Ltd. All rights reserved.

into central vision [...] and in keeping his eyes fixed on a moving point” (Holmes and Horrax, 1919, p. 405), in the absence of any gross oculomotor impairments. This may be interpreted as a qualitative indication of difficulties in the initiation and maintenance of convergence eye movements (see above). Though repetitively examined over several months, WF’s condition remained remarkably stable, neither recovery nor slight improvements were reported.

A few similar cases since WF have been occasionally described in the last decades (see De Renzi, 1982 for review). All of these patients suffered from bilateral, mostly occipito-parietal lesions, usually resulting in homonymous visual field loss and deficits in simultaneous object detection (De Renzi, 1982; Gloning, 1965). Comorbid oculomotor impairments like gaze palsies or exotropia were occasionally reported, too (Michel et al., 1963; Gloning, 1965). A detailed and quantitative analysis of binocular visual capacities including an assessment of binocular fusion, stereopsis and visual depth estimation was however not conducted in the majority of reported patients. Thus, the identification of any “core deficit(s)” within the binocular vision network which may be responsible for the 3-D-vision loss is still missing. Unsurprisingly, little is known about recovery and nothing about potential treatments for this severe condition.

Here, we describe a unique patient (EH) that we studied over 2 years who showed an abrupt loss of visual depth perception after a unilateral right-sided stroke. We assessed several visual and binocular components potentially responsible for this condition and evaluated whether and to which extent this deficit could be modified by repetitive dichoptic training that is effective in less severe conditions of binocular vision impairment (Schaadt et al., 2014a, 2014b). Taken together, we argue that disturbed horizontal convergent fusion caused “flat vision” in patient EH and consequently may be the core deficit for this peculiar disorder.

## 2. Case description and Methods

Patient EH was a 56-year-old right-handed, successful lawyer with 18 years of education who had suffered from a right-sided parieto-occipital probably hypertensive hemorrhagic stroke 11 months before study entry. He had no history of neurological, ophthalmological or neuropsychological deficits prior to his stroke, in particular no squint. Neurovisual anamnesis revealed bilateral lower visual field loss and transient diplopia after enduring periods of binocular near space activity like reading or PC work. Particularly the latter prevented him from pursuing his regular vocation. However, as his most severe problem he described the complete loss of 3-D depth perception, subjectively manifesting in “flat vision”: All visual stimuli in 3-D-space appeared equidistant to him, “like coulisses with no information about the space between the objects” and their distance to him. Though EH was independent in basic daily activities (e.g. personal hygiene, dressing), he described plain difficulties in all visuomotor activities involving depth judgments, e.g. taking staircases or walking on uneven ground, grasping, perception of motion in depth, despite proper sensorimotor functions of the lower and upper limbs.

### 2.1. Magnetic resonance imaging (MRI) of brain lesion

EH underwent MRI 3 weeks after the hemorrhage. To screen for extra lesions and white matter lesions, distinct T1 and T2-weighted data sets (FLAIR; TR/TE 10000/90 ms, TI=2500 ms, FOV=165 × 220 mm<sup>2</sup>; 28 transversal slices; T2\*; TR/TE 700/15 ms, FOV=192 × 220 mm<sup>2</sup>; 28 transversal slices) were analyzed. There was no evidence for additional subcortical, cortical or white matter lesions.

**Table 1**  
Characteristics and affected areas of EH’s brain lesion.

Lesion size	20375 voxels
Automatic anatomical labeling (AAL)	Angular gyrus Calcarine Cuneus Middle occipital Precuneus Superior occipital
Brodmann areas (BA)	BA 7 BA 17 BA 18 BA 19 BA 31 BA 30 BA 39
Center of mass	X= 22, Y= -71, Z= 26

For lesion reconstruction we used a high-resolution T1 MR data set (MPRAGE; TR/TE 1300/3.5 ms, TI=650 ms, FOV=256 × 240 mm<sup>2</sup>; 176 sagittal slices). The data set was normalized with MATLAB (The MathWorks, Natick, MA, USA) and SPM8 software (Wellcome Trust Centre for Neuroimaging, University College London, UK) using Chris Rorden et al.’s Clinical Toolbox (<http://www.mccauslandcenter.sc.edu/CRNL/clinical-toolbox>).

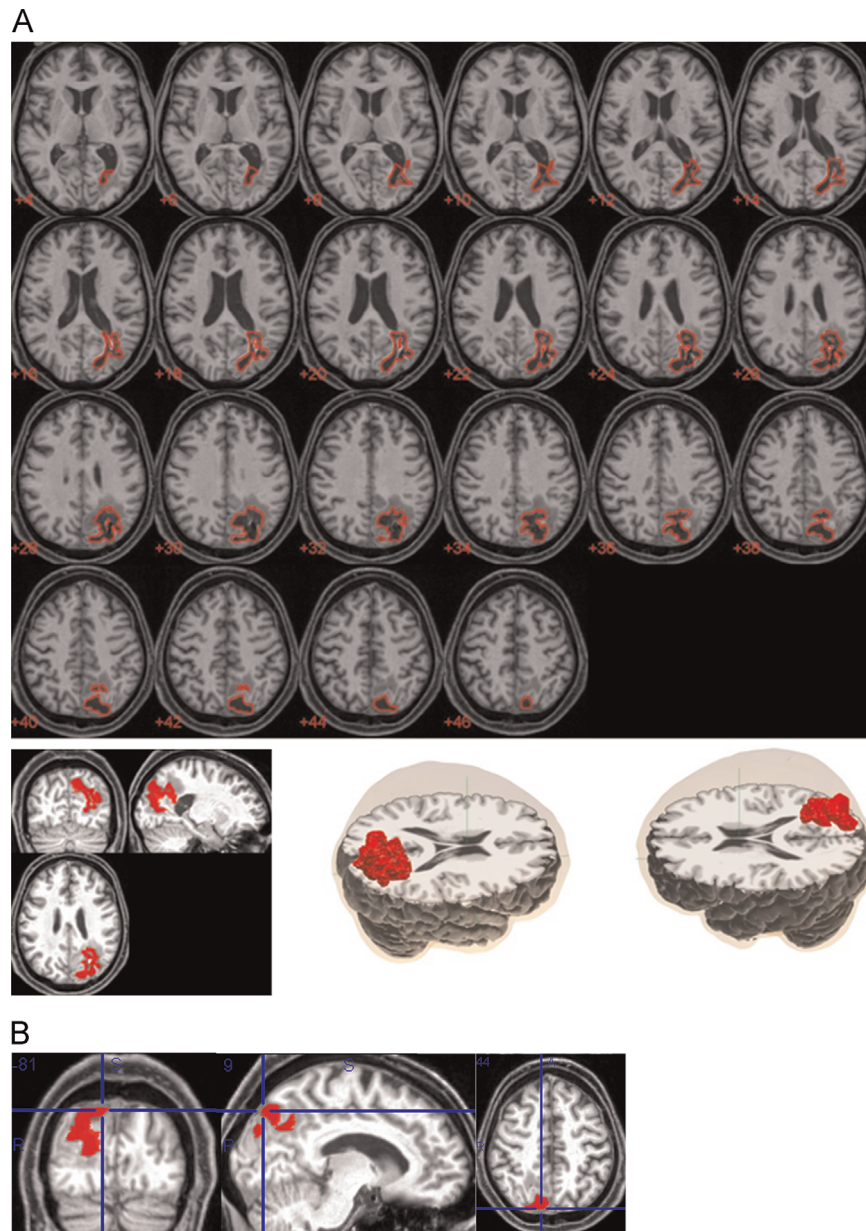
Two experienced raters (neurologist and psychologist) manually delineated the lesions to MRI images using MRICron software (<http://www.sph.sc.edu/comd/rorden/mricron/install.html>).

After normalization and lesion delineation, the lesion was registered to MNI space. This allows a standardized classification of which areas are affected in the patient brain using Automatic anatomical labeling toolbox (see Table 1 and Fig. 1). The lesion had an approximate volume of 20.38 cm<sup>3</sup>, and was centered around the grey and white matter of the right parieto-occipital sulcus (see Fig. 1). Here it affected the calcarine fissure, middle and superior occipital gyrus, the cuneus and precuneus (see Table 1 for Brodmann areas). Only the most rostral part of the angular gyrus was lesioned. Moreover, the white matter was affected and the lesion extended to the posterior horn of the lateral right ventricle.

### 2.2. Neuropsychological profile

EH had no visual neglect, as he did not show left- or right-sided omissions in a digit cancellation task nor a neglect-typical shift towards the right side in horizontal line bisection (Hesse et al., 2012; Machner et al., 2009; Reinhart et al., 2013; Kuhn et al., 2012; see Table 2, below). He also showed no abnormalities in figure copying (star, daisy, face), nor omissions in an indented reading test (180 words; see Table 2). Furthermore, neglect-associated behavioral symptoms in everyday life situations like dressing, washing or eating were negated by himself and his wife and were never observed by us during the 2 years of investigations.

EH did not show simultanagnosia, as he could simultaneously detect and name more than 6 visual objects in a 3-D topographical scenery (in a room or outside). He was also well able to recognize up to 5 geometric forms drawn over each other, in order to assess simultaneous visual perception (cf. Finke et al., 2007). He showed no motor (i.e. hemiparesis), nor somatosensory impairments. His speech was fluent and educated; he answered promptly and appropriately to questions, thus showed no signs of aphasia. His memory capacities were unimpaired by the stroke. He performed above average in all visual and verbal memory tests (see Table 2 below). This finding is also congruent with Kraft et al. (2014)



**Fig. 1.** (A) Top: Lesion delineation, Bottom-left: Center of mass, Bottom-middle and Bottom-right: 3D Lesion reconstruction. (B) Involvement of Area V6/V6A within the lesion boundaries (MNI coordinates based on [Pitzalis et al. \(2013\)](#)).

where memory deficits are associated with occipital-temporal lesions.

### 2.3. Neurovisual assessments

#### 2.3.1. Elementary visual functions

Detailed ophthalmologic and orthoptic examinations revealed neither abnormalities of the eyes nor oculomotor impairments. A clinical orthoptic examination showed normal saccadic and smooth pursuit eye-movements, however no apparatusive eye-movement recording was performed. Near (100%, 40 cm distance) and far visual acuity (125%, 5 m distance), spatial contrast sensitivity (1.25%, 1 m distance) and accommodation were unimpaired (3.5 dpts for both eyes; all tests from Visus GmbH, Stuttgart, Germany). Monocular visual perimetry (30°, Centerfield, Oculus, Wetzlar) showed left-sided homonymous scotomas particularly in the lower quadrant, compatible with the right-sided occipital-parietal lesion particularly affecting the upper part of the calcarine

sulcus (see [Fig. 2D](#)). Interestingly, there was an additional scotoma in the lower right quadrant in the perimetry of the right eye (see [Table 2](#), [Fig. 2D](#)). Visually evoked potentials (VEPs) revealed a slightly weaker peripheral P100 of the right anterior pathway as compared to the left eye, whereas central VEPs were normal in both eyes. As there were no signs or history of inflammatory optic nerve disease or prior arteritic infarctions of the anterior visual pathways, this antonymous field defect is most likely explained by acute nonarteritic ischemic optic neuropathy induced by intracranial pressure due to the large space-occupying hemorrhage ([Arnold, 2005](#)). On a binocular, i.e. functional level, visual campimetry (30°, Eyemove, MedCom, Munich) revealed scotomas in both the lower quadrants, representing the patient's reported bi-lateral inferior field loss.

#### 2.3.2. Binocular vision

We performed two tests that assessed foveal stereoacuity, but no tests of stereoscopic performance for visual field locations away

**Table 2**  
EH's assessment results at Baselines, Post-Test and Follow Up. Subjective binocular reading duration was defined as the time the patient could read binocularly without experiencing diplopia (see (Schaadt et al., 2014a, 2014b) for details).

Variable	BL1	BL 2	Post-Test	FU	Cutoff
Memory (Wechsler Memory Scale IV, 2012; verbal/spatial, percentile rank)		77/50	NA	NA	25 <sup>a</sup>
Reading (180 words; % correct)	100	100	NA	NA	98.89 <sup>b</sup>
Digit cancellation (Omissions L/R)	0/2	0/0	NA	NA	1 <sup>c</sup>
Line bisection 20 cm (% deviation horizontal/vertical)	16 <sup>d</sup> /0	0/0	NA	NA	5 <sup>c</sup>
Convergent horizontal fusional range (cm/m)	5.33	2.33	25	25	15 <sup>e,f</sup>
Subjective binocular reading duration (min.)	60	60	240	240	
Local Stereopsis (Titmus, arc seconds)	40	40	40	40	45 <sup>g</sup>
Global stereopsis (TNO, arc seconds)	120	120	120	60	90 <sup>g</sup>
Mean error in depth estimation (cm, % )	NO	7 (35)	1 (5)	1.8 (9)	
Near visual acuity (Letterchart, %)	100	NA	NA	125	100 <sup>h</sup>
Far visual acuity (Letterchart, %)	100	NA	NA	100	100 <sup>h</sup>
Contrast sensitivity (%)	1.25	NA	NA	1.25	1.5 <sup>i</sup>
Accommodation (dpts., L/R)	3.5/3.5	NA	NA	4/3.5	0.8/0.8 <sup>j</sup>
Visual perimetry (L/R, number of omissions, %)					
Left hemifield	11/12 (45.8/50)		11/12 (45.8/50)	8/9 (33.3/37.5)	0/0 <sup>h</sup>
Right hemifield	4/14 (16.7/58.3)		4/14 (16.7/58.3)	5/8 (20.8/33.3)	0/0 <sup>h</sup>

Abbreviations: dpts: diopters, L: left eye, R: right eye, NA: not further assessed because normal at Baseline 1 resp. 2, NO: not yet operationalized at Baseline 1. Digit cancellation: 20 digits (all number 5) have to be cancelled out on a 29.7 × 21 cm<sup>2</sup> white sheet of paper containing 200 single numerals from 0 to 9. Line bisection: 20 cm long × 1 cm wide black line on a 29.7 × 21 cm<sup>2</sup> white sheet of paper.

<sup>a</sup> Petermann and Lepach (2012).

<sup>b</sup> Kerkhoff et al. (2012).

<sup>c</sup> Kerkhoff (1999);

<sup>d</sup> EH showed a left-sided shift in horizontal line bisection of 16%.

<sup>e</sup> Schaadt et al. (2014a).

<sup>f</sup> Schaadt et al. (2014b).

<sup>g</sup> Momeni-Moghadam et al. (2011).

<sup>h</sup> Wall and Johnson (2005).

<sup>i</sup> Leat et al. (1999).

<sup>j</sup> Duane (1912).

from the fovea. EH showed normal local stereopsis (40°; Titmus-Test; Stereo Optical, Chicago) and close-to-normal global stereopsis (120°; TNO-Test; Lameris Ootech BV, Ede, Table 2). Consistent with his transient diplopia following binocular activities (after 60 min at latest, see “subjective reading time” in Table 2) he showed a severe reduction of binocular horizontal fusion, expressed as the convergent fusional range (Mean<sub>Baseline 1&2</sub> = 3.84 cm/m, lower cutoff in healthy controls: 15 cm/m, see Schaadt et al. (2014a, 2014b) for details). Convergent fusional range was measured with prisms (range=0–45 cm/m; Visus GmbH, Stuttgart): while both eyes gazed at a light point in 5 m distance (through a Bagolini glass), prisms of increasing diopters (horizontal, base out, in steps of 2 dpts) were positioned in front of the other eye (see Fig. 2A Prisms) in order to gradually increase the disparity of the monocular input. The value up to which both monocular images could be correctly fused, i.e. seeing one single light point for at least 5 s, is defined as convergent fusional range (expressed in cm/m, corresponding to prism diopter; 1 cm/m = 1 prism diopter = 0.5° of visual angle (Schaadt et al., 2014a, 2014b)). In sum, the convergent fusion measurement both includes an oculomotor component in terms of convergence eye movements induced by the prism and a sensory component, i.e. the merging of the monocular images into a cyclopean, binocular percept.

### 2.3.3. Visual depth perception during ego-motion

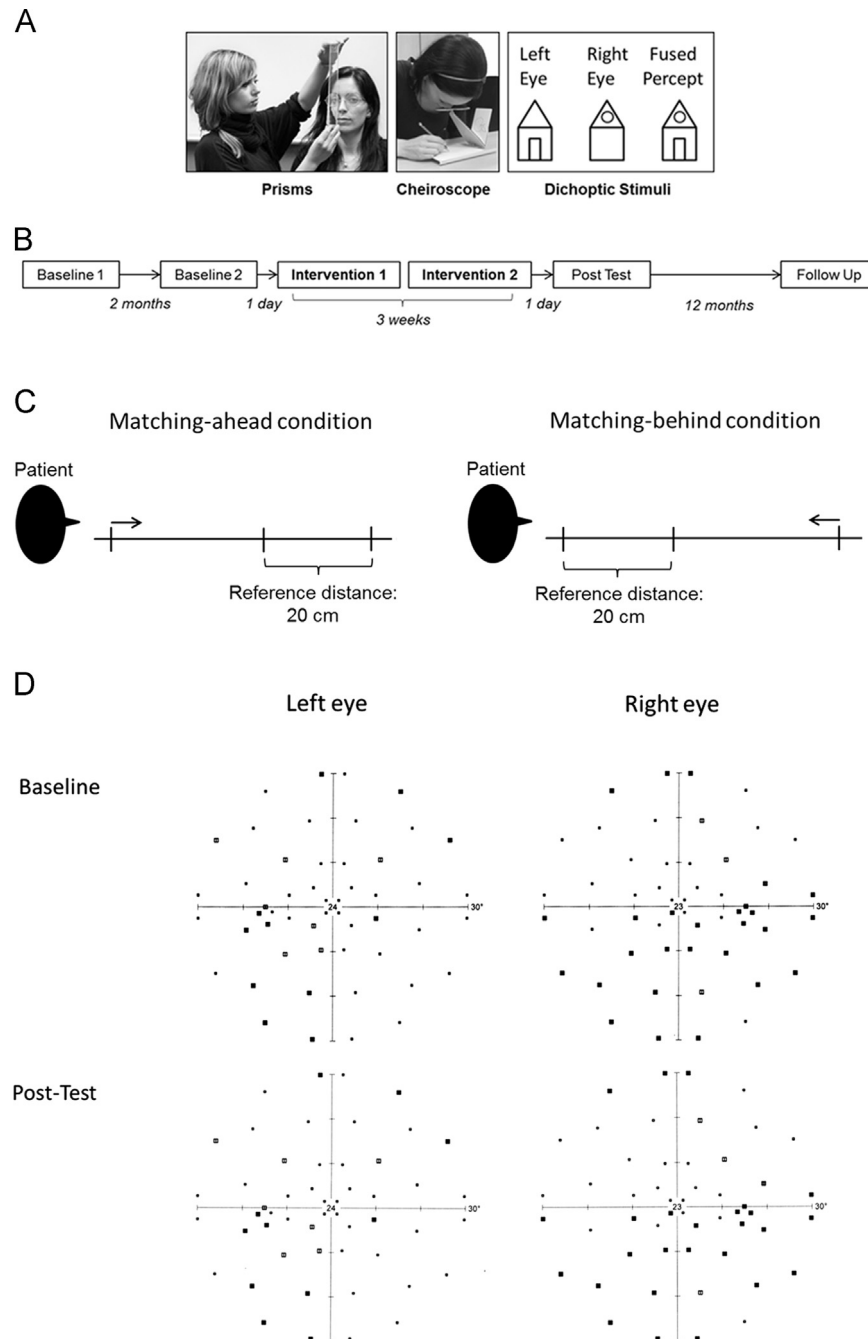
To evaluate the potential impact of motion on EH's subjective visual depth perception, we asked whether he experienced any impression of 3-D vision when moving forward in depth. Walking as a pedestrian, he described no stereo perception. In contrast, as an assistant driver in a car at a speed of approximately 50–60 km/h he experienced sensations of visual depth which he literally described as “pseudo-stereo”: while moving forward, the surrounding visual stimuli did not appear completely flat, instead evoking a slight sense of visual depth that however abruptly disappeared when the vehicle slowed down or stopped. On the other

hand, when velocities exceeded some 60 km/h, EH experienced no stereo-by-motion sensations but only blurred vision.

### 2.4. Experimental investigations

Besides his visual field loss, EH showed abnormalities in only one visual variable, i.e. convergent fusional range. In order to evaluate whether his impairment in binocular fusion was responsible for the loss of 3-D depth perception, we decided to treat the convergent fusional range subsequently in a single-subject baseline design. 3 Validated training devices – which have been proved to be quite effective in patients with less severe disturbances in binocular visual space perception (Schaadt et al., 2014a, 2014b) – were used: prisms of increasing diopters, a cheiroscope and dichoptic stimuli of ascending disparity angle (Fig. 2A). Details of these methods have been published elsewhere, (Schaadt et al., 2014a, 2014b), therefore only a short description is given here. Training with prisms of increasing diopters as described above started with an amplitude EH could just correctly fuse (2 cm/m). Prism size was subsequently increased when he was able to fuse both images for at least 2 min without diplopia. Practice with the dichoptic stimuli was conducted by displaying each eye two slightly different images of increasing horizontal disparity (0–12°), which again had to be fused by EH for at least 2 min. Using the cheiroscope, with the left eye, one perceives a line drawing, with the right eye a blank sheet of paper. When both monocular images can be fused, the subject is able to see the line drawing on the blank sheet of the paper. Consequently, the projected picture can be copied on the paper sheet by retracing the lines. Put differently: The better the patient fuses both images (picture on left side/eye and own drawing on right side/eye), the more exact (“fused”) the copy appears.

EH was trained in a single-subject design with two Baseline assessments (within 2 months), a 3-week training period, a Post-Test one day after and a Follow Up (FU) one year after the end of



**Fig. 2.** (A) Training methods (see Schaadt et al. (2014a, 2014b) for details). (B) Training design. (C) Distance-in-depth matching task. The patient had to estimate the distance ahead (left) and behind (right) a 20 cm reference distance. (D) Monocular visual perimetry before and after dichoptic treatment.

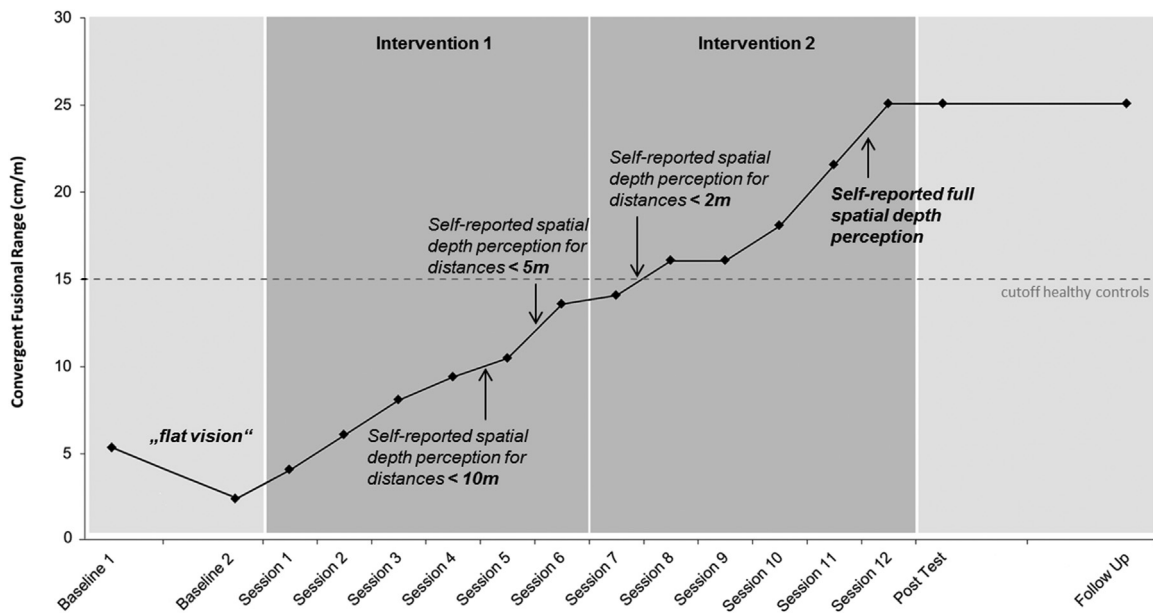
training (Fig. 2B). As depth perception first reoccurred in the far distance (5–10 m, see below), EH was trained in two consecutive interventions: in Intervention 1 (sessions 1–6) he received prism training in 5 m distance, in Intervention 2 distances were varied between 5 m, 2 m and 1 m with the aim of improving depth perception in near space. EH received 1–2 sessions a day (each 1 h), but did not receive any other treatment except saccadic training for his field loss (Kerkhoff, 1999) 1 h per day from Baseline 1 to Post-Test.

To operationalize the deficit in visual depth perception in greater detail, a distance-in-depth matching task was designed: EH sat at a distance of 60 cm from the center of a metal bar pointing away from him, with his head fixed centrally in a head-and chin-rest, to avoid head movements. By adjusting a mark, EH

had to match the interspace ahead and behind a 20 cm, fixed reference-distance, which was again displayed by 2 marks (Fig. 2C). 3 trials were performed ahead and behind the pre-set reference distance. For statistical analysis the mean of these six trials was calculated, as there was no difference between the matching-ahead vs. the matching-behind condition. At baseline, EH averagedly misjudged the distances about 7 cm (in relation to the 20 cm target distance).

### 3. Results

Convergent fusional range improved continuously during both experimental interventions up to a normal level (25 cm/m). One



**Fig. 3.** Development of convergent fusional range and reported subjective binocular spatial depth perception during baselines/training/Follow Up. The grey dotted line shows the lower cutoff of the convergent horizontal fusional range in healthy controls (Schaadt et al., 2014a, 2014b).

sample *t*-Tests against a fixed value revealed significant ( $p < .05$ ) changes between averaged baseline (fixed value: 3.84 cm/m) and Intervention 1 (Mean<sub>Intervention1</sub> = 8.54 cm/m, SD = 3.35;  $t(5) = 3.441$ ,  $p = .018$ ,  $d = 1.4$ ), Intervention 2 and Post-Test, respectively (fixed value: 25 cm/m; Mean<sub>Intervention2</sub> = 18.42 cm/m, SD = 4.10;  $t(5) = -3.929$ ,  $p = .011$ ,  $d = -1.6$ ). Wilcoxon signed-rank tests showed significant differences in fusional range (Mdn<sub>Intervention1</sub> = 8.67, IQR<sub>Intervention1</sub> = 5.68; Mdn<sub>Intervention2</sub> = 17, IQR<sub>Intervention2</sub> = 7.88) between both interventions ( $z = -2.207$ ,  $p = .031$ ;  $r = -0.64$ ; Fig. 3). Along with binocular fusion, reading duration increased 4-foldly from baseline to Post-Test/FU (Table 2).

After Session 4, EH reported a gradual reinstatement of depth perception, first in far distances (5–10 m; Intervention 1), then in the near (< 2–5 m; Intervention 2), with a full recovery after session 11 which remained stable at 1-year-FU (Fig. 3). In the distance-in-depth matching task, he improved from a mean misjudgment error of 7 cm (35%) at baseline to 1 cm (5%, Post-Test) respectively 1.87 cm (9%, FU; Table 2). Interestingly, local and global stereopsis remained completely unchanged throughout the training, while the latter slightly improved at FU (from 120° to 60°; Table 2). Visual field defects were stable at Post-Test and slightly improved at FU. Visual acuity, contrast sensitivity and accommodation remained unchanged until FU (Table 2).

## 4. Discussion

Patient EH suffered from a complete loss of binocular depth perception after a purely unilateral right-sided occipito-parietal stroke. Detailed assessment of visual functions revealed visual field loss in both the lower quadrants and severe disturbances in binocular fusion, in the absence of any further neurovisual or neuropsychological dysfunction. After 3 weeks of repetitive dichoptic training applied to improve convergent fusional range, he showed, besides a normalization of binocular fusion, a full and stable restoration of visual depth perception.

The following findings are apparent from this study: (i) flat vision may result from impaired binocular horizontal fusion, and (ii) this deficit can be fully reversed by specific neurovisual treatments. We will discuss these findings in detail below.

### 4.1. Causes of flat vision

#### 4.1.1. Functional causes

Contrary to Holmes and Horrax (1919) very thoroughly examined case WF, EH did not show any deficits in the simultaneous perception of visual stimuli, ruling out simultanagnosia as a primary cause for “flat vision” in EH. Concerning lesion location, all reported cases on flat vision showed bilateral lesions of differential etiological origin, mostly affecting occipito-parietal regions (De Renzi, 1982), whereas EH suffered from unilateral, i.e. right-sided stroke, weakening any suggestions on the necessity of bilateral brain damage on areas potentially devoted to spatial depth perception.

What appears to be yet, at least functionally, *bilateral* in EH’s case is his lower visual field loss. Comparing EH to Holmes and Horax’s patient WF as well as to the other available case studies (De Renzi, 1982; Gloning, 1965), the parallel between bilateral inferior visual field loss and “flat vision” is appealing. But importantly, EH’s depth perception loss was clearly attributable to a severely impaired convergent fusional range while his visual field loss remained unchanged during the reinstatement of depth perception. Whether such visual field loss is a necessary prerequisite or only a frequently – due to lesion proximity – associated phenomenon in “flat vision” remains to be clarified in future investigations.

In all previously described cases (Holmes and Horrax, 1919; De Renzi, 1982; Gloning, 1965), binocular fusion was not comparably assessed or most likely impaired due to severe oculomotor impairments evident in some cases (Michel et al., 1963; Gloning, 1965). Though, in WF convergence insufficiency was qualitatively reported (Holmes and Horrax, 1919; see Introduction). As proper convergence eye movements are an essential component of binocular fusion (Skelton and Kertesz, 1991), fusional dysfunction may be a likely – but completely speculative – explanation for WF’s loss of stereoscopic vision, too.

#### 4.1.2. Neuroanatomical causes

In the literature disorders in depth perception have been associated with lesions of Brodmann areas BA7/19/39, which were all affected in patient EH (Ffytche et al., 2010). However, deficits in

depth perception have also been discussed to be ascribed to lesions of U-shaped fibers and the splenium (Ffytche et al., 2010; Danta et al., 1978; Mitchell and Blakemore, 1970). Note that patient EH showed lesion of white matter tracts and the lesion extended to the ventricle. Thus, it is possible that fibers connecting the hemisphere were lesioned and that disconnection between the hemispheres caused the deficit.<sup>1</sup>

However, this explanation cannot fully account for the selective dependency of EH's visual depth perception on his convergent fusional range. On a functional level, the treatment-induced improvement of binocular fusion was directly associated with an improvement in 3-D perception. Consequently, the neural basis of visual depth perception, if there is one, has to include brain regions involved in disparity coding in order to integrate the binocular coordinates into a refined 3-D spatial percept. A promising candidate for this claim seems to be the homolog area V6/V6A in the medial occipito-parietal cortex, which was affected in EH (Fig. 1B; Pitzalis et al., 2013). As revealed in animal and human functional neuroimaging studies, V6/V6A plays an important role in the analysis of spatial locations of visual stimuli and the encoding of gaze positions in visual 3-D space (Galletti et al., 1995; Fattori et al., 2009). Interestingly, the majority of V6/V6A neurons fires selectively during prolonged fixation periods based on sustained vergence eye positions, whereas initial, i.e. transient vergence eye movements are less encoded in this brain region (Breveglieri et al., 2012). As sustained vergence is essential to binocular convergent fusion (see Introduction), the putative involvement of Area V6/V6A in EH's brain lesion provides a neuroanatomical connection between binocular fusion and real 3-D vision. In addition, several other dorsal visual areas have been shown to be involved in vergence-based disparity coding, including MIP (Bhattacharyya et al., 2009) and the posterior-parietal area 7A (Sakata et al., 1980), which however were not affected by the lesion (Rushworth et al., 2001; Heim et al., 2012).

#### 4.2. Plasticity in binocular visual space perception

Most remarkably and in contrast to the other reported cases, EH's objective stereoscopic depth perception and his subjective feeling of space ("flat vision") could be normalized by repetitive, step-wise dichoptic training of binocular convergent fusion and stereo disparity. Interestingly, EH's subjective depth perception recovered in a gradient-like manner after fusion training in different distances (far, near). His recovery was paralleled by improved distance-in-depth judgments. Though previous studies showed close links between fusion and stereopsis (Schaadt et al., 2014a, 2014b), EH's stereopsis was nearly completely preserved and did not change during the training, indicating that "flat vision" does not necessarily result from astereopsis (Rizzo, 1989), but can solely be caused by insufficient binocular fusion.

## 5. Conclusion

Impaired convergent horizontal fusion may cause a total loss of 3-D vision ("flat vision") and training of fusion may completely normalize this disorder. This distinct involvement of binocular fusion in 3-D vision indicates a crucial dependency of higher cortical areas devoted to visual space perception on pathology- and training-induced modifications in earlier visual processing stages. This view is supported by animal studies revealing a high

specificity and elaborated connectivity of the neural components underlying visual depth processing (Chowdhury and DeAngelis, 2008).

## Funding source

Georg Kerkhoff receives funding from the Deutsche Forschungsgemeinschaft (DFG) (Grant no. IRTG 1457), International Research Training Group IRTG 1457 Adaptive Minds.

## Conflict of interest

The authors declare no conflict of interest.

## References

- Alkan, Y., Biswal, B.B., Alvarez, T.L., 2011. Differentiation between vergence and saccadic functional activity within the human frontal eye fields and midbrain revealed through fMRI. *PLoS One* 6, e25866.
- Anzai, A., DeAngelis, G.C., 2010. Neural computations underlying depth perception. *Curr. Opin. Neurobiol.* 20, 367–375. <http://dx.doi.org/10.1016/j.conb.2010.04.006>.
- Arnold, A.C., 2005. Ischemic optic neuropathy. 6th edition In: Miller, N.R., Newman, N.J., Biousse, V., Kerrison, J.B. (Eds.), *Walsh & Hoyt's Clinical Neuro-Ophthalmology, vol. I*. Lippincott Williams & Wilkins, Philadelphia, pp. 349–384.
- Bhattacharyya, R., Musallam, S., Andersen, R.A., 2009. Parietal reach region encodes reach depth using retinal disparity and vergence angle signals. *J. Neurophysiol.* 102 (2), 805–816. <http://dx.doi.org/10.1152/jn.90359.2008>.
- Breveglieri, R., Hadjimitsakis, K., Bosco, A., Sabatini, S.P., Galletti, C., Fattori, P., 2012. Eye position encoding in three-dimensional space: integration of version and vergence signals in the medial posterior parietal cortex. *J. Neurosci.* 32 (1), 159–169. <http://dx.doi.org/10.1523/JNEUROSCI.4028-11.2012>.
- Chowdhury, S.A., DeAngelis, G.C., 2008. Fine discrimination training alters the causal contribution of macaque area MT to depth perception. *Neuron* 60, 367–377. <http://dx.doi.org/10.1016/j.neuron.2008.08.023>.
- Danta, G., Hilton, R.C., O'Boyle, D.J., 1978. Hemisphere function and binocular depth perception. *Brain* 101, 569–589.
- De Renzi, E., 1982. Spatial perception and its deficits. In: De Renzi, E. (Ed.), *Disorders of Space Exploration and Cognition*. John Wiley & Sons, Chichester, pp. 138–171.
- Duane, A., 1912. Normal values of the accommodation at all ages. *J. American Med. Assoc.* 59 (12), 1010–1013.
- Fattori, P., Pitzalis, S., Galletti, C., 2009. The cortical visual area V6 in macaque and human brains. *J. Physiol.* 103 (1), 88–97. <http://dx.doi.org/10.1016/j.jphysparis.2009.05.012>.
- Ffytche, D.H., Blom, J.D., Catani, M., 2010. Disorders of visual perception. *J. Neurol., Neurosurg. Psychiatry* 81 (11), 1280–1287. <http://dx.doi.org/10.1136/jnnp.2008.171348>.
- Finke, K., Schneider, W.X., Redel, P., Dose, M., Kerkhoff, G., Müller, H.J., Bublak, P., 2007. The capacity of attention and simultaneous perception of objects: a group study of Huntington's disease patients. *Neuropsychologia* 45 (14), 3272–3284. <http://dx.doi.org/10.1016/j.neuropsychologia.2007.06.006>.
- Galletti, C., Battaglini, P.P., Fattori, P., 1995. Eye position influence on the parieto-occipital prea PO (V6) of the Macaque monkey. *Eur. J. Neurosci.* 7 (12), 2486–2501. <http://dx.doi.org/10.1111/j.1460-9568.1995.tb01047>.
- Gillebert, C.R., Humphreys, G.W., Mantini, D., 2014. Automated delineation of stroke lesions using brain CT images. *NeuroImage: Clin.* 4, 540–548. <http://dx.doi.org/10.1016/j.nicl.2014.03.009>.
- Gloning, K., 1965. *Die cerebralen bedingten Störungen des räumlichen Sehens und des Raumerlebens*. W. Maudrich Verlag, Wien.
- Hart, C., 1969. Disturbances of fusion following head injury. *Proc. R. Soc. Med.* 62, 704–706.
- Heim, S., Amunts, K., Hensel, T., Grande, M., Huber, W., Binkofski, F., Eickhoff, S.B., 2012. The role of human parietal area 7A as a link between sequencing in hand actions and in overt speech production. *Front. Psychol.* 3. <http://dx.doi.org/10.3389/fpsyg.2012.00534>.
- Hesse, C., Lane, A.R., Aimola, L., Schenk, T., 2012. Pathways involved in human conscious vision contribute to obstacle-avoidance behaviour. *Eur. J. Neurosci.* 36 (3), 2383–2390. <http://dx.doi.org/10.1111/j.1460-9568.2012.08131.x>.
- Holmes, G., Horrax, G., 1919. Disturbances of spatial orientation and visual attention, with loss of stereoscopic vision. *Arch. Neurol. Psychiatry* 1, 384–407.
- Kerkhoff, G., 1999. Restorative and compensatory therapy approaches in cerebral blindness—a review. *Restor. Neurol. Neurosci.* 15, 255–271. [http://dx.doi.org/10.1016/S0028-3932\(99\)00140-2](http://dx.doi.org/10.1016/S0028-3932(99)00140-2).
- Kerkhoff, G., Wimbauer, K., Reinhart, S., 2012. Saarbrücker Lesetexte. From: (<http://www.uni-saarland.de/lehrstuhl/kerkhoff/downloads-siagnostiktherapie/materi-ali-en-fuer-diagnostiktherapie.html>) (retrieved 3.09.14).
- Kraft, A., Grimsen, C., Kehler, S., Bahnmann, M., Spang, K., Prass, M., Brandt, S.A.,

<sup>1</sup> We used a manual delineation approach in the current study. Note that recent studies point out that manual delineation does not detect stroke-induced degeneration that takes place outside the lesion and there is no clear cutoff between lesion and non-lesioned parts of the brain (Gillebert et al. 2014).

2014. Neurological and neuropsychological characteristics of occipital, occipitotemporal and occipito-parietal infarction. *Cortex: J. Devoted Study Nerv. Syst. Behav.* 56, 38–50. <http://dx.doi.org/10.1016/j.cortex.2012.10.004>.
- Kuhn, C., Bublak, P., Jobst, U., Rosenthal, A., Reinhart, S., Kerkhoff, G., 2012. Contralateral spatial bias in chronic hemianopia: the role of (ec)centric fixation, spatial cueing and visual search. *Neuroscience* 210, 118–127. <http://dx.doi.org/10.1016/j.neuroscience.2012.03.020>.
- Leat, S.J., Legge, G.E., Bullimore, M.A., 1999. What is low vision? A re-evaluation of definitions. *Optom. Vis. Sci.* 76 (4), 198–211.
- Machner, B., Sprenger, A., Hansen, U., Heide, W., Helmchen, C., 2009. Acute hemianopic patients do not show a contralesional deviation in the line bisection task. *J. Neurol.* 256 (2), 289–290. <http://dx.doi.org/10.1007/s00415-009-0148-3>.
- Michel, F., Jeannerod, M., Devic, M., 1963. A case of visual orientation disorder in the 3 dimensions of space. (Apropos of Balint's syndrome and the syndrome described by G. Holmes). *Cortex* 1 (4), 441–466.
- Mitchell, D.E., Blakemore, C., 1970. Binocular depth perception and the corpus callosum. *Vis. Res.* 10, 49–54.
- Momeni-Moghadam, H., Kundart, J., Ehsani, M., Gholami, K., 2011. The comparison of stereopsis with TNO and Titmus Tests in symptomatic and asymptomatic university students. *J. Behav. Optom.* 23, 2.
- Petermann, F., Lepach, A.C., 2012. Wechsler Memory Scale. Fourth Edition, German Edition. Manual. Pearson Assessment, Frankfurt.
- Pitzalis, S., Sdoia, S., Bultrini, A., Committeri, G., Di Russo, F., Fattori, P., Galati, G., 2013. Selectivity to translational egomotion in human brain motion areas. *PLoS One* 8 (4), e60241. <http://dx.doi.org/10.1371/journal.pone.0060241>.
- Reinhart, S., Wagner, P., Schulz, A., Keller, I., Kerkhoff, G., 2013. Line bisection error predicts the presence and severity of neglect dyslexia in paragraph reading. *Neuropsychologia* 51, 1–7. <http://dx.doi.org/10.1016/j.neuropsychologia.2012.10.026>.
- Rizzo, M., 1989. Astereopsis. In: Boller, F., Grafman, J. (Eds.), *Handbook of Neuropsychology*. Elsevier, Amsterdam, pp. 415–427.
- Rushworth, M.F., Paus, T., Sipila, P.K., 2001. Attention systems and the organization of the human parietal cortex. *J. Neurosci.* 21 (14), 5262–5271.
- Sakata, H.I.D.E., Shibutani, H., Kawano, K.E.N.J.I., 1980. Spatial properties of visual fixation neurons in posterior parietal association cortex of the monkey. *J. Neurophysiol.* 43 (6), 1654–1672.
- Schaadt, A.K., Schmidt, L., Kuhn, C., Summ, M., Adams, M., Garbacenkaite, R., et al., 2014a. Perceptual relearning of binocular fusion after hypoxic brain damage: four controlled single-case treatment studies. *Neuropsychology* 28, 382–387. <http://dx.doi.org/10.1037/neu0000019>.
- Schaadt, A.K., Schmidt, L., Reinhart, S., Adams, M., Garbacenkaite, R., Leonhardt, E., et al., 2014b. Perceptual relearning of binocular fusion and stereoacuity after brain injury. *Neurorehabil. Neural Repair* 28, 462–471. <http://dx.doi.org/10.1177/1545968313516870>.
- Skelton, B.J., Kertesz, A.E., 1991. Sensory interactions during human fusional response. *Vis. Res.* 31, 1573–1587.
- Wall, M., Johnson, C.A., 2005. Principles and techniques of the examination of the visual sensory system. 6th. edition In: Miller, N.R., Newman, N.J., Biousse, V., Kerrison, J.B. (Eds.), *Walsh & Hoyt's Clinical Neuro-Ophthalmology*, vol. 1. Lippincott Williams & Wilkins, Philadelphia, pp. 83–149.