

## CASE REPORT

# A case of cortical deafness and loss of vestibular and somatosensory sensations caused by cerebrovascular lesions in bilateral primary auditory cortices, auditory radiations, and postcentral gyruses – complete loss of hearing despite normal DPOAE and ABR

KIMITAKA KAGA<sup>1,2</sup>, YUKIKO SHINJO<sup>1</sup>, CHIEKO ENOMOTO<sup>1</sup> & MITSUKO SHINDO<sup>1</sup>

<sup>1</sup>National Institute of Sensory Organs, National Tokyo Medical Center, Tokyo, Japan and <sup>2</sup>Center for Speech and Hearing Disorders, International University of Health and Welfare, Tochigi, Japan

## Abstract

**Conclusion:** A right-handed 38-year-old man's complete loss of hearing could be diagnosed as cortical deafness caused by cerebral vascular lesions in bilateral auditory cortices. **Objective:** The aim of this case report was to study the pathophysiology of a particular patient who manifested deafness without residual hearing and lost somatosensory sensation, vestibular sensation, and articulation ability after a right internal carotid-posterior communicating artery (IC-PC) aneurysm and subarachnoid hemorrhage. **Methods:** MRI, aphasia and neurological tests, subjective and objective audiometry, and vestibular function tests were performed. **Results:** The neurological test revealed system loss of somatosensory sensation with normal motor function and articulation ability. Brain imaging revealed extensive infarction in the bilateral primary auditory cortices, postcentral gyruses, and the bilateral partial third frontal gyruses. Pure-tone audiometry of both ears revealed off-the-scale results and speech audiometry demonstrated 0% maximum speech discrimination. However, objective audiometry showed normal distortion product otoacoustic emissions (DPOAE) and normal auditory brainstem response (ABR). The patient showed 0% perception of environmental, speech, and music sounds in both ears. He was unable to feel vestibular sensation despite normal caloric nystagmus. He showed no damage to his larynx or articulation organs.

**Keywords:** *anarthria, auditory agnosia, objective audiometry, speech audiometry, vestibular function test*

## Introduction

There has been a dispute about the difference in residual hearing between cortical deafness and auditory agnosia [1]. Cortical deafness and auditory agnosia have been reported as auditory imperception mostly caused by damage of bilateral primary auditory cortices or auditory radiation following cerebrovascular accidents despite normal distortion product otoacoustic emissions (DPOAE) and auditory brainstem response (ABR). Most patients with such damage have residual hearing with moderate or severe threshold elevation, as determined by pure-tone audiometry, but show imperception of speech sounds, as determined

by speech audiometry [2–4]. However, it is very rare to encounter patients with cortical deafness who completely lose hearing in both ears [5–7]. We report a case of a patient who completely lost his auditory, vestibular, and somatosensory sensations and articulation ability after a cerebrovascular accident.

## Case report

The chief complaint was loss of hearing of both ears and loss of somatosensory sensation and articulation ability.

The patient was a right-handed 38-year-old man. He worked as an IT engineer for a company in Tokyo

Correspondence: Kimitaka Kaga MD PhD, National Institute of Sensory Organs, National Tokyo Medical Center, 2-5-1 Higashigaoka, Meguro-Ku, Tokyo 152-8902, Japan. Tel: +81 3 3411 0111 Fax: +81 3 3411 0185. E-mail: kimikaga-tyk@umin.ac.jp

(Received 2 September 2014; accepted 9 October 2014)

ISSN 0001-6489 print/ISSN 1651-2251 online © 2015 Informa Healthcare  
DOI: 10.3109/00016489.2014.980914

1. Temperature sensation	Lost
2. Pain sensation	Lost
3. Touch sensation	Lost
4. Vibration sensation	Lost




Figure 1. Somatosensory tests. The patient cannot feel temperature, pain, touch or vibration.

without any speech, hearing or motor disorders before the cerebrovascular accident.

In 2007, he experienced rupture of a right internal carotid-posterior communicating artery (IC-PC) aneurysm and subarachnoidal hemorrhage, and subsequently lost his hearing, somatosensory sensation, and articulation ability. Because he complained of profound hearing loss, he was referred to us by a rehabilitation hospital in 2012 for further auditory study.

Before he was referred to us, he underwent rehabilitation for motor dysfunction in the rehabilitation hospital for 1 year and he recovered his motor function completely. However, he did not recover his loss of hearing, somatosensory sensation, and articulation ability at all. Nevertheless, his activities of daily living (ADLs) were satisfactory and he visited us alone. He presently lives alone and works in the same company.

#### Neurological test

A neurological test revealed systematic loss of somatosensory sensation of temperature, pain, touch, and vibration (Figure 1) with normal motor function. An intellectual function test revealed a PCRM score of 30/30. A memory test showed only mild visual memory impairment. The standard aphasia test (Table I) revealed normal reading and writing abilities. However, he showed complete loss of auditory perception and speaking ability but preserved inner speech.

#### Brain imaging

Brain imaging examination showed extensive infarction of the primary auditory cortices and auditory radiation (Figure 2) and localized infarction of the bilateral postcentral gyri and the partial third frontal gyri.

#### Audiological tests

Pure-tone audiometry of both ears revealed off-the-scale results and speech audiometry demonstrated 0% maximum speech discrimination in both ears. The environmental sound test revealed no perception even with picture matching (Figure 3). However, the objective audiometry showed normal DPOAE in both ears and normal ABR in terms of wave configuration and thresholds of 20 dB in both ears (Figure 4).

Table I. Standard aphasia test, Japanese version.

	Category	Items	Percent correct
I	Hearing	1. Word	0
		2. Short sentence	0
		3. Auditory order	0
		4. Monosyllable	0
II	Speaking	5. Naming	0
		6. Word repeats	0
		7. Explanation of behaviors	0
		8. Explanation of cartoon	0
		9. Sentence repeats	0
		10. Word saying	0
		11. Reading aloud words	0
		12. Reading aloud monosyllables	0
		13. Reading aloud words	0
		14. Reading aloud sentences	0
II	Reading	15. Kanji words	100
		16. Kana words	100
		17. Short sentences	100
		18. Order by writing	100
IV	Writing	19. Words	100
		20. Monosyllables	100
		21. Explanation of cartoon	100
		22. Dictation of monosyllables	0
		23. Dictation of kanji words	0
		24. Dictation of short sentences	0
V	Calculation	25. Simple calculation	85

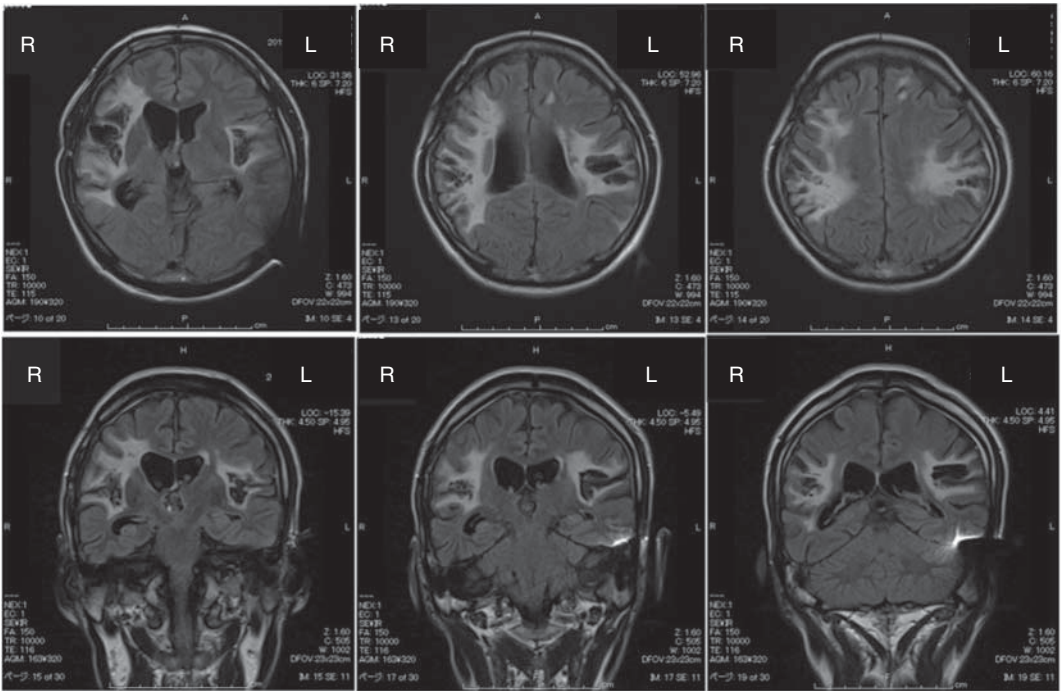


Figure 2. Brain imaging by MRI shows cerebrovascular lesions in bilateral regions. Flair images reveal lesions in bilateral auditory cortices, radiations, and postcentral gyri and the partial damage of the third frontal gyri.

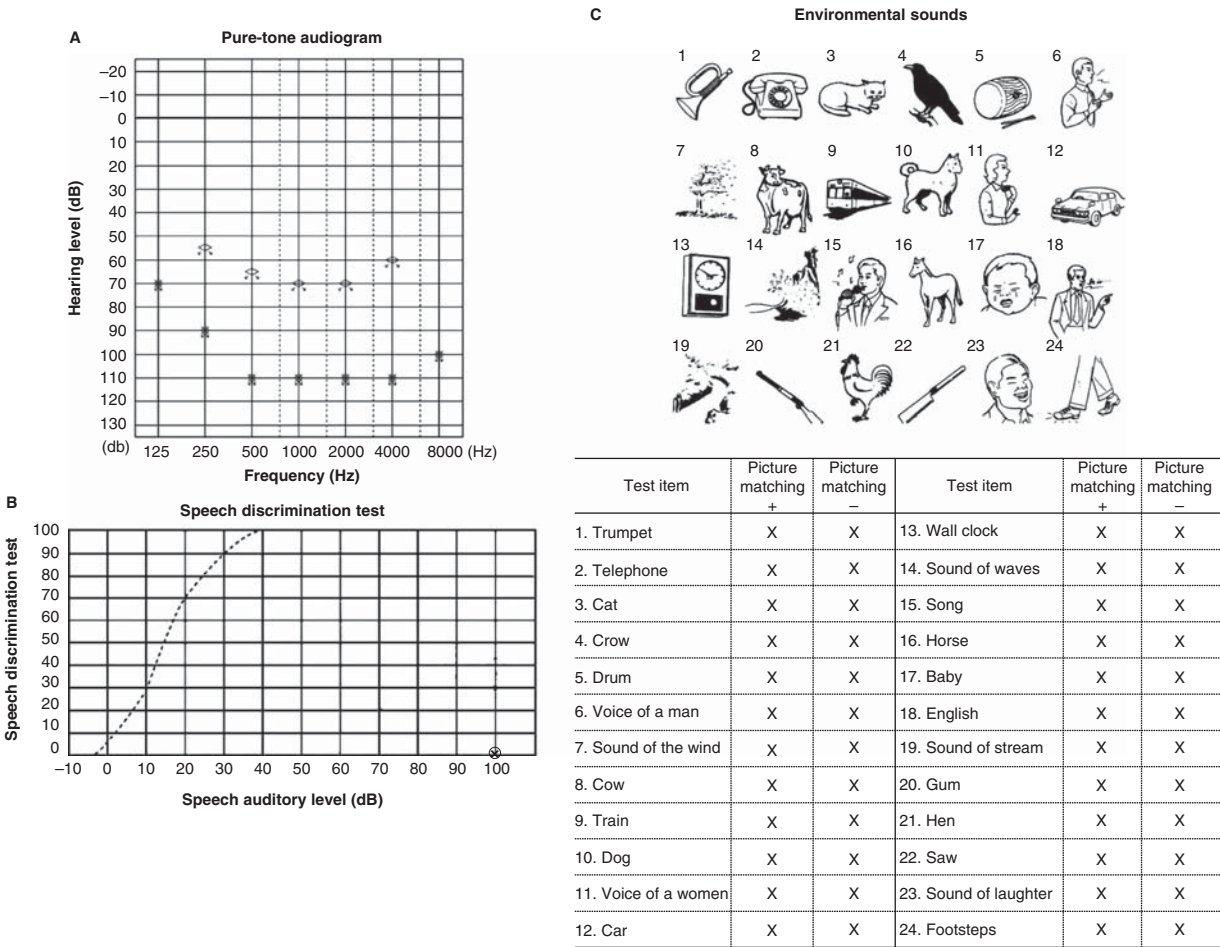


Figure 3. Audiological tests. (A) Pure-tone audiometry, (B) speech audiometry, (C) environment sound test. All audiological tests reveal no hearing

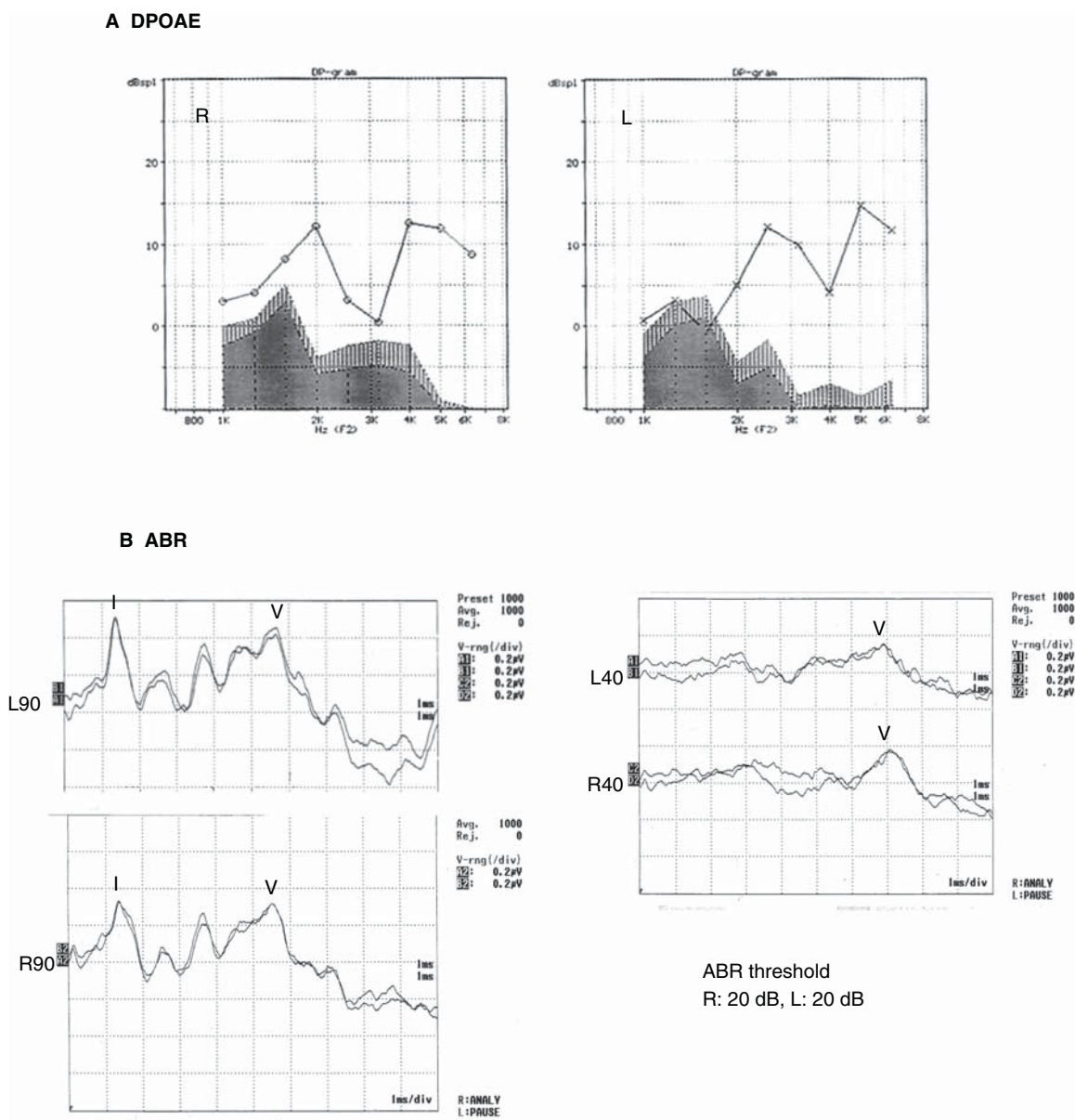


Figure 4. Objective audiological test. (A) Distortion product otoacoustic emissions (DPOAE), (B) auditory brain response (ABR). Both DPOAE and ABR are normal.

### Vestibular function test

The caloric test results were normal for both ears and the rotational chair test showed normal nystagmus by clockwise and counterclockwise rotations. However, the patient cannot feel vestibular sensation at all (Figure 5).

### Voice and articulation

He showed no damage to his larynx or articulation organs. However, he lost his articulation ability and was only able to produce meaningless sounds.

### Communication

He underwent training for lip-reading, but he was unable to acquire the skill. Therefore, he communicated by writing.

### ADLs

His ADLs without hearing and somatosensory sensation are summarized in Table II.

He uses a light-integrated clock to wake up. For his bath, temperature is carefully adjusted using a thermometer. He communicates with others by writing,



**A Caloric test**

5°C, 5 ml  
Normal reaction in both ears

**B Damped rotational chair test**

Normal reaction to right and left rotation

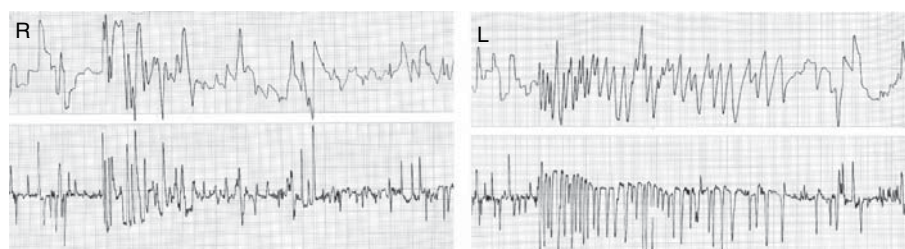


Figure 5. Vestibular examination. (A) Caloric test elicited normal nystagmus reaction. (B) Damped rotational chair test. Normal rotation nystagmus was elicited. The patient did not feel vestibular sensation at all.

Table II. Activities of daily living (ADLs) of the patient without hearing and somatosensory sensation.

ADL	Status
Paper handling	He is not able to count the number of papers. When he needs to count money, he asks for help from a staff member in a bank
Hot water	He is not able to feel the shower on his skin and he cannot discriminate between hot and cold water
Earthquake	He cannot feel the vibration of tuning fork, earthquake or motion sickness
Wake up in the morning	He wakes up using an alarm light instead of an alarm clock
Loneliness	In his daily life, he feels lonely because of complete loss of hearing and touch sensation. He enjoys drinking alcoholic drinks (particularly bourbon whisky) and eating his favorite food (sushi)
Shake hands	His shaking hand is very powerful because he cannot control the strength due to the loss of touch sensation
Voice	His voice is very loud but he cannot produce meaningful articulation
Lip-reading	Although he underwent training for lip-reading with a speech pathologist, his learning was very slow and his lip-reading skill was poor
Communication by writing	He communicates by writing. He proposes the use of easy erase boards when communicating with others

The patient loses sensations of temperature, pain, touch, and vibration.

using two erase boards, one for himself and the other for the person he is communicating with.

## Discussion

On the basis of the above-mentioned clinical data, we made the neuropsychological diagnosis of cortical deafness, loss of vestibular and somatosensory sensations, and anarthria.

In our previous studies, we reported audiological findings of patients with auditory agnosia following bilateral auditory cerebrovascular accidents [1,3,4]. These studies revealed moderate preservation of pure-tone hearing and the ability to perceive environmental sounds, similar to the study by Lherrnitte et al. [2].

However, the patient in this case report completely lost his hearing in both ears (despite having normal DPOAE and ABR) and lost vestibular and somatosensory sensations. The loss of hearing and vestibular and somatosensory sensations could be caused by the complete damage of bilateral auditory radiations and postcentral gyruses in both hearing here. Anarthria could be caused by lesions in the third frontal gyruses. Our patient's hearing loss should be diagnosed as cortical deafness on the basis of Hirano's paper on 'so-called cortical deafness' [5]. Before Hirano's report, objective audiometry was not used in clinical medicine. However, after Hirano and Tanaka et al. reported on 'so-called' cortical deafness [5,6], we also encountered a case of cortical deafness that was revealed by neuropathological study [7].

The patient in the present study demonstrated normal DPOAE and ABR, and complete loss of hearing. A patient with auditory agnosia may show residual hearing because of only partial damage of bilateral auditory cortices and radiations. On the other hand, cortical deafness as in the case of our patient can be caused by complete damage of these brain regions. In his daily life our patient makes efforts to live a safe and enjoyable life despite the complete loss of hearing and somatosensory sensation by, for example, devising a way to adjust and check the temperature of his bath. Moreover, he cannot feel earthquakes. He communicates with others by writing because of anarthria. Taken together, the patient has central deafness and is mute.

In our clinic, he underwent training for lip-reading to aid his communication, but his learning was poor. Presently, he communicates by writing only.

## Conclusion

From the findings of this particular patient, we consider that the complete loss of hearing can be caused by complete damage of the bilateral auditory cortices and radiations. This central deafness should be named cortical deafness.

On the other hand, auditory agnosia can be caused by partial damage of bilateral auditory cortices and radiations owing to lesions.

## Acknowledgments

We thank Dr Hiroyuki Ito for his clinical contribution in Kanagawa Rehabilitation Hospital and Ms Kayoko Sekiguchi for her secretarial assistance.

**Declaration of interest:** The authors report no conflicts of interest. The authors alone are responsible for the content and writing of the paper.

## References

- [1] Kaga K. Central auditory pathway disorders. Springer; Tokyo, Japan. 2009.
- [2] Lhermitte F, Chain F, Escourolle R. [Study of auditory perception disorders in bilateral temporal lesions. (3 case studies 2 of which are anatomoclinical)]. *Rev Neurol* 1971; 124:329–51; in French.
- [3] Kaga K, Kaga M, Tamai F, Shindo M. Auditory agnosia in children after herpes encephalitis. *Acta Otolaryngol* 2003;123: 232–5.
- [4] Kaga K, Shindo M, Tanaka Y, Haebara H. Neuropathology of auditory agnosia following bilateral temporal lobe lesions. A case study. *Acta Otolaryngol* 2000;120:259–62.
- [5] Hirano S. ‘So-called’ cortical deafness. *Psychiatria et Neurologia Japonica* 1973;75:94–138.
- [6] Tanaka Y, Kamo T, Yoshida M, Yamadori A. ‘So-called’ cortical deafness. Clinical, neuropsychological and radiological observations. *Brain* 1991;114:2385–401.
- [7] Kaga K, Shindo M, Tanaka Y. Central auditory information processing in patients with bilateral auditory cortex lesions. *Acta Otolaryngol Suppl* 1997;532:77–82.