

## CASE REPORT

## Emergency placement of stent-graft for symptomatic acute carotid artery occlusion after endarterectomy

Jun Kyeung Ko,<sup>1</sup> Chang Hwa Choi,<sup>1</sup> Sang Weon Lee,<sup>2</sup> Tae Hong Lee<sup>3</sup>

► Additional material is available. To view please visit the journal online (<http://dx.doi.org/10.1136/bcr-2014-011553>).

<sup>1</sup>Department of Neurosurgery, Medical Research Institute, Pusan National University Hospital, Busan, Republic of Korea

<sup>2</sup>Department of Neurosurgery, Medical Research Institute, Pusan National University Yangsan Hospital, Yangsan, Republic of Korea

<sup>3</sup>Department of Diagnostic Radiology, Medical Research Institute, Pusan National University Hospital, Busan, Republic of Korea

**Correspondence to**

Dr Tae Hong Lee, Department of Diagnostic Radiology, Pusan National University Hospital, 179, Gudeok-ro, Seo-Gu, Busan 602-739, Republic of Korea; [drcello@lycos.co.kr](mailto:drcello@lycos.co.kr)

Accepted 2 January 2015

**SUMMARY**

A patient underwent a left-sided carotid endarterectomy (CEA) for an asymptomatic 80% carotid artery (CA) stenosis. There were no signs of intolerance during the carotid cross-clamping and an initially uneventful awakening was observed. However, in the third postoperative hour he experienced left amaurosis and dysarthria. An urgent MRI showed an occluded internal CA on the operated site without evidence of acute infarction. To recanalize the occluded internal CA and minimize leakage from the arteriotomy site, a self-expandable stent-graft was placed, covering the dissection and the distal atherosclerotic lesions. Complete recanalization of the left internal CA was achieved and the patient showed a dramatic improvement of his preoperative deficits. To our knowledge, this is the first case of stent-graft implantation for a symptomatic acute CA occlusion following CEA. Stent-graft placement should be considered as an alternative method of treatment for acute CA occlusion or dissection following CEA.

**BACKGROUND**

Perioperative stroke has been reported in 1.5–9% of carotid endarterectomy (CEA) cases.<sup>1</sup> Several reports have documented that acute thrombus at the endarterectomy site is a common cause of neurological deficit after CEA.<sup>2–3</sup> Other causes include carotid artery (CA) dissection, hypotension, embolization, and intracerebral hemorrhage.<sup>1</sup> Controversy exists with regard to which diagnostic tests should be performed and which definitive therapy is optimal.<sup>4–5</sup> We recently experienced a case in which stent-graft placement was used for treatment of a symptomatic occlusion of the CA that occurred immediately after CEA.

**CASE PRESENTATION**

The patient was referred for management of an incidental CA stenosis. Cerebral angiography confirmed an 80% stenosis of the left proximal internal carotid artery (ICA) with high location of the carotid bifurcation and a very distal extension of atheromatous plaques ([figure 1](#)). A perfusion study was normal. After discussion of the management options and associated risks, the patient elected to proceed with CEA. CEA was performed under sedation without intraoperative shunting. After adequate exposure of the CA the patient was given 5000 IU intravenous heparin. No sign of intolerance was observed during the carotid cross-clamping. As expected, the plaque extended so far cranially that it could not be removed entirely, so

microscissors were used to trim the plaque distally and create the distal breakpoint. Distal intemectomy was easily achieved and no tacking points were needed. After confirming the presence of a good back-flow, the arteriotomy was closed without the interposition of a patch and no stenosis occurred. Intraoperative ultrasound was also normal. Blood pressure in the perioperative period was controlled with a mean systolic range of 110–100 mm Hg. The patient initially showed an uneventful awakening. However, in the third postoperative hour he experienced left amaurosis and dysarthria. An urgent MRI showed an occluded ICA on the operated site without evidence of acute infarction ([figure 2A, B](#)). Consent was obtained from the patient's family for emergency cerebral angiography and possible endovascular intervention.

**TREATMENT**

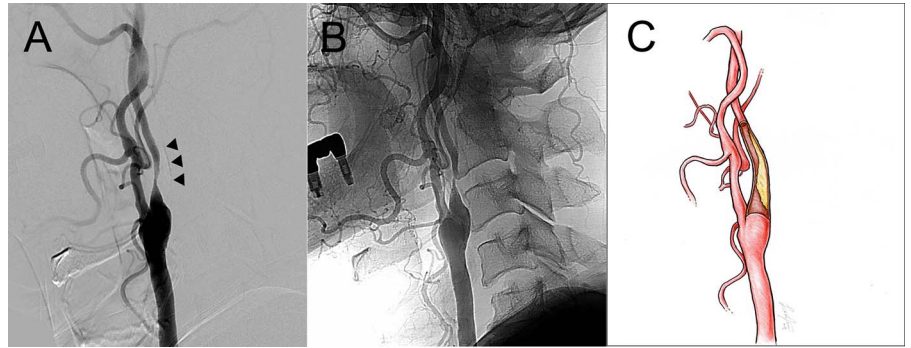
A left CA angiogram showed complete occlusion at the endarterectomy site ([figure 3A](#)). On the left CA angiogram the intracranial segment of the left ICA and middle cerebral artery were visualized with poor contrast via the collateral vessels of the external CA and the ophthalmic artery ([figure 3B, C](#)). Collateral circulation was provided mainly by the right ICA through the anterior communicating artery, but was very slow and insufficient ([figure 3D](#)). A 6 Fr Shuttle sheath was then advanced into the CA proximal to the occluded site. A 0.014 inch microwire (Transcend Ex; Boston Scientific Target, Fremont, California, USA) was advanced through the occluded segment to the distal cervical ICA. Angiography provided assurance that the occluded segment was partially recanalized with a high-grade stenosis and the intracranial segment of the left ICA and middle cerebral artery was patent ([figure 4A](#)). After passing the ICA occlusion using a 5 Fr Spider Embolic Protection Device, predilation was performed. Angiography after predilation showed partial re-expansion of the vessel lumen indicative of a dissection in the proximal segment of the ICA ([figure 4B](#)). A 6 mm×5 cm Viabahn stent-graft (Gore, Newark, DE, USA) was introduced and positioned from the ICA just above the carotid bifurcation to the distal cervical ICA to cover the dissection and the distal atherosclerotic lesions. The sheath was withdrawn to expose the stent. Recanalization of the left ICA was achieved, but postdilation was required in order to resolve the residual stenosis. It was dilated to the normal artery size, being careful not to dilate outside the confines of the stent-graft. Angiography showed good



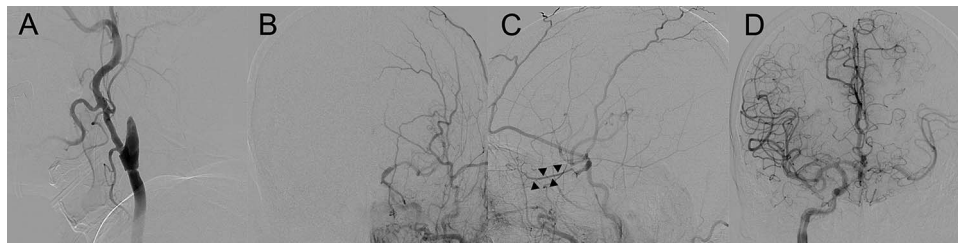
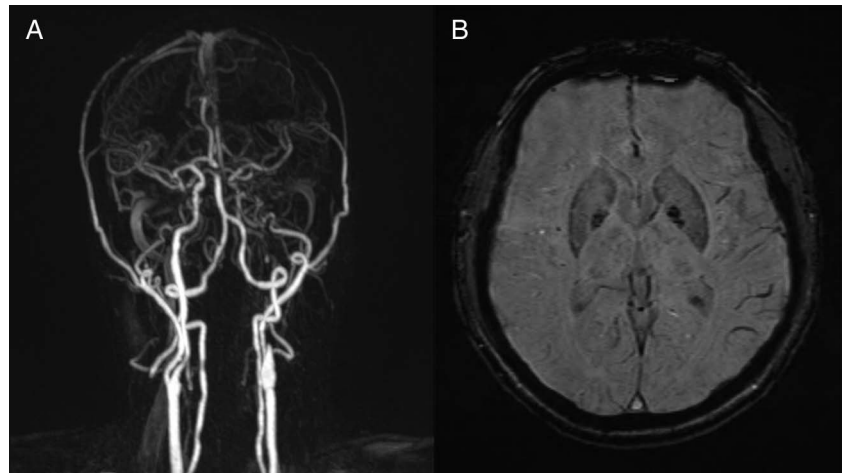
CrossMark

**To cite:** Ko JK, Choi CH, Lee SW, et al. *BMJ Case Rep* Published online: [please include Day Month Year] doi:10.1136/bcr-2014-011553

**Figure 1** (A) Subtracted and (B) unsubtracted digital subtraction angiograms and (C) representative illustration demonstrating an 80% stenosis of the left proximal internal carotid artery (CA). The left common CA bifurcates at the level of the third cervical vertebrae. The plaque is thickest at the level between the second and the third cervical vertebrae and seems to be very distally extended, considering the relatively narrow lumen of the distal cervical internal CA and calcific boundary of the internal CA (arrowheads).



**Figure 2** (A) MR angiogram with contrast enhancement 3 h after carotid endarterectomy shows the occluded internal carotid artery on the operated site. (B) Maximum intensity projection image implies a stasis of cerebral blood flow at the left hemisphere.



**Figure 3** (A) Angiography of the left common carotid artery (CA) shows complete occlusion at the endarterectomy site. (B) Anteroposterior and (C) lateral views of the left common CA angiogram show that the intracranial segment of the left internal CA and middle cerebral artery is visualized with poor contrast via the collateral vessels of the external CA and the ophthalmic artery (arrowheads). (D) Collateral circulation is provided mainly by the right internal CA through the anterior communicating artery, but is very slow and insufficient.

re-expansion of the vessel lumen and excellent filling of the intracranial circulation (figure 4C, D).

### OUTCOME AND FOLLOW-UP

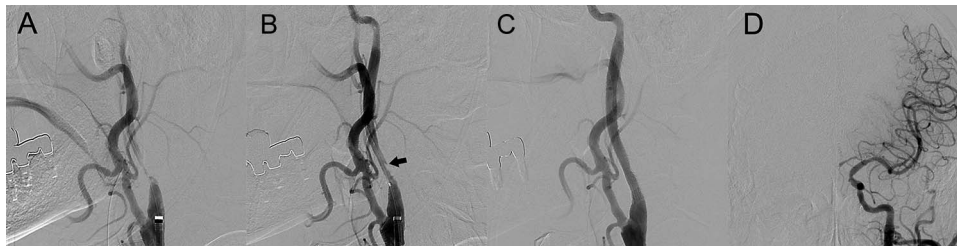
The patient showed a dramatic improvement in his preoperative neurological deficits soon after the procedure. He received 100 mg aspirin and 75 mg clopidogrel (Plavix; Sanofi-Synthelabo, Seoul, Korea) daily according to our protocol for graft-stent placement in cerebral vessels. The patient remains asymptomatic 6 months after discharge.

### DISCUSSION

Acute thrombosis after CEA is the most common cause of perioperative stroke, accounting for up to 75% of cases.<sup>4</sup> Distal

intimal flap represents another important cause of such a complication.<sup>3</sup>

Although our case was thought to be challenging for performing usual CEA due to the high location of the carotid bifurcation and distal extension of atheromatous plaques, we thought that the carotid flow could be sufficiently recovered if the thick plaque in the most stenotic region—not the entire plaque—could be removed effectively just above the carotid bifurcation. As expected, the plaque extended so far cranially that it could not be removed entirely. We therefore created the distal breakpoint and closed the arteriotomy without stenosis after confirming the presence of a good back-flow. However, acute carotid occlusion—presumably caused by a dissection from the distal intimal flap—induced severe hypoperfusion of the ipsilateral hemisphere and resulted in neurologic deterioration. In this



**Figure 4** (A) Angiography after passing the internal carotid artery (CA) occlusion using a 0.014 inch microwire demonstrating a partially recanalized internal CA with a high-grade stenosis. (B) Angiography after balloon predilation showing partial re-expansion of the vessel lumen. The arrow indicates a flow-limiting dissection in the proximal segment of the internal CA. (C) Angiography after stent-graft implantation and postdilation shows good re-expansion of the vessel lumen and normal internal carotid artery outflow. (D) Control angiogram shows excellent filling of the intracranial circulation.

situation, immediate re-exploration for thrombectomy may lead to unsuccessful restoration of the flow of the CA.

According to one report, implantation of a bare stent appears to be a safe and effective strategy in the treatment of perioperative stroke complicating CEA, especially when carotid dissection represents the main anatomic problem.<sup>6</sup> However, we thought that a stent-graft would be more suitable for in-stent balloon angioplasty (that could rupture the suture line) than a bare stent because the safety of the suture site was not secured. Placement of stent-grafts in the CA has been difficult due to the risk of cerebral infarction resulting from acute dissection, occlusion, or embolism, which may be caused by the large profile and size of the device and lack of flexibility of delivery systems.<sup>7, 8</sup> Nevertheless, carotid stent-grafts would be most suitable for carotid lesions with impending rupture requiring emergency recanalization, as in the current case. To

the best of our knowledge, this is the first case of implantation of a self-expandable stent-graft for a symptomatic acute CA occlusion following CEA.

**Acknowledgements** We thank Mr Jae Min Lee for preparing the illustrations.

**Contributors** JKK and THL were primarily responsible for study design, collecting data and drafting the manuscript. CHC and SWL contributed significantly to this report by critically reading the manuscript and providing many helpful suggestions. All of the authors read and approved the manuscript to be submitted for publication.

**Competing interests** None.

**Patient consent** Obtained.

**Provenance and peer review** Not commissioned; externally peer reviewed.

## REFERENCES

- Zarins CK. Carotid endarterectomy: the gold standard. *J Endovasc Surg* 1996;3:10–15.
- Koslow AR, Ricotta JJ, Ouriel K, *et al.* Reexploration for thrombosis in carotid endarterectomy. *Circulation* 1989;80:73–8.
- Ross CB, Ranval TJ. Intraoperative use of stents for the management of unacceptable distal internal carotid artery end points during carotid endarterectomy: short-term and midterm results. *J Vasc Surg* 2000;32:420–7.
- Findlay JM, Marchak BE. Reoperation for acute hemispheric stroke after carotid endarterectomy: is there any value? *Neurosurgery* 2002;50:486–92.
- Simma W, Hesse H, Gilhofer G, *et al.* Management of immediate occlusion after carotid-reconstruction. *J Cardiovasc Surg* 1987;28:176–9.
- Anzuini A, Briguori C, Roubin GS, *et al.* Emergency stenting to treat neurological complications occurring after carotid endarterectomy. *J Am Coll Cardiol* 2001;37:2074–9.
- Lesley WS, Chaloupka JC, Weigle JB, *et al.* Preliminary experience with endovascular reconstruction for the management of carotid blowout syndrome. *AJNR Am J Neuroradiol* 2003;24:975–81.
- Hoppe H, Barnwell SL, Nesbit GM, *et al.* Stent-grafts in the treatment of emergent or urgent carotid artery disease: review of 25 cases. *J Vasc Interv Radiol* 2008;19:31–41.

## Learning points

- ▶ We recently experienced a case of symptomatic occlusion of the CA that occurred immediately after CEA.
- ▶ To recanalize the occluded ICA and minimize leakage from the arteriotomy site, a self-expandable stent-graft was placed.
- ▶ Stent-graft placement should be considered as an alternative method of treatment for acute CA occlusion or dissection following CEA.

Copyright 2015 BMJ Publishing Group. All rights reserved. For permission to reuse any of this content visit <http://group.bmj.com/group/rights-licensing/permissions>.  
BMJ Case Report Fellows may re-use this article for personal use and teaching without any further permission.

Become a Fellow of BMJ Case Reports today and you can:

- ▶ Submit as many cases as you like
- ▶ Enjoy fast sympathetic peer review and rapid publication of accepted articles
- ▶ Access all the published articles
- ▶ Re-use any of the published material for personal use and teaching without further permission

For information on Institutional Fellowships contact [consortiasales@bmjgroup.com](mailto:consortiasales@bmjgroup.com)

Visit [casereports.bmj.com](http://casereports.bmj.com) for more articles like this and to become a Fellow