

Pediatric Neurocysticercosis: Three Cases Presented in the Netherlands with Divergent Clinical Presentations

Laura A. van de Pol¹ T. E. M. van Doeveren¹ M. van der Kuip² N. I. Wolf¹ R. J. Vermeulen¹

¹Department of Child Neurology, VU University Medical Center, Amsterdam, The Netherlands

²Department of Pediatric Infectious Diseases and Immunology, VU University Medical Center, Amsterdam, The Netherlands

Address for correspondence Laura A. van de Pol, MD, PhD, Department of Child Neurology, VU University Medical Center, Amsterdam, The Netherlands (e-mail: l.vandepol@vumc.nl).

Neuropediatrics 2015;46:130–133.

Abstract

Background Neurocysticercosis is a helminthic disease that affects the central nervous system by the larvae of the *Taenia solium*, the pork tapeworm. Because of the growing number of immigrants from endemic areas, its incidence is increasing in Western Europe.

Cases We describe three children, aged between 2 and 13 years, two of whom have a definite and one a probable diagnosis of neurocysticercosis based on the “Del Brutto criteria.” They presented with different symptoms and signs: symptomatic epilepsy, asymmetric cerebral palsy, and headache. Serological evaluation was negative in two of the three cases. All cases showed comparable abnormalities on magnetic resonance imaging of the brain: solitary or multiple, cystic lesions, with surrounding edema. In one of them, the “scolex” (part of the larvae) could be visualized. One case was treated with albendazole, the other two cases did not receive medication.

Conclusion A prompt diagnosis of neurocysticercosis by recognition of its typical brain lesions is important to prevent unnecessary diagnostic tests and treatment.

Keywords

- ▶ neurocysticercosis
- ▶ pediatric
- ▶ MRI

Background

Neurocysticercosis is an infection of the central nervous system by the larvae of the pork tapeworm, *Taenia solium*. It is a major cause of neurological disease and even the most common cause of epilepsy in the developing world.¹ Neurocysticercosis is rare in Western Europe, however, its incidence has increased over the past 30 years as a result of immigration from endemic areas.² Clinical presentation is variable and prognosis is often favorable.¹

We describe three cases of children diagnosed with neurocysticercosis in our hospital in the past 5 years. These cases illustrate the variety in clinical symptoms, which, in combination with the relative rarity of the disease in the developed world, may lead to diagnostic delay and unnecessary diagnostic procedures and treatment.

Case Reports

Case 1

A 13-year-old girl from Nepal who had been living in the Netherlands for 11 years presented with two generalized epileptic seizures. Neurological examination showed mild gait ataxia and a minor intention tremor of the left arm. Brain magnetic resonance imaging (MRI) revealed a calcification in the left parietal lobe and a partially enhancing annular lesion, with significant perilesional edema in the right parietal area (▶ **Fig. 1**). Blood investigation showed an erythrocyte sedimentation rate of 67 mm/h and a C-reactive protein level of 67.0 mg/L. Serological testing (LDBio immunoassay [LDBIO Diagnostics, Lyon, France]³ and in the case of nonconclusive results an additional test: the Qualidcode of Immunetics [Immunetics Inc., Boston, Massachusetts, United States])

received

June 6, 2014

accepted after revision

November 15, 2014

published online

February 2, 2015

© 2015 Georg Thieme Verlag KG
Stuttgart · New York

DOI <http://dx.doi.org/10.1055/s-0034-1399753>.
ISSN 0174-304X.

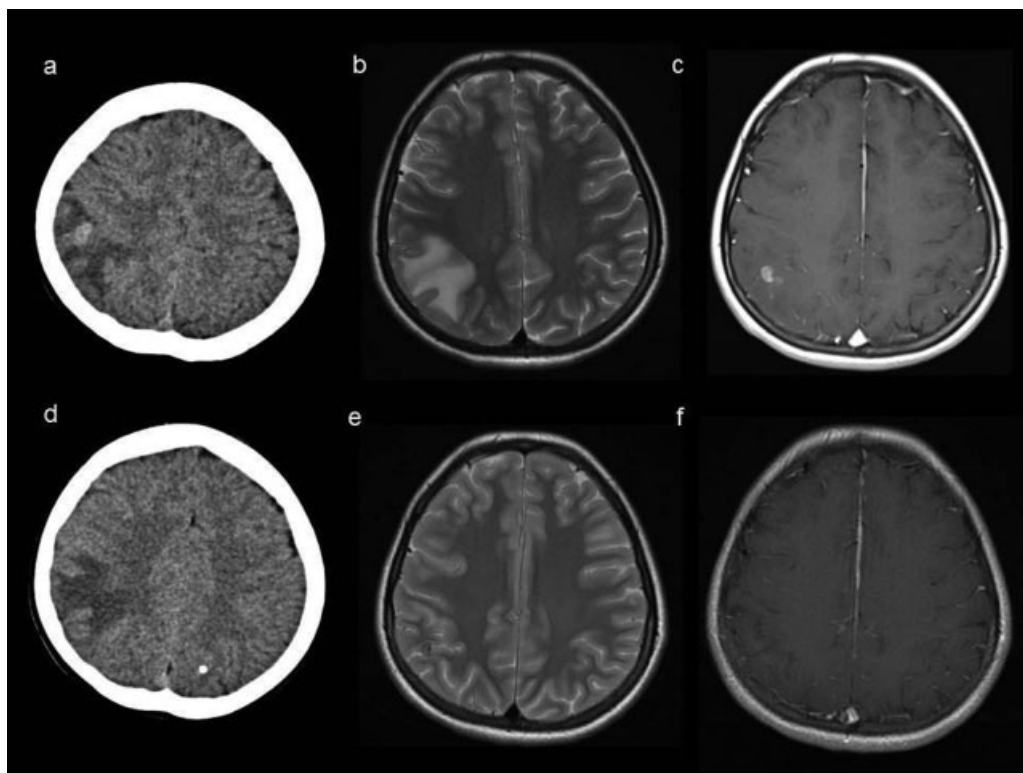


Fig. 1 Case 1. (a) Computed tomographic (CT) scan of the brain at presentation showing a lesion in the right parietal area. (b) T2-weighted magnetic resonance imaging (MRI) scan at presentation showing edema in the right parietal lobe. (c) T1-weighted MRI scan with gadolinium at presentation showing a partially enhancing annular lesion with perilesional edema. (d) CT scan of the brain showing a calcified lesion in the left parietal lobe. (e, f) T2-weighted MRI scan and T1-weighted MRI scan with gadolinium at follow-up show reduction of the edema and the lesion in the right parietal lobe.

revealed anticysticercal antibodies in serum. Serological tests and an in-house developed polymerase chain reaction (PCR) for the detection of *Taenia solium* DNA (a CO1 and NADH1 PCR) were negative in cerebrospinal fluid (CSF). On the basis of the “del Brutto criteria” for neurocysticercosis, our patient fulfilled two major criteria (evidence of lesions highly suggestive of neurocysticercosis on neuroimaging and positive serum immunoblot for the detection of anticysticercal antibodies) plus one epidemiologic criterion (individuals coming from or living in an area where cysticercosis is endemic) consistent with a definitive diagnosis of neurocysticercosis.⁴ The patient was treated with albendazole (15 mg/kg/d: 300 mg twice daily for 7 days) in combination with dexamethasone (1 mg three times a day) and oxcarbazepine. After admission, she remained seizure free. Oxcarbazepine was discontinued after 16 months. A follow-up MRI, 3 months later, showed clear reduction of the abnormalities.

Case 2

A 2-year-old girl, born in Cambodia and adopted at 6 months of age, presented with a motor developmental delay and a preference for the left side. No medical history was available. Physical examination showed plagiocephaly on the left side. She did not walk independently until the age of 24 months. A mild asymmetric cerebral palsy (Gross Motor Function Classification Scale class I⁵) was found on neurological examination, consisting of hypertonia and hyperreflexia of the right arm and leg. Brain MRI revealed a large fluid cavity in the left

frontal lobe and a smaller fluid cavity in the right frontal lobe. Both fluid cavities contained multiple well-definable, annular-enhancing lesions, suggestive of neurocysticercosis. Routine blood investigations were unremarkable. No information from family members was available, as she had been adopted. According to the “del Brutto criteria” for neurocysticercosis she had one major criterion (evidence of lesions highly suggestive of neurocysticercosis on neuroimaging), one minor criterion (presence of clinical manifestations suggestive of neurocysticercosis [that is, focal neurological signs]) and one epidemiological criterion (individuals coming from or living in an area where cysticercosis is endemic) compatible with a probable diagnosis of neurocysticercosis.⁴ Her stable neurological development since she had been adopted was the reason to refrain from treatment. A follow-up MRI after 2 years showed no changes.

Case 3

A 7-year-old vegetarian boy of Indian ancestry, born in the Netherlands, with a travel history in India, reported severe headaches regularly accompanied by nausea and vomiting since 2 weeks. Physical examination was unremarkable. Brain MRI showed two confluent small cysts in the right occipital lobe of which at least one showed a possible scolex (→ Fig. 2), which is one of the absolute criteria for a definitive diagnosis of neurocysticercosis according to the “del Brutto criteria.”⁴ Blood investigations (including cysticercosis serology) were unremarkable. Lumbar puncture showed an increased opening pressure of

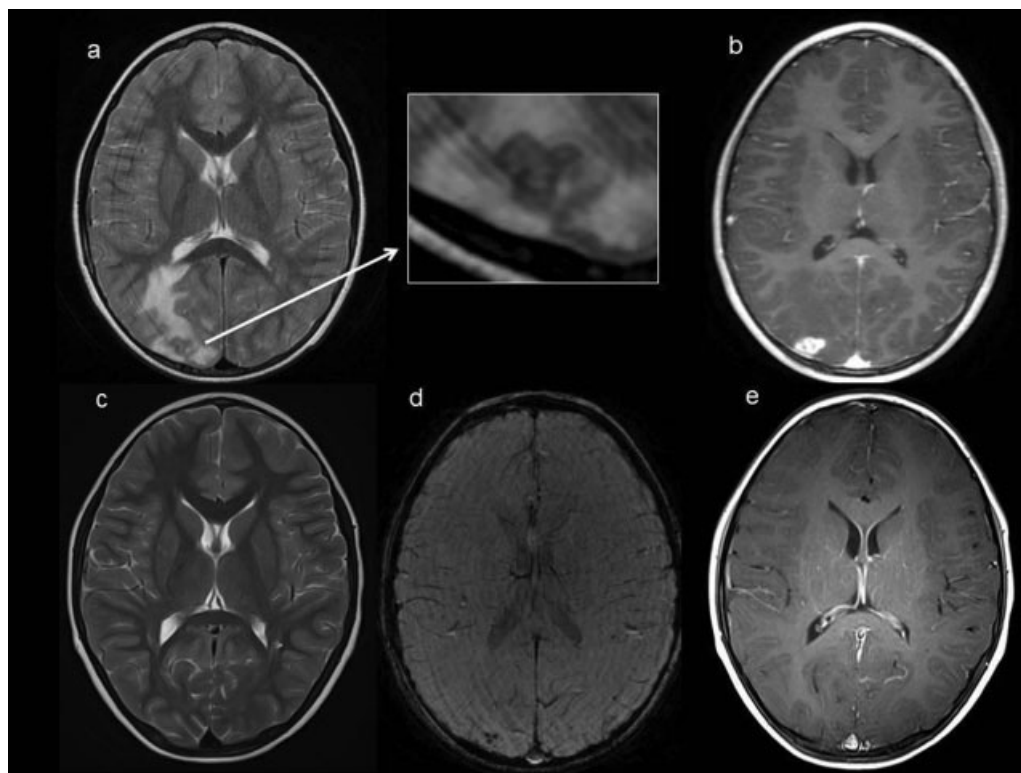


Fig. 2 Case 3. (a) T2-weighted magnetic resonance imaging (MRI) at presentation showing two confluent small cysts in the right occipital lobe, of which at least one showed a possible scolex. (b) T1-weighted MRI with gadolinium at presentation showing enhancement of the lesion. (c) T2-weighted MRI 3 months later showing clear reduction of the lesion. (d) Susceptibility weighted MRI at follow-up showing calcification of the lesion. (e) T1-weighted MRI with gadolinium at follow-up showing clear reduction of the lesion.

38 cm H₂O. CSF analysis revealed a leukocyte count of 9/uL, with an increased proportion of eosinophilic granulocytes. No serological testing or PCR was performed in CSF. A follow-up MRI, 1 month later, showed a clear reduction of the lesion. On susceptibility weighted MRI calcification of the lesion was evident, indicating progression to the granular-calcified stage of the disease. Because of quick spontaneous regression of symptoms and MRI lesions no treatment was started.

Discussion

Neurocysticercosis is endemic in the third world countries, but it is still a rare disease in the developed world.¹ In the past 5 years, we have seen three cases, one of whom had a probable diagnosis, in our center in Amsterdam, The Netherlands. Fabiani and Bruschi recently reviewed all case studies of neurocysticercosis in Europe published since 1970.⁶ Only three Dutch case reports, describing 16 patients, with neurocysticercosis have been published in the past 44 years.⁶ Of the 176 cases in total published from Europe, the majority were imported cases. Rosenfeld et al described 47 children with neurocysticercosis in Chicago, of whom 96% were Hispanic.⁷ These studies show that the majority of cases of neurocysticercosis in the developed world are imported from endemic areas. This holds true for our patients as well; patients 1 and 2 were born in Nepal and Cambodia, respectively, and patient 3 frequently travelled to India. Epidemiologic information is therefore an important clue to the diagnosis.

In children of all ages, seizures, headache, and vomiting are the most common presenting symptoms.⁸ This is consistent with our patients, presenting with symptomatic epilepsy (patient 1) and headache with vomiting (patient 3). Our second patient, however, presented differently with cerebral palsy. In the literature, neurocysticercosis is renowned for its pleomorphic clinical presentation, depending on the stage, number, location, and size of the parasites, as well on the age and immune response of the host.¹ Neurocysticercosis should be considered as a diagnosis in a wide variety of neurological symptoms, independent of age.

By eating undercooked pork meat, *Taenia solium* cysts can develop into adult parasites in the human digestive tract, which is called cysticercosis. Neurocysticercosis can develop when a person is infected with eggs from the *Taenia solium* by fecal–oral transmission from a person with cysticercosis, that become encysted in the central nervous system.¹ So, under poor hygienic circumstances, also vegetarian patients, such as our third patient, can develop neurocysticercosis. The cysts will evolve through four stages. First, in the vesicular stage, the cysts contain a living larva, which may be visible on MRI as the “scolex.” Degeneration of the cyst is initiated by an immunological reaction of the host, and the colloidal stage is entered, in which the vesicular fluid becomes turbid and the larvae show signs of hyaline degeneration. The third phase is the “granulonodular” phase as the membrane of the cyst thickens, and the cysticercus is no longer viable. Finally, calcification of the lesion will take place.^{1,9}

In 2001, Del Brutto et al proposed diagnostic criteria for neurocysticercosis, with different degrees of diagnostic certainty.⁴ Absolute criteria are based on direct demonstration of the parasite by biopsy, identification of the scolex on MRI or fundoscopic examination demonstrating subretinal parasites. In clinical practice, the diagnosis is often made by a combination of clinical and epidemiological information together with MRI and serological testing of serum and CSF.⁴ In our patients, we used (at least) the following MRI sequences: sagittal and/or transversal fluid-attenuated inversion recovery (FLAIR), axonal T1-weighted series with and without gadolinium, axonal T2-weighted imaging, and diffusion-weighted imaging. Lucato et al concluded that FLAIR images detect a significantly higher number of scolices than other sequences. For demonstrating the lesions, a T1-weighted sequence with gadolinium is recommended.¹⁰ T2-weighted sequence is relevant to demonstrate perilesional edema.⁸ To detect calcifications, computed tomography has been described to be more sensitive than MRI.⁸ However, in our third patient, the susceptibility weighted MRI clearly showed the calcified lesion, and this sequence together with the fast imaging employing steady-state acquisition image may be of value in diagnosing neurocysticercosis.

Pediatric neurocysticercosis differs from that in adults. Children most often present with a single parenchymal cyst, whereas extraparenchymal disease is rare.¹¹ Indeed, our three patients had parenchymal disease. However, two out of the three patients showed more than one lesion (patients 1 and 2). In addition, CSF abnormalities (elevated cell count and protein level) are infrequently found in children.^{8,11} In case 3, we found a mild pleocytosis with normal protein level and glucose concentration. However, the increased proportion of eosinophilic granulocytes was a clue to the diagnosis. Serological testing in serum or CSF, using enzyme-linked immunoelectrotransfer blot, can be performed to confirm suspected diagnosis and has high sensitivity (98%) and specificity (100%) in subjects with two or more lesions.^{1,2} However, in subjects with a single parenchymal lesion sensitivity is low, with a false-negative result in up to 50% of cases. Therefore, especially in children, negative serology and normal CSF findings do not exclude neurocysticercosis.

Neurocysticercosis is treated using a combination of antiparasitic medication; albendazole and/or praziquantel, steroids, and antiepileptic drugs. However, exact indications for treatment in the individual patient are not precisely defined. In 2013, a guideline for the treatment of parenchymal neurocysticercosis was published by the American Academy of Neurology suggesting to consider albendazole plus steroids in adults and children both to decrease the number of active lesions on brain imaging studies and to reduce long-term seizure frequency. This guideline is based on reviewing the existing randomized controlled trials.⁹ However, the studies reviewed were heterogeneous with regard to number of lesions and treatment regimen.¹² Recently, the results of a large RCT comparing different treatment regimens in neurocysticercosis were published favoring the use of albendazole in combination with praziquantel over treatment with one

antiparasitic drug alone.¹³ Despite these recent efforts, treatment of neurocysticercosis remains controversial.^{12,14} We feel that the indication for and type of treatment should be considered in every patient individually.

Neurocysticercosis is a rare infectious disease in developed countries. Because of increased migration from endemic areas, it should be included in the differential diagnosis of a variety of neurological symptoms in children. Clinical manifestations combined with an epidemiological history and characteristic MRI abnormalities lead to the diagnosis in most cases. A just and timely diagnosis can prevent children from unnecessary diagnostic testing and treatment.

Acknowledgments

The authors acknowledge the assistance of Dr. M. Manohar Shroff with coassessment and advice on the neuroimaging of case 3.

References

- 1 Del Brutto OH. Neurocysticercosis. *Continuum (Minneapolis)* 2012;18:1392–1416
- 2 Garcia HH, Del Brutto OH; Cysticercosis Working Group in Peru. Neurocysticercosis: updated concepts about an old disease. *Lancet Neurol* 2005;4(10):653–661
- 3 Michelet L, Fleury A, Sciotto E, et al. Human neurocysticercosis: comparison of different diagnostic tests using cerebrospinal fluid. *J Clin Microbiol* 2011;49(1):195–200
- 4 Del Brutto OH, Rajshekhar V, White AC Jr, et al. Proposed diagnostic criteria for neurocysticercosis. *Neurology* 2001;57(2):177–183
- 5 Palisano R, Rosenbaum P, Walter S, Russell D, Wood E, Galuppi B. Development and reliability of a system to classify gross motor function in children with cerebral palsy. *Dev Med Child Neurol* 1997;39(4):214–223
- 6 Fabiani S, Bruschi F. Neurocysticercosis in Europe: Still a public health concern not only for imported cases. *Acta Trop* 2013;128(1):18–26
- 7 Rosenfeld EA, Byrd SE, Shulman ST. Neurocysticercosis among children in Chicago. *Clin Infect Dis* 1996;23(2):262–268
- 8 Singhi P, Singhi S. Neurocysticercosis in children. *Indian J Pediatr* 2009;76(5):537–545
- 9 Baird RA, Wiebe S, Zunt JR, Halperin JJ, Gronseth G, Roos KL. Evidence-based guideline: treatment of parenchymal neurocysticercosis: report of the Guideline Development Subcommittee of the American Academy of Neurology. *Neurology* 2013;80(15):1424–1429
- 10 Lucato LT, Guedes MS, Sato JR, Bacheschi LA, Machado LR, Leite CC. The role of conventional MR imaging sequences in the evaluation of neurocysticercosis: impact on characterization of the scolex and lesion burden. *AJNR Am J Neuroradiol* 2007;28(8):1501–1504
- 11 Sáenz B, Ruíz-García M, Jiménez E, et al. Neurocysticercosis: clinical, radiologic, and inflammatory differences between children and adults. *Pediatr Infect Dis J* 2006;25(9):801–803
- 12 Burneo JG, Escalaya AL, Gonzalez-Duarte A. Evidence-based guideline: Treatment of parenchymal neurocysticercosis: report of the guideline development subcommittee of the American Academy of Neurology. *Neurology* 2013;81(16):1474–1476
- 13 Garcia HH, Gonzales I, Lescano AG, et al. Efficacy of combined antiparasitic therapy with praziquantel and albendazole for neurocysticercosis: a double-blind, randomised controlled trial. *Lancet Infect Dis* 2014;14(8):687–695
- 14 Singh G, White AC Jr. Determining better treatments for neurocysticercosis. *Lancet Infect Dis* 2014;14(8):658–659

Copyright of Neuropediatrics is the property of Georg Thieme Verlag Stuttgart and its content may not be copied or emailed to multiple sites or posted to a listserv without the copyright holder's express written permission. However, users may print, download, or email articles for individual use.