

CASE REPORT

Mania occurring during systemic lupus erythematosus relapse and its amelioration on clinical and neuroimaging follow-up

T Hirachi¹, H Ishii¹, Y Tada², T Noguchi³, Y Haraguchi¹, H Tateishi¹, Y Mizoguchi¹, TA Kato⁴,
T Kawashima¹ and A Monji¹

¹Department of Psychiatry, Saga University, Japan; ²Department of Rheumatology, Saga University, Japan; ³Department of Radiology, Saga University, Japan; and ⁴Department of Neuropsychiatry, Graduate School of Medical Sciences, Kyushu University, Japan

Psychiatric manifestations of systemic lupus erythematosus (SLE) that are commonly preceded by organic syndromes include confusional states, anxiety disorder, cognitive dysfunction, mood disorder and psychosis. A 35-year-old woman was admitted to hospital with a relapse of SLE. Laboratory data were exacerbated, with some physical symptoms, and her primary psychiatric symptom was mania. The symptoms were reduced by treatment with prednisolone, methylprednisolone and aripiprazole. Magnetic resonance imaging and single-photon emission computed tomography (SPECT) using ¹²³I-IMP was then performed and analyzed with three-dimensional stereotactic surface projection. This case emphasizes that SLE can commence with organic syndromes and relapse with predominantly psychiatric symptoms, and that the treatment efficacy may be confirmed using a follow-up of SPECT. *Lupus* (2015) 0, 1–4.

Key words: Systemic lupus erythematosus (SLE); relapse; mania; single-photon emission computed tomography (SPECT); magnetic resonance imaging (MRI)

Introduction

Neuropsychiatric systemic lupus erythematosus (NPSLE) develops in approximately 20–70% of patients with systemic lupus erythematosus (SLE) during the course of the disease.¹ There are 19 peripheral and central nervous system (CNS) syndromes that are associated with SLE. Five of the CNS syndromes are psychiatric: acute confusional state, anxiety disorder, cognitive dysfunction, mood disorder and psychosis.² Overlooking psychiatric symptoms may have severe consequences for the patient, including decreased quality of life, disability and loss of employment; any of which can worsen other psychiatric symptoms. Mania is also present in approximately 3% of patients, and is often considered to be caused by corticosteroid treatment.^{3–5} Here we report a case of SLE that

relapsed as mania because of the discontinuation of corticosteroid treatment. Re-administration of corticosteroids ameliorated manic symptoms, which was confirmed by single-photon emission computed tomography (SPECT) using ¹²³I-IMP and analyzed by three-dimensional stereotactic surface projection (3D-SSP).

Case report

A 35-year-old woman, who had no past or family history of psychiatric disorders, was diagnosed with SLE at 31 years of age with the fulfillment of the following American College of Rheumatology criteria: malar rash, photosensitivity, arthritis and the presence of antinuclear antibodies. Prednisolone (20 mg/day) was started for the treatment of SLE at 32 years of age and SLE gradually subsided. The patient discontinued corticosteroid treatment at her own discretion at 34 years of age. Approximately 5 months after the discontinuation of corticosteroid treatment, her mood became labile and irritable. She exhibited overactivity with pressured speech, flight of ideas and decreased concentration.

Correspondence to: Toru Hirachi, Department of Psychiatry, Faculty of Medicine, Saga University, Nabeshima 5-1-1, Saga 849-8501, Japan. Email: si5059@cc.saga-u.ac.jp

Akira Monji, Department of Psychiatry, Faculty of Medicine, Saga University, Nabeshima 5-1-1, Saga 849-8501, Japan.

Email: amonji@hf.rim.or.jp

Received 28 April 2014; accepted 7 January 2015

Physically, she complained only of arthralgia. Her laboratory data included a high erythrocyte sedimentation rate (31 mm/hour), cytopenia (white blood cell count = $4.7 \times 10^3/\mu\text{L}$, red blood cell count = $3.91 \times 10^6/\mu\text{L}$), low levels of complements (C3 = 27 mg/dL, C4 = 1 mg/dL, CH50 \leq 5CH50/mL), high titers of antinuclear antibodies (>1:640), high titers of anti-double stranded DNA IgG antibodies (92I U/mL), high titers of anti-Smith antibodies (102 U/mL) and high titers of anti-ribonucleoprotein antibodies (>500 U/mL). These data indicated a relapse of SLE, although titers of anti-cardiolipin antibodies IgG (<8 U/mL) were normal. She was admitted to our psychiatric department because of her manic symptoms. At this time, she was alert and oriented in time, place and person, but she said, "I see something like dust in the air", and grasped at empty space twice during the interview because of this dust-like elementary hallucination. She went on to say, "Everything is fun: always cleaning", in a low voice. The patient referred to herself in a form of the first person that is typically used by men. Her manic state was the most remarkable of her symptoms, but affective incontinence and radical mood swings were also observed. Her score on Young's mania rating scale was 29/60 points.⁶ Methylprednisolone pulse therapy (1000 mg for 3 days) was immediately performed on admission, followed by administration of prednisolone (50 mg/day). Aripiprazole (6 mg/day) was also started and was increased up to 24 mg/day the next day. Twenty-two days' (from day 6 to day 27) isolation and 22 days' (from day 28 to day 49) temporal isolation was required until the time her condition was better and manageable. Magnetic resonance imaging (MRI) revealed multiple white matter hyperintensities, while ¹²³I-IMP SPECT revealed hypoperfusion in the occipital area (Figure 1(a)).

Within 2 days of her admission, the patient was astonished by the sudden disappearance of her elementary hallucinations. Her manic symptoms gradually ameliorated with the normalization of her laboratory data. At approximately 50 days after admission, she was mildly depressed. Lithium (400 mg/day) was started and was increased up to 800 mg/day. At 72 days after admission, she was free of her psychiatric symptoms and was discharged from our psychiatric department. At the time of discharge, the dose of prednisolone was 30 mg/day, with the plan to decrease the dose gradually at the patient's visits to the outpatient clinic. Within 1 month of discharge, aripiprazole and lithium were discontinued. Twenty-eight days after discharge, the

multiple white matter hyperintensities revealed by MRI remained unchanged, while hypoperfusion in the occipital area revealed by ¹²³I-IMP SPECT was remarkably normalized (Figure 1(b)). The patient has been euthymic for approaching 12 months on corticosteroid treatment alone.

Discussion

Manic episodes are among the most important and common manifestations of corticosteroid-induced neuropsychiatric disorders (CIPD).^{5,7} A recent report demonstrated a case of bipolar disorder triggered by chloroquine, another drug used in the treatment of SLE.⁸ Neuropsychiatric symptoms in SLE tend to occur relatively early in the disease, with their frequency decreasing with time, and SLE is the only specific illness that has been linked to a greater risk of CIPD.⁵ Therefore, it is often difficult to distinguish CIPD from NPSLE. However, in the present case, manic symptoms occurred after the discontinuation of corticosteroid treatment, and visual hallucinations were observed simultaneously. These observations are more suggestive of NPSLE than CIPD. To our knowledge, there are only a few reports that have described mania in SLE without corticosteroid treatment. Khan *et al.* reported a case of a 32-year-old woman with SLE whose initial manifestation was mania.⁹ Alao *et al.* also reported a 15-year-old woman with SLE whose initial manifestation was mania. However, this diagnosis was confounded by the patient's strong family history of psychiatric disorders.¹⁰ The present case may be the first reported case of SLE that relapsed predominantly as mania.

In CNS-SLE with diffuse manifestations, multiple defects of cerebral blood flow are often observed in frontal and parietal areas. These perfusion defects can significantly improve to the point of total absence after effective treatment.¹¹ Hypoperfusion in the frontal cortex is not necessarily specific to the manic state associated with CNS-SLE, and has been associated with mania more generally.¹² In this patient, the defect was located in occipital rather than frontal areas. Interestingly, the amelioration of the manic symptoms and her occipital hypoperfusion coincided with the disappearance of her visual hallucinations. Broadly speaking, the occipital cortex processes vision. It is therefore possible that the visual hallucinations and occipital hypoperfusion observed in this patient might have been associated with her manic symptoms.

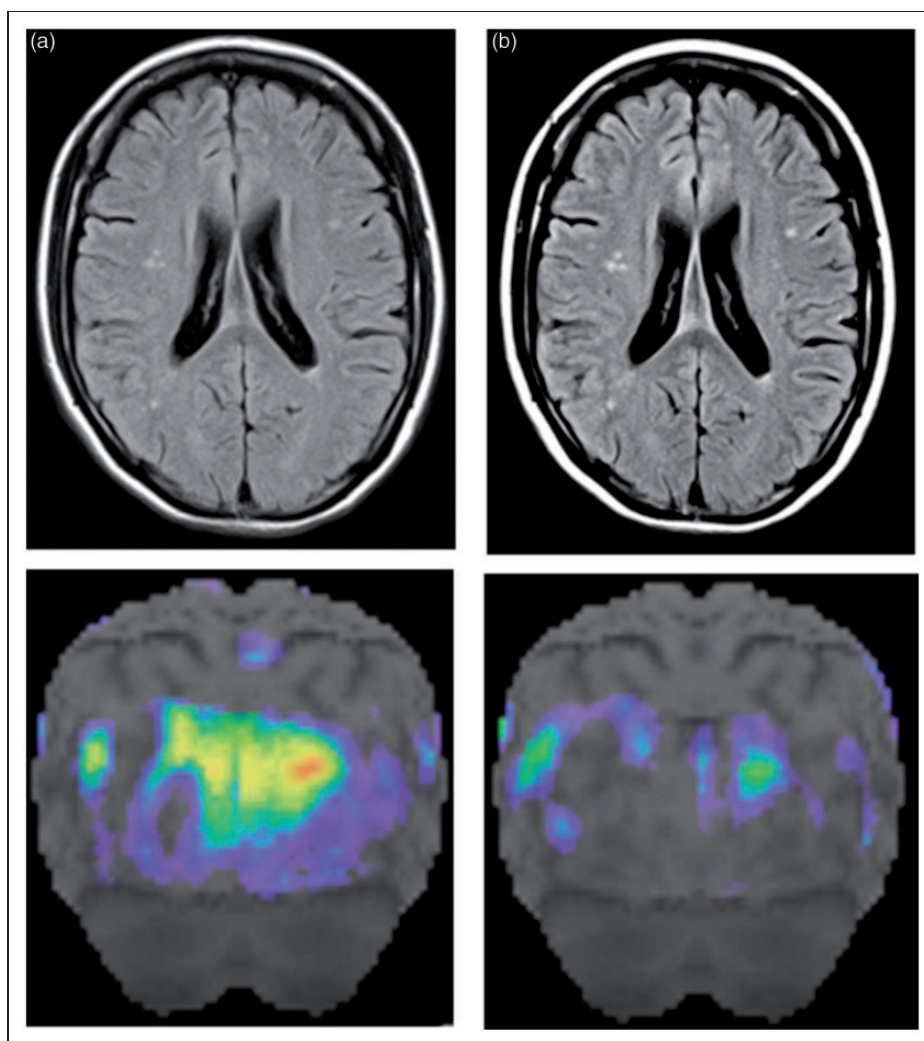


Figure 1 A fluid-attenuated inversion recovery (FLAIR) image of magnetic resonance imaging revealed multiple white matter hyperintensities, while ^{123}I -IMP single-photon emission computed tomography (SPECT) analyzed with three-dimensional stereotactic surface projection revealed hypoperfusion in the occipital area. (a) Approximately 90 days later, white matter hyperintensity revealed by a follow-up FLAIR image remained unchanged, while (b) hypoperfusion in the occipital area revealed by a follow-up ^{123}I -IMP SPECT was remarkably normalized.

Castellino and colleagues argue that there is no ‘gold standard’ for the diagnosis and follow-up of NPSLE, and suggest that coupling a morphological MRI with a functional SPECT may be more helpful in excluding NPSLE than in confirming it.^{13,14} In the present case, multiple white matter hyperintensities revealed by MRI remained unchanged, while hypoperfusion in the occipital area revealed by SPECT, which might be related to visual hallucinations, was remarkably normalized after the amelioration of psychiatric symptoms. These results may suggest the superiority of ^{123}I -IMP SPECT over MRI in follow-up, especially for monitoring disease severity and guiding treatment.¹¹

Funding

This research received no specific grant from any funding agency in the public, commercial, or not-for-profit sectors.

Conflict of interest statement

The authors have no conflicts of interest to declare.

References

- 1 Jennekens FG, Kater L. The central nervous system in systemic lupus erythematosus, pt 1: clinical syndromes: a literature investigation. *Rheumatology (Oxford)* 2002; 41: 605–618.

- 2 American College of Rheumatology Ad Hoc Committee on Neuropsychiatric Lupus Nomenclature. The American College of Rheumatology nomenclature and case definitions for neuropsychiatric lupus syndromes. *Arthritis & Rheumatism* 1999; 42: 599–608.
- 3 Bachen EA, Chesney MA, Criswell LA. Prevalence of mood and anxiety disorders in women with systemic lupus erythematosus. *Arthritis & Rheumatism* 2009; 61: 822–829.
- 4 Meszaros ZS, Perl A, Faraone SV. Psychiatric symptoms in systemic lupus erythematosus: A systematic review. *J Clin Psychiatry* 2012; 73: 993–1001.
- 5 Bhangle SD, Kramer N, Rosenstein ED. Corticosteroid-induced neuropsychiatric disorders: review and contrast with neuropsychiatric lupus. *Rheumatol Int* 2013; 33: 1923–1932.
- 6 Young RC, Biggs JT, Ziegler VE, Meyer DA. A rating scale for mania: reliability, validity and sensitivity. *Br J Psychiatry* 1978; 133: 429–435.
- 7 Nishimura K, Omori M, Sato E, Katsumata Y, Gono T, Kawaguchi Y, Harigai M, Yamanaka H, Ishigooka J. Risperidone in the treatment of corticosteroid-induced mood disorders, manic/mixed episodes, in systemic lupus erythematosus: A case series. *Psychosomatics* 2012; 53: 289–293.
- 8 Bogaczewicz J, Sobow T, Bogaczewicz A, Robak E, Bienkowski P, Sysa-Jedrzejowska A, Wozniacka A. Exacerbations of bipolar disorder triggered by chloroquine in systemic lupus erythematosus—a case report. *Lupus* 2014; 23: 193–188.
- 9 Khan S, Haddad P, Montague L, Summerton C. Systemic lupus erythematosus presenting as mania. *Acta Psychiatr Scand* 2000; 101: 406–408.
- 10 Alao AO, Chlebowski S, Chung C. Neuropsychiatric systemic lupus erythematosus presenting as bipolar I disorder with catatonic features. *Psychosomatics* 2009; 50: 543.
- 11 Zhang X, Zhu Z, Zhang F, Shu H, Li F, Dong YI. Diagnostic value of single-photon-emission computed tomography in severe central nervous system involvement of systemic lupus erythematosus: A case-control study. *Arthritis & Rheumatism* 2005; 53: 845–849.
- 12 Benabarre A, Vieta E, Martínez-Arán A, Garcia-Garcia M, Martín F, Lomeña F, Torrent C, Sánchez-Moreno J, Colom F, Reinares M, Brugue E, Valdés M. Neuropsychological disturbances and cerebral blood flow in bipolar disorder. *Australian and New Zealand Journal of Psychiatry* 2005; 39: 227–234.
- 13 Castellino G, Govani M, Trotta GF. Optimizing clinical monitoring of central nervous system involvement in SLE. *Autoimmunity Reviews* 2008; 7: 297–304.
- 14 Castellino G, Padovan M, Bortoluzzi A, Borrelli M, Feggi L, Caniatti ML, Trotta F, Govoni M. Single photon emission computed tomography and magnetic resonance imaging evaluation in SLE patients with and without neuropsychiatric involvement. *Rheumatology* 2008; 47: 319–323.