



Clinical Reasoning: An unusual case of subacute encephalopathy

Neal Parikh, MD
Alexander E. Merkler,
MD
Natalie T. Cheng, MD
Hediyeh Baradaran, MD
Halina White, MD
Dana Leifer, MD

Correspondence to
Dr. Leifer:
dal2023@med.cornell.edu

SECTION 1

A 52-year-old previously healthy man presented with 8 months of progressive cognitive decline. He complained of months of confusion, fatigue, depression, hypersomnolence, headaches, and, subsequently, urinary incontinence and unsteady gait. His family reported that he spoke of his deceased mother as if she were alive. His executive deficits progressed, leading to termination of his employment and a motor vehicle accident. He was evaluated and treated in Morocco before presenting to our institution for further care.

Mental status examination was notable for slowed mentation and dyscalculia but was otherwise normal. Motor, sensory, and deep tendon reflex examination results were normal. Cerebellar and gait examination

revealed wide-based gait and lower extremity dysmetria. Relevant laboratory evaluation revealed only a C-reactive protein of 1.79 (normal 0–0.99).

Brain MRI obtained in Morocco 2 months prior to presentation had demonstrated bilateral thalamic T2 hyperintensities and patchy enhancement in the right medial temporal lobe, midbrain, and basal ganglia. A right thalamic biopsy obtained in Morocco had revealed “inflammatory cells” without evidence of malignancy.

Questions for consideration:

1. How can thalamic injury cause encephalopathy?
2. What is the differential diagnosis for bilateral thalamic MRI abnormalities?

[GO TO SECTION 2](#)

SECTION 2

The thalamus is a major processing center for the brain that relays motor, sensory, cerebellar, as well as cognitive and limbic inputs. Information regarding cognition and arousal is processed in the mediodorsal, midline, and intralaminar thalamic nuclei. The latter

are part of the reticular activating system, which is involved in maintaining consciousness and arousal. Perturbations in these portions of the thalamus can cause confusion, depressed levels of alertness, and coma. Lesions of other structures initially affected on the patient's MRI, such as the basal ganglia and medial temporal lobe, can produce similar symptoms; however, only bilateral thalamic injury was redemonstrated on our own imaging.

The differential diagnosis for thalamic lesions is broad. Etiologies for bilateral thalamic MRI abnormalities include neoplastic (glioma or lymphoma), hereditary, metabolic and toxic (Wernicke encephalopathy, osmotic myelinolysis, pantothenate kinase deficiency, Wilson disease, liver disease, hypoxic ischemic encephalopathy, carbon monoxide poisoning), infectious (West Nile virus or other flaviviruses, Creutzfeldt-Jakob disease, toxoplasmosis), inflammatory (neuro-Behçet disease), and vascular (occlusion at the top of the basilar artery, occlusion of an artery of Percheron, cerebral venous sinus thrombosis [CVST]).¹ Clinical history, other imaging features, and laboratory analysis narrow the diagnostic possibilities.

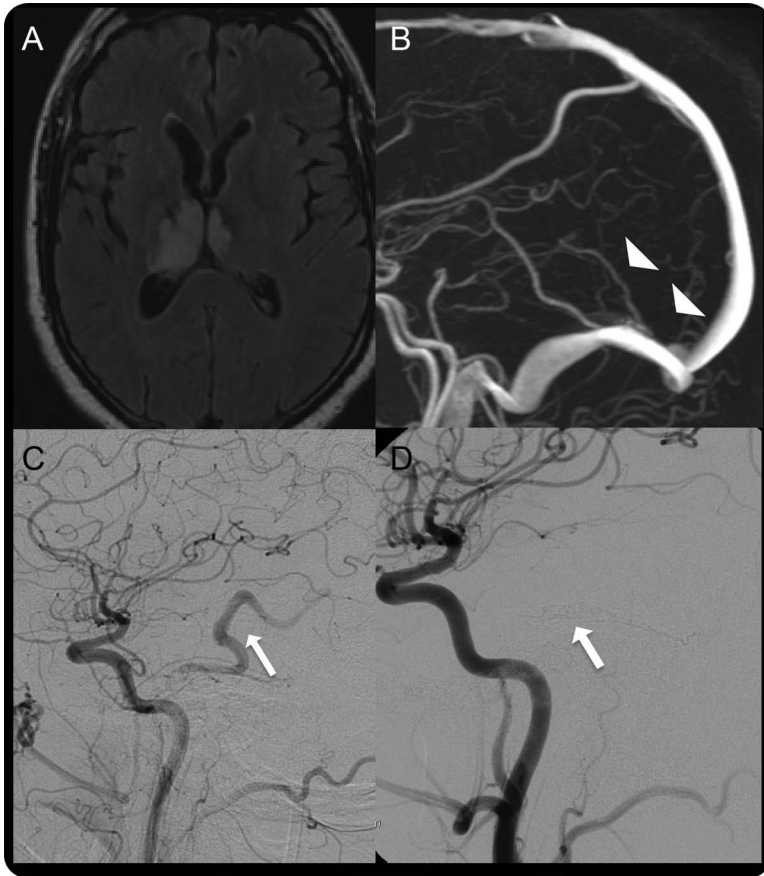
Repeat MRI revealed microhemorrhage, T2 and fluid-attenuated inversion recovery signal abnormality (figure, A), and patchy postcontrast enhancement in the bilateral thalami. Additionally, our patient had already been treated with prednisone in Morocco with subsequent worsening. Based on the bilateral midline signal abnormalities with only patchy enhancement and lack of steroid responsiveness, we suspected a vascular etiology, specifically a straight sinus venous thrombosis, rather than a vasculitic, meningoencephalitic, or neoplastic etiology. Magnetic resonance angiography results were normal; however, magnetic resonance venography showed prominent collateral veins along the left occipital lobe and nonvisualization of the internal cerebral veins, distal vein of Galen, and straight sinus (figure, B).

Questions for consideration:

1. What is the differential diagnosis for CVST?
2. What is the appropriate next step in diagnostic evaluation?

GO TO SECTION 3

Figure Pre-embolization and post-embolization neuroimaging



(A) Right greater than left fluid-attenuated inversion recovery signal hyperintensity in the thalami with patchy postcontrast enhancement (not shown) and microhemorrhage on gradient echo imaging (not shown), consistent with subacute venous infarction. (B) Arrowheads at expected sites of occluded vein of Galen and straight sinus. (C) Pre-embolization digital subtraction angiogram (DSA) image after injection of the left common carotid artery demonstrates early filling of a venous varix (arrow) in the left perimesencephalic cistern, primarily supplied by small branches of the left middle meningeal artery, consistent with a dural arteriovenous fistula (dAVF). (D) Post-embolization DSA image after embolization of the dAVF with onyx with no evidence of residual vessel filling.

SECTION 3

CVST is observed most commonly in patients with acquired or inherited hypercoagulability, high estrogen states, cancer, and, uncommonly, head and neck infections.² In our patient, nonvisualization of the straight sinus was seen along with prominent collateral veins and thalamic ischemia or infarction. These findings suggested a dural arteriovenous fistula (dAVF) and prompted angiography.³

Angiography confirmed straight sinus thrombosis and revealed early filling of a venous varix supplied by small branches of the left middle meningeal artery and dural branches of the left posterior cerebral artery, which were consistent with a dAVF (figure, C).

Questions for consideration:

1. What interventions are indicated?
2. What is the pathophysiologic relationship among thalamic injury, CVST, and dAVF?

GO TO SECTION 4

SECTION 4

We elected to treat the patient by embolization of the dAVF and with anticoagulation for venous thrombosis. Angiography demonstrated complete obliteration of the dAVF at the end of embolization (figure, D). MRI was repeated 1 month later and showed nearly complete resolution of the thalamic T2 hyperintensities. There was no change in the neurologic examination at that time; however, persistent CVST was seen. The patient was subsequently lost to follow-up.

DISCUSSION Dural arteriovenous fistulas are rare vascular malformations in which meningeal arteries drain directly into dural venous sinuses, meningeal veins, or subarachnoid veins.³ This type of vascular malformation is associated with various neurologic symptoms and deficits including tinnitus, dementia, seizures, parkinsonism, and cerebellar symptoms.³ When seen with cortical venous drainage, they have a 30% hemorrhage risk.⁴ A retrospective analysis also found a 4.5% incidence of ischemic stroke in a cohort of 134 patients with dAVF; 5 of the 6 patients with strokes had venous infarctions.⁵ Ischemic stroke was nonsignificantly more common in patients who had CVST in addition to dAVF. Although CVST has been described in the setting of dAVF, there are no known reports of this combination as a cause of bilateral thalamic injury and encephalopathy.

Accumulating evidence suggests that this is a unique vascular mechanism by which thalamic compromise results in subacute encephalopathy or rapidly progressive dementia. Three case reports describe patients with similar presentations who were found to have dAVF with thalamic involvement.^{6–8} Our patient uniquely presented with concomitant CVST. In contrast to our patient, these 3 patients experienced significant clinical improvement after treatment. Perhaps the persistence of the CVST in our patient was responsible for the lack of improvement.

The co-occurrence of dAVF and CVST in our patient prompts consideration of the theoretical pathophysiologic relationship between these 2 processes and thalamic injury.^{5,9} Ischemia associated with a dAVF, for example of the bilateral thalami, may result from the development of venous reflux. Sinus thrombosis results in venous hypertension, which may promote the formation of the dAVF by opening dural arteriovenous shunts and produce ischemia secondary to venous reflux and relative stasis. Alternatively, turbulence in the dAVF may promote thrombus formation.

With obliteration of the dAVF, flow decreases, venous reflux is eliminated, and perfusion improves. Apparent diffusion coefficient changes (and T2 hyperintensities and contrast enhancement) may then reverse.¹⁰

In other words, injury because of edema or ischemia may be reversible. Indeed, such radiographic improvement correlates with clinical improvement in some cases.^{6–8}

Ischemia in the context of a dAVF and CVST is therefore a potentially treatable condition. Appropriate treatment is primarily endovascular embolization of the dAVF, which resulted in reversal of T2 signal abnormalities in our patient, along with anticoagulation for the CVST. Alternative treatments for dAVF include surgical intervention and stereotactic radiosurgery.³

Since thalamic injury attributed to both dAVF and CVST may be reversible, and the 2 processes require distinct treatments, it is imperative to consider CVST with associated dAVF in the differential diagnosis for bilateral thalamic MRI abnormalities.

AUTHOR CONTRIBUTIONS

Neal Parikh conceived and designed the study and drafted and revised the manuscript for intellectual content. Alexander E. Merkler conceived and designed the study and drafted and revised the manuscript for intellectual content. Natalie T. Cheng drafted and revised the manuscript for intellectual content. Hediye Baradaran drafted and revised the manuscript for intellectual content. Halina White conceived and designed the study and drafted and revised the manuscript for intellectual content. Dana Leifer conceived and designed the study and drafted and revised the manuscript for intellectual content.

STUDY FUNDING

No targeted funding reported.

DISCLOSURE

N. Parikh, A. Merkler, N. Cheng, H. Baradaran, and H. White report no disclosures. D. Leifer is supported by NIH grant R01 HL089521. He also has received research support from NIH grants NS058728 and NS044378. Go to Neurology.org for full disclosures.

REFERENCES

1. Hegde AN, Mohan S, Lath N, Lim CC. Differential diagnosis for bilateral abnormalities of the basal ganglia and thalamus. *Radiographics* 2011;31:5–30.
2. Saposnik G, Barinagarrementeria F, Brown RD, et al. Diagnosis and management of cerebral venous thrombosis: a statement for healthcare professionals from the American Heart Association/American Stroke Association. *Stroke* 2011;42:1158–1192.
3. Gandhi D, Chen J, Pearl M, Huang J, Gemmete JJ, Kathuria S. Intracranial dural arteriovenous fistulas: classification, imaging findings, and treatment. *AJNR Am J Neuroradiol* 2012;33:1007–1013.
4. Gross BA, Du R. The natural history of cerebral dural arteriovenous fistulae. *Neurosurgery* 2012;71:594–602; discussion 602–593.
5. Yeh SJ, Tsai LK, Liu HM, Yip PK, Jeng JS. Ischemic stroke in patients with intracranial dural arteriovenous fistulas. *J Formos Med Assoc* 2011;110:299–305.
6. Santillan A, Safdieh JE, Gobin YP, Patsalides A. Neurological picture: bilateral thalamic venous hypertension caused by a tentorial dural arteriovenous fistula: endovascular treatment. *J Neurol Neurosurg Psychiatry* 2011;82:749–750.
7. Morparia N, Miller G, Rabinstein A, Lanzino G, Kumar N. Cognitive decline and hypersomnolence: thalamic manifestations of a tentorial dural arteriovenous fistula (dAVF). *Neurocrit Care* 2012;17:429–433.
8. van Munster CE, van den Berg R, Weinstein HC. A dural fistula as a treatable cause of cognitive impairment. *Neurohospitalist* 2014;4:111–112.

9. Tsai LK, Jeng JS, Liu HM, Wang HJ, Yip PK. Intracranial dural arteriovenous fistulas with or without cerebral sinus thrombosis: analysis of 69 patients. *J Neurol Neurosurg Psychiatry* 2004;75:1639–1641.
10. Sato K, Shimizu H, Fujimura M, Inoue T, Matsumoto Y, Tominaga T. Compromise of brain tissue caused by cortical venous reflux of intracranial dural arteriovenous fistulas: assessment with diffusion-weighted magnetic resonance imaging. *Stroke* 2011;42:998–1003.