

# Profuse Unilateral Hyperhidrosis Induced by Urinary Retention in a Stroke Patient

Jia-Chi Wang, MD,\* † Rai-Chi Chan, MD,\* † Po-Yao Chang, MD,\*  
and Tsui-Fen Yang, MD\* †

**Introduction:** The diagnosis of urinary retention in stroke patients is challenging because their symptoms may be subtle, or go unnoticed. Furthermore, patients suffering from aphasia or impaired cognition often have difficulties communicating urination problems, leading to their urinary retention being overlooked.

**Case Report:** We report a 53-year-old man with bilateral pontine hemorrhage resulting in incomplete locked-in syndrome. During the patient's hospital course, he developed 3 episodes of rapid onset of profuse unilateral hyperhidrosis. All 3 episodes were found to be induced by an overly distended bladder and each time the unilateral hyperhidrosis resolved promptly after bladder drainage.

**Conclusions:** This case provides the first description of unilateral hyperhidrosis as a manifestation of urinary retention in a stroke patient. It is important for clinicians to recognize this condition so that appropriate management can be implemented in time to prevent potential detrusor injury and renal impairment caused by bladder overdistension.

**Key Words:** stroke, hyperhidrosis, autonomic dysfunction, urinary retention

(*The Neurologist* 2015;19:82–84)

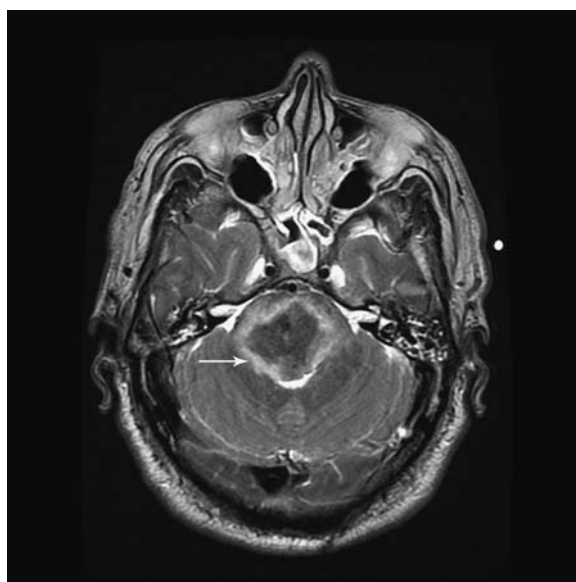
Voiding dysfunction is common in stroke patients. After an initial period of detrusor areflexia, stroke patients frequently have bladder incontinence resulting from a lack of cortical inhibition to void. This leads to detrusor hyperreflexia, with an increase in the frequency of urination and urge incontinence. Persistent detrusor hyporeflexia and areflexia may also occur after stroke, causing urinary retention and sometimes overflow incontinence. Pontine lesions, cerebellar lesions, and hemorrhagic stroke may be associated with detrusor areflexia and urinary retention.<sup>1,2</sup> Impaired consciousness, perceptual deficits, limited mobility, use of anticholinergics, and preexisting bladder outlet obstruction are further potential contributory factors to urinary retention in stroke patients.

The most common symptoms and signs of urinary retention are inability to void, suprapubic pain, or a palpable bladder. However, the diagnosis of urinary retention in stroke patients is challenging because their symptoms are usually less obvious than the general population. Furthermore, patients

who have aphasia or impaired cognition have difficulties communicating their urination problems, leading to their urinary retention being overlooked. In clinical practice, any sign related to urinary retention needs to be identified promptly so that appropriate treatment can be instituted. In this case report we describe a patient with pontine hemorrhage resulting in incomplete locked-in syndrome, who presented with episodes of profuse unilateral hyperhidrosis caused by an overly distended bladder.

## CASE REPORT

This 53-year-old man, with a medical history of hypertension and gouty arthritis, suffered from sudden onset of headache, dizziness, and slurred speech followed by a change in consciousness on January 1, 2011. Brain magnetic resonance imaging revealed a bilateral pontine hemorrhage with a maximum diameter of 3.7 cm and local mass effect to the fourth ventricle (Fig. 1). The patient was mechanically ventilated to support respiration. Percutaneous tracheostomy was performed after 2 weeks, and the patient was weaned off mechanical ventilation 2 weeks later. The consciousness level of the patient improved gradually. He was admitted to our rehabilitation department 2 months after the onset of stroke. At that time, the Glasgow Coma Scale score was E4VTM6, and he was able to follow simple commands to open and close his eyes. He had spastic paresis of the left upper limb and bilateral lower limbs, with bilateral positive Babinski and Hoffman signs. However, the motor function of his right hand was found to be only mildly impaired, with muscle strength of the right hand being 4/5 according to the Medical Research Council Grade. Bilateral facial



**FIGURE 1.** Axial T2-weighted brain magnetic resonance imaging revealed a bilateral pontine hemorrhage (white arrow) with a maximum diameter of 3.7 cm.

From the \*Department of Physical Medicine & Rehabilitation, Taipei Veterans General Hospital; and †Department of Physical Medicine & Rehabilitation, National Yang Ming University, Taipei, Taiwan.

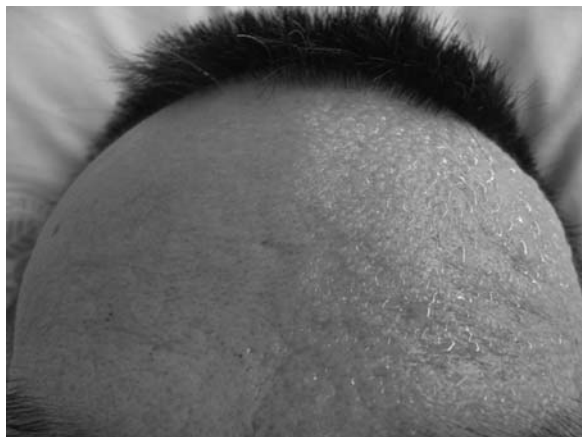The authors declare no conflict of interest.

Reprints: Tsui-Fen Yang, MD, Department of Physical Medicine and Rehabilitation, Taipei Veterans General Hospital, No. 201, Section 2, Shih-Pai Road, Taipei 112, Taiwan. E-mail: tfyang@vghtpe.gov.tw.

Copyright © 2015 Wolters Kluwer Health, Inc. All rights reserved.

ISSN: 1074-7931/15/1903-0082

DOI: 10.1097/NRL.0000000000000012



**FIGURE 2.** Profuse unilateral hyperhidrosis with a clear distinction along the midline of the face.

pareisis (right side was more severe than left side) and bilateral vertical nystagmus with conjugate gaze deviation to the left were noted. The right pupil was slightly smaller (2 mm) than the left (3 mm). No ptosis was evident, and the sweating function of the right side of the body was normal. During the course of hospitalization in our rehabilitation ward, we removed the Foley catheter and initiated an intermittent catheterization program for bladder training. Rapid onset of profuse hyperhidrosis over the left side of the face, neck, and upper trunk, as well as the left shoulder and left hand during bed rest was observed. The hyperhidrosis was most obvious on the face and hand, with a clear line of distinction along the midline of his face (Fig. 2). There were large drops of sweat dripping from these parts, and the pillow and clothes on his left side were wet due to the profuse sweating.

No obvious change in temperature, blood pressure, or heart rate was noted during the episode. Physical examination was inconclusive due to the patient's poor communicative function. There were no pressure sores, and defecation was normal. Laboratory work-up, including complete blood cell count, cardiac enzyme, and thyroid function, was unremarkable. A bladder scan indicated approximately 500 mL of urine in the bladder. A Foley catheter was inserted immediately and 530 mL of urine was drained. The unilateral hyperhidrosis resolved promptly after bladder drainage. Two more episodes of hyperhidrosis were subsequently observed, when the patient's bladder was distended to 500 mL. These episodes were also quickly resolved after bladder drainage. Because volitional voiding was not observed in the course of intermittent catheterization, continuous catheter drainage was used instead and no further episodes of hyperhidrosis occurred.

## DISCUSSION

The diagnosis of urinary retention in stroke patients can be challenging, and the condition can be easily missed in patients with a reduced consciousness level, impaired cognition, and/or communication difficulties. It is important for clinicians to palpate the suprapubic area and be aware of any signs that may indicate urinary retention. Cases of leg swelling caused by external compression of the iliac vein due to bladder distension and sympathetic storming (presenting with hypertension, tachycardia, tachypnea, hyperthermia, and diaphoresis) related to urinary retention have been described.<sup>3,4</sup> To the best of our knowledge, isolated unilateral hyperhidrosis as a symptom of urinary retention in stroke patients has not been previously reported.

Excessive sweating is a common manifestation of autonomic dysreflexia in patients with spinal cord injury. Any noxious stimulus occurring below the injury level of the spinal cord can trigger an episode of autonomic dysreflexia. However, excessive sweating is uncommon in stroke patients. Labar et al<sup>5</sup> reported profuse unilateral hyperhidrosis only in 3 of 633 stroke

cases. Kim et al<sup>6</sup> observed the phenomenon of hyperhidrosis in only 5 of 350 patients with acute stroke. Korpelainen et al<sup>7</sup> reported visually apparent profuse hemihidrosis after a heat stimulus in 4 out of 53 patients, whereas the majority of his patients required the evaporimetric method to demonstrate hyperhidrosis. The hyperhidrosis typically involved the contralateral face, neck, and arm, being most obvious on the forehead and hand, and was typically transient, lasting for a few months. However, long-lasting hyperhidrosis has been described in a stroke patient.<sup>8</sup> The clinical phenomenon of hyperhidrosis in stroke patients is indicative of an autonomic dysfunction. However, unlike autonomic dysreflexia in spinal cord injury, there are no other concurrent signs of autonomic dysfunction.

Lesions of the cerebral hemispheres,<sup>5,6</sup> hypothalamus,<sup>9-11</sup> pons,<sup>8,12,13</sup> and lateral medulla,<sup>6,14</sup> resulting in contralateral hyperhidrosis have been reported. The neurophysiological mechanism and clinical significance of unilateral hyperhidrosis associated with a cerebral lesion are not well known. Most authors attributed contralateral hyperhidrosis to lesions of a crossed inhibitory hypothalamospinal sympathetic pathway, which controls sweating of the contralateral face and body. This pathway might originate in the cortex, possibly the operculum, traverse the ipsilateral hypothalamus and brain stem, crossing at the spinal level, and make terminal connections with the contralateral thoracic spinal cord. Our case presented with a bilateral pontine lesion; however, only unilateral left-side hyperhidrosis was noted. This may be explained by the asymmetry of the hemorrhage, involving the right sympathoinhibitory pathway while sparing the left side, thus resulting in the left-sided hyperhidrosis.

Review of the currently available literature shows that episodes of unilateral hyperhidrosis in stroke patients are elicited by heat exposure, effort, or stress.<sup>8,14</sup> In our patient, urinary retention was the instigating factor. In clinical practice, we should be aware that unilateral hyperhidrosis, despite its rarity, can be a presenting symptom of bladder distension in stroke patients. If the patient is managed with continuous bladder catheterization, the catheter should be checked for kinks or obstructions, and irrigated or renewed if necessary. If the patient is managed with intermittent catheterization, the bladder should be scanned or palpated to detect bladder distension upon presentation of symptoms. If the bladder is distended, catheterization should be carried out immediately to drain the bladder. Clinicians should be aware that unilateral hyperhidrosis can be the cardinal sign of a noxious stimulus, such as urinary retention, in stroke patients with impaired sensation and cognition. As soon as unilateral hyperhidrosis is observed in a stroke patient, the patient should be examined and treated for any noxious stimulus that might be triggering the hyperhidrosis.

We report this rare case to make clinicians aware that hyperhidrosis is a potential manifestation of urinary retention in a specific group of stroke patients. It is important for clinicians to recognize this condition because of the potential for detrusor malfunction and renal impairment caused by bladder overdistension, if it were to go undetected. Further studies are necessary to identify the precise neuroanatomic structures involved in sympathetic control of hidrosis and to disclose the pathophysiology of unilateral hyperhidrosis in stroke patients.

## REFERENCES

1. Burney TL, Senapati M, Desai S, et al. Acute cerebrovascular accident and lower urinary tract dysfunction: a prospective correlation of the site of brain injury with urodynamic findings. *J Urol.* 1996;156:1748-1750.

2. Sakakibara R, Hattori T, Yasuda K, et al. Micturitional disturbance and the pontine tegmental lesion: urodynamic and MRI analyses of vascular cases. *J Neurol Sci*. 1996;141:105–110.
3. Siu G, Marino M, Desai A, et al. Sympathetic storming in a patient with intracranial basal ganglia hemorrhage. *Am J Phys Med Rehabil*. 2011;90:243–246.
4. Im S, Lim SH, Chun HJ, et al. Leg edema with deep venous thrombosis-like symptoms as an unusual complication of occult bladder distension and right May-Thurner syndrome in a stroke patient: a case report. *Arch Phys Med Rehabil*. 2009;90:886–890.
5. Labar DR, Mohr JP, Nichols FT III, et al. Unilateral hyperhidrosis after cerebral infarction. *Neurology*. 1988;38:1679–1682.
6. Kim BS, Kim YI, Lee KS. Contralateral hyperhidrosis after cerebral infarction. Clinicoanatomic correlations in five cases. *Stroke*. 1995;26:896–899.
7. Korpelainen JT, Sotaniemi KA, Myllylä VV. Hyperhidrosis as a reflection of autonomic failure in patients with acute hemispherical brain infarction. An evaporimetric study. *Stroke*. 1992;23:1271–1275.
8. Pellecchia MT, Criscuolo C, De Joanna G, et al. Pure unilateral hyperhidrosis after pontine infarct. *Neurology*. 2003;61:1305.
9. Sakashita Y, Kakuta K, Kakuma K, et al. Unilateral persistent hyperhidrosis after ischemic stroke. *Rinsho Shinkeigaku*. 1992;32:454–456.
10. Bassetti C, Staikov IN. Hemiplegia vegetativa alterna (ipsilateral Horner's syndrome and contralateral hemihyperhidrosis) following proximal posterior cerebral artery occlusion. *Stroke*. 1995;26:702–704.
11. Smith CD. A hypothalamic stroke producing recurrent hemihyperhidrosis. *Neurology*. 2001;56:1394–1396.
12. Rey A, Marti-Vilalta JL, Abellan MT. Contralateral hyperhidrosis secondary to the pontine infarct. *Rev Neurol*. 1996;24:459–460.
13. Sato K, Nitta E. Pontine hemorrhage presenting with Foville syndrome and transient contralateral hyperhidrosis. *Rinsho Shinkeigaku*. 2000;40:271–273.
14. Rousseaux M, Hurtevent JF, Benaim C, et al. Late contralateral hyperhidrosis in lateral medullary infarcts. *Stroke*. 1996;27:991–995.