

CASE REPORT

Improvement of sudden bilateral hearing loss after vertebral artery stenting

Ji Hwa Kim,¹ Kyung Jin Roh,² Sang Hyun Suh,^{3,4} Kyung-Yul Lee^{1,4}¹Department of Neurology, Gangnam Severance Hospital, Yonsei University College of Medicine, Seoul, Republic of Korea²Department of Otorhinolaryngology, Gangnam Severance Hospital, Yonsei University College of Medicine, Seoul, Republic of Korea³Department of Radiology, Gangnam Severance Hospital, Yonsei University College of Medicine, Seoul, Republic of Korea⁴Severance Institute for Vascular and Metabolic Research, Yonsei University, Seoul, Republic of Korea⁵Department of Neurology, Gangnam Severance Hospital and Severance Institute for Vascular and Metabolic Research, Seoul, Republic of Korea**Correspondence to**

Dr Kyung-Yul Lee, Department of Neurology, Gangnam Severance Hospital, Yonsei University College of Medicine, 211 Eonjuro, Gangnam-gu, Seoul, 135-720, Korea; kylee@yuhs.ac

Received 4 January 2015

Revised 27 January 2015

Accepted 28 January 2015

SUMMARY

Bilateral deafness is a rare but possible symptom of vertebrobasilar ischemia. We report a case of sudden bilateral sensorineural hearing loss caused by bilateral vertebral artery (VA) occlusion which dramatically improved after stenting. A 54-year-old man was admitted with sudden onset of bilateral deafness, vertigo, and drowsy mental status. Brain diffusion-weighted MRI showed acute infarction involving both the posterior inferior cerebellar artery and left posterior cerebral artery territory. Cerebral angiography showed bilateral distal VA occlusion, and emergency intracranial stenting was performed in the left VA. After reperfusion therapy his symptoms gradually improved, including hearing impairment. Endovascular stenting may be helpful in a patient with sudden deafness caused by bilateral VA occlusion.

BACKGROUND

Bilateral deafness is a rare but possible symptom of vertebrobasilar artery occlusion (VBO) due to ischemia of the cochlear nerve and auditory tracts in the brainstem.^{1–2} The hearing impairment tends to precede other brainstem signs such as decreased consciousness, dysarthria, ataxia, weakness, and sensory deficits, or can be the only symptom of VBO.^{3–4} Thus, hearing impairment caused by VBO is difficult to detect early, despite its grave prognosis.^{2–3} In addition, few cases of hearing recovery have been reported in these patients.^{1–3} We present a case of sudden bilateral sensorineural hearing loss (SSNHL) caused by bilateral VBO which improved after endovascular stenting.

CASE PRESENTATION

A 54-year-old man was admitted to the emergency room because of sudden bilateral deafness and vertigo. He had no symptoms until the night before admission and noticed the hearing impairment when he awoke. He arrived at the hospital 7 h after symptom onset because of symptom worsening and vertigo. The patient had a history of hypertension and smoking, but no other known illnesses. Initial neurological examination revealed bilateral deafness and right beating horizontal nystagmus without any motor weakness or sensory impairment; drowsy mentality and dysarthria developed after admission.

Laboratory studies were normal, except an elevated fasting glucose (124 mg/dL), HbA1c (7.5%), and low-density lipoprotein cholesterol (164 mg/dL). ECG showed no abnormalities. Initial brain CT angiography revealed bilateral distal vertebral artery (VA)

occlusion. Diffusion-weighted MRI showed diffusion restriction in the bilateral posterior inferior cerebellar artery (PICA) and left posterior cerebral artery territories and perfusion MRI showed decreased cerebral blood flow as well as delayed mean transit time and time to peak in the bilateral cerebellum, brainstem, and left occipital lobe (figure 1). Cerebral angiography showed bilateral VA occlusion involving the origin of the PICA (figures 2A–C). The basilar artery (BA) was barely filled with collateral circulation from the anterior spinal artery, and the right PICA was visualised by BA collaterals but the right anterior inferior cerebellar artery (AICA) was not visualised (figures 2B, C). The left AICA–PICA common trunk was also supplied by BA collaterals. Atherosclerotic arterial occlusion was suspected due to vascular risk factors and diffuse atherosclerotic changes in other cerebral arteries. There was no evidence of arterial dissection on cerebral angiography.

TREATMENT

Endovascular treatment was performed immediately due to worsening neurological signs. A 6 Fr guiding catheter (Envoy; Codman Neurovascular, Raynham, Massachusetts, USA) was introduced into the left VA via the right femoral artery. A microcatheter (pre-shaped J Prowler select plus, Codman Neurovascular) was guided carefully into the occluded segment of the left VA using a 0.014 inch microwire (Synchro-2; Stryker, Fremont, California, USA) and was advanced through the BA. Due to long segment occlusion of the left VA (>30 mm), an Enterprise stent (38 mm, Codman Neurovascular) was deployed in the occluded segment of the left VA and 0.5 mg of intra-arterial tirofiban was administered to prevent reocclusion. Control angiography showed a patent stent lumen without thrombosis, and the antegrade flow was restored immediately in the right AICA, PICA, and left AICA–PICA common trunk (figure 2D). Daily dual antiplatelet agents (aspirin 100 mg and clopidogrel 75 mg) were started immediately after the procedure.

OUTCOME AND FOLLOW-UP

Immediately after stent implantation the patient's neurologic symptoms improved, except bilateral deafness. Pure tone audiography was performed 2 days after admission, which showed severe sensory neural hearing loss at 72 dB in the right ear and 75 dB in the left. However, his hearing improved gradually and he could understand voice when he was discharged 5 days after admission. The patient exhibited no hearing impairment or other neurologic deficits 1 month after discharge.



CrossMark

To cite: Kim JH, Roh KJ, Suh SH, et al. *BMJ Case Rep* Published online: [please include Day Month Year] doi:10.1136/bcr-2014-011595

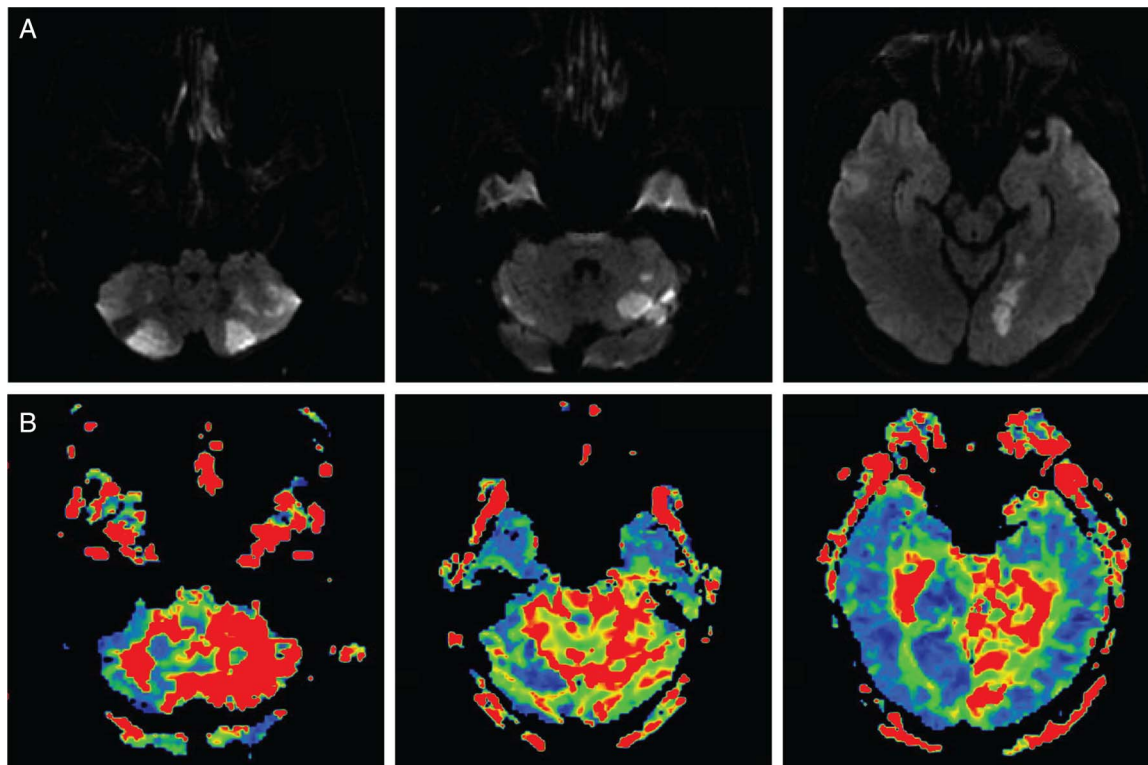


Figure 1 (A) Initial brain diffusion-weighted MRI shows diffusion restriction in both the posterior inferior cerebellar artery and left posterior cerebral artery territory. (B) Perfusion MRI shows delay of mean transit time in the bilateral cerebellum, brainstem, and left occipital lobe.

DISCUSSION

Although unilateral SSNHL is common with a relatively good prognosis, bilateral SSNHL is rare, representing less than 5% of cases, and typically has a poor prognosis with high morbidity and mortality.⁵ It is associated with serious systemic conditions such as toxins, neoplasms, vascular events, autoimmune diseases, infections, and iatrogenic causes.⁵ Some authors report that SSNHL can be an early warning sign of impending vertebrobasilar ischemic stroke^{2 4 6} in which the incidence of hearing impairment is 1.2–14.3%.^{1 4} Sauvaget *et al*¹ described some features of hearing impairment associated with VBO, including bilateral occurrence, associated occipital or posterior nuchal pain, and delayed neurological deficits.

Regarding vascular causes, there were reports of ischemic stroke in the AICA territory as well as the PICA and other brainstem territories, most of which are associated with VBO.⁴ The internal auditory artery (IAA) is a main feeder to the inner ear

and it usually originates from the AICA or less frequently from the PICA or BA. The IAA divides into two main branches, the common cochlear artery and the anterior vestibular artery. Even brief periods of ischemia can cause inner ear damage because the IAA and its subdivisions are end arteries with minimal collaterals from other major arteries; this anatomical characteristic explains the vulnerability of the cochlea to ischemia.⁷

There is no standard treatment for SSNHL with VBO. Some case reports suggested that early recognition and immediate anticoagulation therapy were associated with a relatively good prognosis in hearing loss associated with vertebrobasilar ischemia.¹ However, in the case of bilateral VA occlusion or BA occlusion, it was associated with high morbidity and mortality, even after treatment with anticoagulation or antiplatelet agents^{1 2} or thrombolysis using intravenous tissue plasminogen activator or intra-arterial urokinase.³ Endovascular treatment is often the best treatment option in symptomatic VBO patients

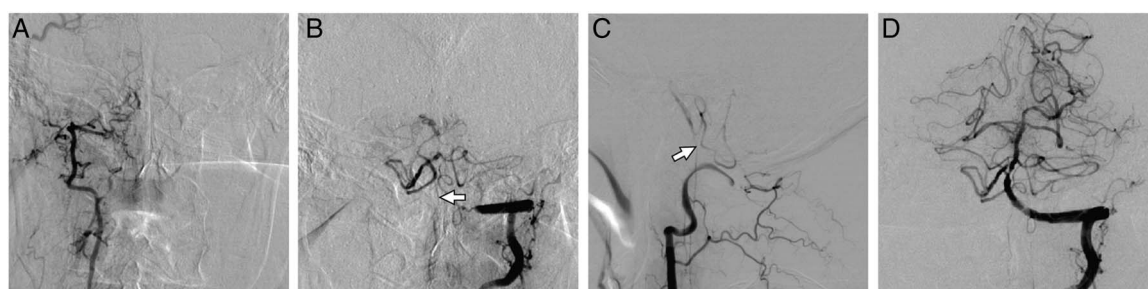


Figure 2 (A–C) Cerebral angiography before endovascular treatment. (A) Right vertebral angiogram in anteroposterior view and left vertebral angiogram in (B) anteroposterior view and (C) lateral view show the occluded bilateral vertebral artery proximal to the posterior inferior cerebellar artery (PICA). Retrograde upward flow through the anterior spinal artery (white arrow) supplies tenuous blood flow to the basilar artery. (D) Delayed angiography after endovascular stenting in the anteroposterior view shows a patent stent lumen without thrombosis. The right anterior inferior cerebellar artery (AICA) is visualized and the right PICA and left AICA–PICA common trunk flows are improved.

and has been reported to be effective and safe.^{8 9} However, there have been no reports of improvement in bilateral SSNHL after VA stenting. This might be due to the rarity of bilateral SSNHL and its late detection because of underestimated hearing symptoms or delayed recognition of ischemia-associated hearing impairment. Although we used antiplatelet agents in addition to endovascular treatment, we speculated that recanalisation via endovascular treatment was the main reason for the rapid and dramatic improvement observed. Importantly, this report is the first case that suggests reversibility of hearing loss after recanalisation. Because endovascular treatment is available only in acute stages of stroke, clinicians should be aware of the possibility of VBO in cases of sudden bilateral hearing impairment, even when brainstem or cerebellar signs are not clear.

Learning points

- ▶ Sudden sensorineural hearing loss may be an early warning sign of vertebrobasilar artery occlusion (VBO). However, in cases where other neurologic symptoms are absent, it is easy to overlook.
- ▶ Accurate neurologic examination and immediate brain imaging may be helpful to distinguish VBO from other causes of sudden hearing loss.
- ▶ This case shows that endovascular treatment is helpful in patients with VBO who present with hearing loss as an early symptom.

Contributors Study concept and design: JHK, KJR, SHS. Acquisition, analysis, or interpretation of data: All authors. Drafting of the manuscript: JHK. Critical revision of the manuscript for important intellectual content: SHS, K-YL. Study supervision: K-YL. K-YL had full access to all of the data in the study and takes responsibility for the integrity of the data and the accuracy of the data analysis.

Competing interests None.

Patient consent Obtained.

Provenance and peer review Not commissioned; externally peer reviewed.

REFERENCES

- 1 Sauvaget E, Kici S, Petelle B, *et al*. Vertebrobasilar occlusive disorders presenting as sudden sensorineural hearing loss. *Laryngoscope* 2004; 114:327–32.
- 2 Huang MH, Huang CC, Ryu SJ, *et al*. Sudden bilateral hearing impairment in vertebrobasilar occlusive disease. *Stroke* 1993;24:132–7.
- 3 Toyoda K, Hirano T, Kumai Y, *et al*. Bilateral deafness as a prodromal symptom of basilar artery occlusion. *J Neurol Sci* 2002;193:147–50.
- 4 Lee H, Baloh RW. Sudden deafness in vertebrobasilar ischemia: clinical features, vascular topographical patterns and long-term outcome. *J Neurol Sci* 2005;228:99–104.
- 5 Sara SA, Teh BM, Friedland P. Bilateral sudden sensorineural hearing loss: review. *J Laryngol Otol* 2014;128(Suppl 1):S8–15.
- 6 Lin HC, Chao PZ, Lee HC. Sudden sensorineural hearing loss increases the risk of stroke: a 5-year follow-up study. *Stroke* 2008;39:2744–8.
- 7 Kim JS, Lopez I, DiPatre PL, *et al*. Internal auditory artery infarction: clinicopathologic correlation. *Neurology* 1999;52:40–4.
- 8 Gawlitza M, Fritzsche D, Quaschling U, *et al*. Mechanical thrombectomy in patients with acute vertebrobasilar occlusion using the Trevo device: a single-centre experience. *Neuroradiology* 2014;56:977–83.
- 9 Brekenfeld C, Schroth G, Mattle HP, *et al*. Stent placement in acute cerebral artery occlusion: use of a self-expandable intracranial stent for acute stroke treatment. *Stroke* 2009;40:847–52.

Copyright 2015 BMJ Publishing Group. All rights reserved. For permission to reuse any of this content visit <http://group.bmj.com/group/rights-licensing/permissions>.

BMJ Case Report Fellows may re-use this article for personal use and teaching without any further permission.

Become a Fellow of BMJ Case Reports today and you can:

- ▶ Submit as many cases as you like
- ▶ Enjoy fast sympathetic peer review and rapid publication of accepted articles
- ▶ Access all the published articles
- ▶ Re-use any of the published material for personal use and teaching without further permission

For information on Institutional Fellowships contact consortiasales@bmjgroup.com

Visit casereports.bmj.com for more articles like this and to become a Fellow