

Fanconi anemia associated with moyamoya disease in Saudi Arabia

Zakaria M. Al-Hawsawi, MBBS, MD, Mohamed A. Al-Zaid, MBBS, Ashwaq I. Barnawi, MBBS, MD, Saadeddine M. Yassine, MBBS, MD.

ABSTRACT

نستعرض هنا حالة مريضة سعودية عمرها 10 سنوات أدخلت المستشفى وهي تعاني من شلل نصفي في الجانب الأيمن من الجسم كما سبق إصابتها بشلل نصفي في الجانب الأيسر وتحسنت تلقائياً. وبعد إجراء الفحوصات المخبرية وأشعة الرنين المغناطيسي للمخ اتضح أنها تعاني من مرض فانكوني أنيميا مصاحب لمرض مويامويا. وهذه المصاحبة نادرة جداً فقد تم تسجيل حالات محدودة جداً على مستوى العالم. لذا نوصي باكتشاف ونشر مثل هذه الحالات النادرة من المملكة العربية السعودية والعالم العربي، كما ينصح بتحديد أسباب المرض و عمل التحليل الجيني لمثل هذه الظاهرة النادرة.

We report a 10-year-old Saudi girl who has Fanconi anemia (FA) and was admitted due to acute hemiplegia, of the right side. She had a previous attack of left side hemiplegia that resolved spontaneously. The brain magnetic resonance angiography showed a cerebrovascular pattern of moyamoya disease. She underwent partially matched related donor stem cell transplantation (SCT), but unfortunately died 3 months later with post SCT complications. The association of moyamoya disease with FA is uncommon, and is rarely reported in the literature. Although this condition may be acquired, it is considered a truly congenital defect in FA, and to identify the etiology of this association furthermore genetic mutation analysis is needed.

Saudi Med J 2015; Vol. 36 (2): 233-235
doi: 10.15537/smj.2015.2.9978

From the Department of Pediatrics (Al-Hawsawi, Al-Zaid, Barnawi), and the Department of Radiology (Yassine), Madinah Maternity and Children's Hospital, Madinah Al-Munawara, Kingdom of Saudi Arabia.

Received 3rd August 2014. Accepted 16th November 2014.

Address correspondence and reprint request to: Dr. Zakaria M. Al-Hawsawi, Department of Pediatrics, Madinah Maternity and Children's Hospital, Taiba University, PO Box 6205, Madinah Al-Munawara, Kingdom of Saudi Arabia. Fax: +966 (14) 8640927. E-mail: zalbawsawi@yahoo.com

Fanconi anemia (FA) is an autosomal recessive condition, first described in 1927 by the Swiss pediatrician Guido Fanconi.¹ It is a phenotypically heterogeneous disorder characterized by pancytopenia, congenital malformation, and predisposition to malignancy.² Fanconi anemia cells are characterized by chromosomal hypersensitivity to cross linking agents such as diepoxybutane, which is often used as the diagnostic test.³ Fanconi anemia is a very rare heterogeneous condition clinically, with a wide variety of abnormalities. Skeletal abnormalities are most common anomalies, followed by skin pigmentation, and short stature. Central nervous system defects are a rare anomaly, including hydrocephalus, absent septum pellucidum, and neural tube defects.⁴ Moyamoya disease is rarely associated with FA, hence we are reporting a case of FA in Saudi child presenting with recurrent alternating hemiplegia. Our objective in presenting this particular case is to highlight this rare association.

Case Report. A 10-year-old Saudi girl was referred from a local hospital with right side weakness, which was of sudden onset, started in the right lower limb, and 2 days later involved the right upper limb. She had a history of 4 months of pallor, and 2 weeks skin bruising prior to the onset. It was not associated with facial weakness, headache, fever, convulsion, visual disturbance, or loss of consciousness, and no history of preceding head trauma. She had a similar attack of left side weakness 5 months earlier, which resolved spontaneously without medical evaluation at a local hospital. Her mother noticed that she is shorter than her other siblings. Her immunization was completed, and her physical, and cognitive development was normal. Her parents were first degree cousin, and had 6 other siblings. Her physical examination revealed a well looking girl, with pallor and skin bruising on lower limbs, with 2x3cm scattered café au lait spots on the back, and inguinal region. Her weight was 25 kg, below 5th centile for her age, and her height was 118 cm, below the 3rd centile for her age. She had right hemiparesis, there were no hepatosplenomegaly, and the examination of other systems were unremarkable.

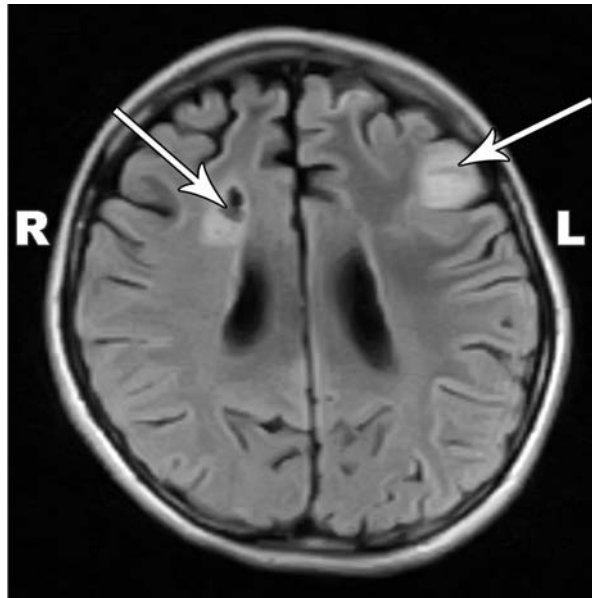


Figure 1 - Magnetic resonance imaging (flair image) showing left frontal focal area of acute ischemic infarction (left arrow), and right parietal periventricular white matter old infarction (right arrow).

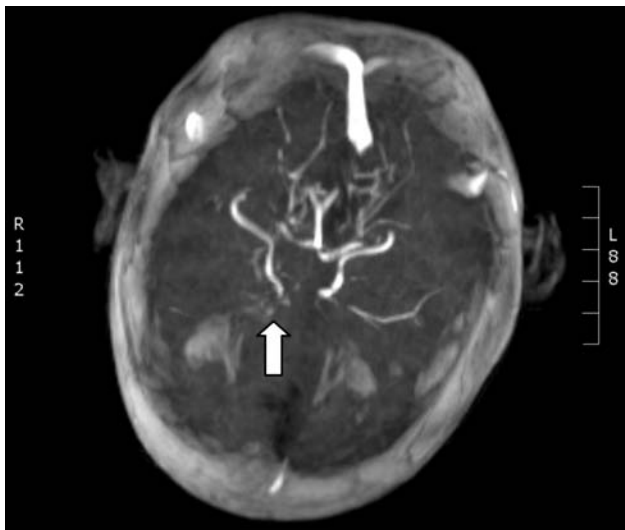


Figure 2 - Magnetic resonance angiography (axial image) showing poor arterial circulation, and narrow distal internal carotid artery with puff of smoke sign (arrow) on right side suggestive of moyamoya disease.

Her investigations showed white blood cell count $2600/\text{mm}^3$ (normal value [NV] - $4000-10500/\text{mm}^3$), neutrophil count $500/\text{mm}^3$ (NV - $3000-5000/\text{mm}^3$), hemoglobin 6.3 g/dl (NV - $12.5-16.1 \text{ g/dl}$), and platelet count $33000/\text{mm}^3$ (NV - $150-400/\text{mm}^3$). Her liver and renal profile were within normal limits. Bone marrow

aspiration showed hypocellular marrow. Chromosomal analysis confirmed chromosomal breakage. Brain MRI showed a left frontal focal area of acute ischemic infarction, and an area of right parietal periventricular white matter old infarction, with multiple small white matter lacunar infarcts (Figure 1). The brain MRA showed poor arterial circulation, and a narrow distal internal carotid artery with puff of smoke sign (arrow) on the right side suggestive of moyamoya disease (Figure 2). The diagnosis was confirmed as FA, with association of moyamoya disease, presenting with right hemiplegia. She was managed initially by supportive care in the form of a blood transfusion, and physical therapy for hemiplegia, later she underwent partial match related donor stem cell transplantation (SCT), but unfortunately, she died after 3 months from post SCT complications.

Discussion. Moyamoya is rarely associated with FA. On literature review, we found 3 reported patients with FA, and moyamoya disease. The first case was reported in 1980, a 10-year-old Arab boy, presented with recurrent left hemiplegia.⁵ The second and third cases were reported in 1995, and presented with strokes.⁶ Moyamoya disease is observed in multiple conditions including bacterial meningitis, tuberculosis, head trauma, neurocutaneous syndrome, atherosclerotic disease, sickle cell disease, and mitochondrial disease.⁷ It results from chronic occlusion of the distal carotid artery resulting in collateral vessels network and angiographic appearance. Various hypothesis have been implicated in the etiology of moyamoya in FA. Recurrent bleeding around the carotid siphon resulting in progressive narrowing of the carotid artery is one possible etiology. Considering FA is associated with multiple congenital anomalies, narrowing of the carotid artery resulting in moyamoya disease is truly a congenital defect, and this was supported by a reported case of FA associated with internal carotid agenesis,⁸ and Fanconi's anemia and a cerebral anomaly in the form of hypoplasia of the cerebral artery.⁹

Our case presented with recurrent episodes of hemiplegia similar to the first case.⁵ Moyamoya disease frequently presents with recurrent hemiplegia, and sometimes with alternating hemiplegia as in our case. We observed this presentation with sickle anemia patients and moyamoya disease following strokes. Stem cell transplantation is the treatment of choice for FA. Our patient underwent SCT from a partially matched related donor, however, she died due to post SCT complications, mainly infection. As FA is highly

prevalent in Saudi Arabia, mainly due to a high rate of consanguinity, and inherited marriage as a result, more than 120 allogeneic SCT have been performed in Saudi patients with FA over the last 30 years at King Faisal Specialist Hospital and Research Center, Riyadh, Kingdom of Saudi Arabia.¹⁰

In conclusion, this is a very rare association between 2 rare conditions, and reporting such cases from Saudi Arabia, and other Arab countries with high consanguinity is very important. To identify the etiology of this association, further genetic mutation analysis for FA is needed to investigate any disease associated mutation between the 2 conditions.

Acknowledgment. We would like to express our thanks to Dr. Ali Al-Mohammadi, General Director of the Madinah Maternity & Children's Hospital for allowing us to report this case, and to Dr. Mohamed Abdulkarim, Consultant Radiologist, for his critical review of the radiological figures. Our thanks also to Mr. Elsadig Ahmed for his excellent secretarial work.

References

1. Fanconi G. Familiare, infantile, perniziosaartige Anämie (pernizioses Blutbild und Konstitution). [Familial Infantile Pernicious-like Anemia (Pernicious Blood Picture and Constitution)]. *Jahrbuch für Kinderheilkunde* 1927; 117: 257-280.
2. Butturini A, Gale RP, Verlander PC, Adler-Brecher B, Gillio AP, Auerbach AD. Hematologic abnormalities in Fanconi anemia: an International Fanconi Anemia Registry study. *Blood* 1994; 84: 1650-1655.
3. Auerbach AD, Rogatko A, Schroeder-Kurth TM. International Fanconi Anemia Registry: relation of clinical symptoms to diepoxybutane sensitivity. *Blood* 1989; 73: 391-396.
4. De Kerviler E, Guermazi A, Zagdanski AM, Gluckman E, Frija J. The clinical and radiological features of Fanconi's anaemia. *Clin Radiol* 2000; 55: 340-345.
5. Cohen N, Bernat M, Simon J. Moyamoya and Fanconi anemia. *Pediatrics* 1980; 65: 804-805.
6. Pavlakis SG, Verlander PC, Gould RJ, Strimling BC, Auerbach AD. Fanconi anemia and moyamoya: evidence for an association. *Neurology* 1995; 45: 998-1000.
7. Pavlakis SG, Gould RJ, Zito JL. Stroke in children. *Adv Pediatr* 1991; 38: 151-179.
8. Rocha CM, Brucki SM, Rocha MS. Internal carotid agenesis and Fanconi's anemia: a rare association. *Pediatr Radiol* 2002; 32: 460-461.
9. Mahato MP, Sharma DB, Shukla R. Fanconi's anaemia and cerebrovascular anomaly. *BMJ Case Rep* 2011; 2011.
10. Ayas M, Al-Seraihi A, El-Solh H, Al-Ahmari A, Khairy A, Aldali A, et al. The Saudi experience in fludarabine-based conditioning regimens in patients with Fanconi anemia undergoing stem cell transplantation: excellent outcome in recipients of matched related stem cells but not in recipients of unrelated cord blood stem cells. *Biol Blood Marrow Transplant* 2012; 18: 627-632.

Ethical Consent

All manuscripts reporting the results of experimental investigations involving human subjects should include a statement confirming that informed consent was obtained from each subject or subject's guardian, after receiving approval of the experimental protocol by a local human ethics committee, or institutional review board. When reporting experiments on animals, authors should indicate whether the institutional and national guide for the care and use of laboratory animals was followed.