

# Nonconvulsive Partial Status Epilepticus Mimicking Recurrent Infarction Revealed by Diffusion-weighted and Arterial Spin Labeling Perfusion Magnetic Resonance Images

Yuka Kanazawa, MD,\* Takato Morioka, MD, PhD,† Shuji Arakawa, MD, PhD,\*  
Yoshihiko Furuta, MD,\* Asako Nakanishi, MD,‡ and Takanari Kitazono, MD, PhD§

---

“Non-convulsive” partial status epilepticus (SE) is an important pathologic condition that should be differentiated from cerebral infarction. Herein, we reported 2 patients who had partial SE associated with old infarction in the right parietal lobe. Each patient had 2 episodes of left hemiparesis and hemisensory disturbance without convulsion. On diffusion-weighted magnetic resonance images (DW-MRI), a hyperintense lesion was noted in the cortex around the old infarction lesion, and recurrent infarction was suspected. Although electroencephalography (EEG) failed to reveal ictal discharges or interictal paroxysmal activities in 3 of 4 episodes, perfusion images with arterial spin labeling (ASL) clearly demonstrated ictal hyperperfusion in the area corresponding to the cortical hyperintense lesion on DW-MRI. After appropriate anticonvulsant treatment based on the diagnosis of partial SE, clinical symptoms were completely improved. These data stress the importance of cortical hyperintensity on DW-MRI and ictal ASL hyperperfusion, even when SE cannot be determined from EEG. **Key Words:** Stroke mimics—ictal hyperperfusion—nonconvulsive status epilepticus—diffusion-weighted image—arterial spin labeling.

© 2015 by National Stroke Association

---

Epilepsy is the most common disorder that can mimic signs of stroke.<sup>1</sup> Although “convulsive” status epilepticus (SE) is easily recognized, inhibitory seizures such as “non-convulsive” prolonged partial epilepsy and partial SE are difficult to differentiate from stroke.<sup>2</sup> In acute stroke, diffusion-weighted magnetic resonance images

(MRI) (DW-MRI) and perfusion MRI (PI) are typically used, although recent studies demonstrated that these techniques provide information in the peri-ictal phase in epilepsy patients.<sup>3-5</sup> In SE, the epileptogenic cortex is in an electrophysiologically extreme state, and the activated cortex exhibits increased glucose and oxygen usage, thereby causing compensatory regional hyperperfusion. Arterial spin labeling (ASL) is a noninvasive and repeatable PI technique, which uses magnetically labeled blood water as an endogenous tracer.<sup>6</sup> Recent reports have described the appearance of “ictal hyperperfusion” with ASL.<sup>6-10</sup> When the hyperperfusion is no longer sufficient to supply the hyperactive cortical area, pathophysiologic changes leading to cytotoxic edema in epileptic cortical neurons can occur, which appear as an abnormal high signal in the cortical lamina (cortical hyperintensity) on DW-MRI.<sup>3,7,11-15</sup> These MRI findings of low apparent diffusion coefficient and high signals on DW-MRI in SE resemble those of acute ischemic stroke, indicating changes attributable to both cytotoxic and vasogenic edema.<sup>4,7</sup> Such ictal changes on ASL and

---

From the \*Department of Cerebrovascular Disease, Kyushu Rosai Hospital, Kitakyushu; †Department of Neurosurgery Kyushu Rosai Hospital, Kitakyushu; ‡Department of Radiology, Kyushu Rosai Hospital, Kitakyushu; and §Department of Medicine and Clinical Science, Graduate School of Medical Sciences, Kyushu University, Fukuoka, Japan.

Received July 28, 2014; revision received September 18, 2014; accepted September 21, 2014.

The study received no funding or support.

Address correspondence to Yuka Kanazawa, MD, Department of Cerebrovascular Disease, Kyushu Rosai Hospital, 1-1 Sonokitamachi, Kokuraminami-ku, Kitakyushu, Fukuoka 800-0296, Japan. E-mail: [yuka8850@gmail.com](mailto:yuka8850@gmail.com).

1052-3057/\$ - see front matter

© 2015 by National Stroke Association

<http://dx.doi.org/10.1016/j.jstrokecerebrovasdis.2014.09.026>

DW-MRI were reversible in most cases.<sup>5,7</sup> In the present study, using serial MRI including DW-MRI and ASL and electroencephalography (EEG) recording, we examined 2 patients with nonconvulsive partial SE clinically resembling recurrent infarction around the old infarction.

## Methods

### *Magnetic Resonance Image*

Brain MRI with routine protocols and PI were performed using a 3-T magnetic resonance unit (Signa HDxt 3.0T, version 23; GE Healthcare, Milwaukee, WI). Routine protocols included axial diffusion-weighted echo planar sequences (b value = 1500 seconds/mm<sup>2</sup>; repetition time (TR)/echo time (TE), 6000/min), T1 fluid-attenuated inversion recovery (T1-FLAIR) sequences (TR/TE/TI, 2050/16.1/AUTO), and T2-weighted fast spin-echo sequences (TR/TE, 4400/100) and T2-FLAIR sequence (TR/TE/TI, 9000/140/AUTO).

ASL was prepared using 3-dimensional, spiral, fast spin-echo sequence with background suppression for perfusion imaging covering the entire brain. A pulsed continuous scheme was employed. Other acquisition parameters were as follows: 4 arms with 1004 points in each spiral arm, phase encoding in the z direction = 32, section thickness = 4 mm, TR = 4728(AUTO) seconds, postlabel wait = 1.525 seconds, and number of excitations = 3.

### *Electroencephalography*

Routine EEG recordings were obtained from an 18-channel digital EEG machine (Neurofax; Nihon-Kohden, Tokyo, Japan) with electrode placement according to the International EEG 10-20 system. The EEG recordings were performed for at least 30 minutes for each patient in resting conditions.

## Results

### *Case 1*

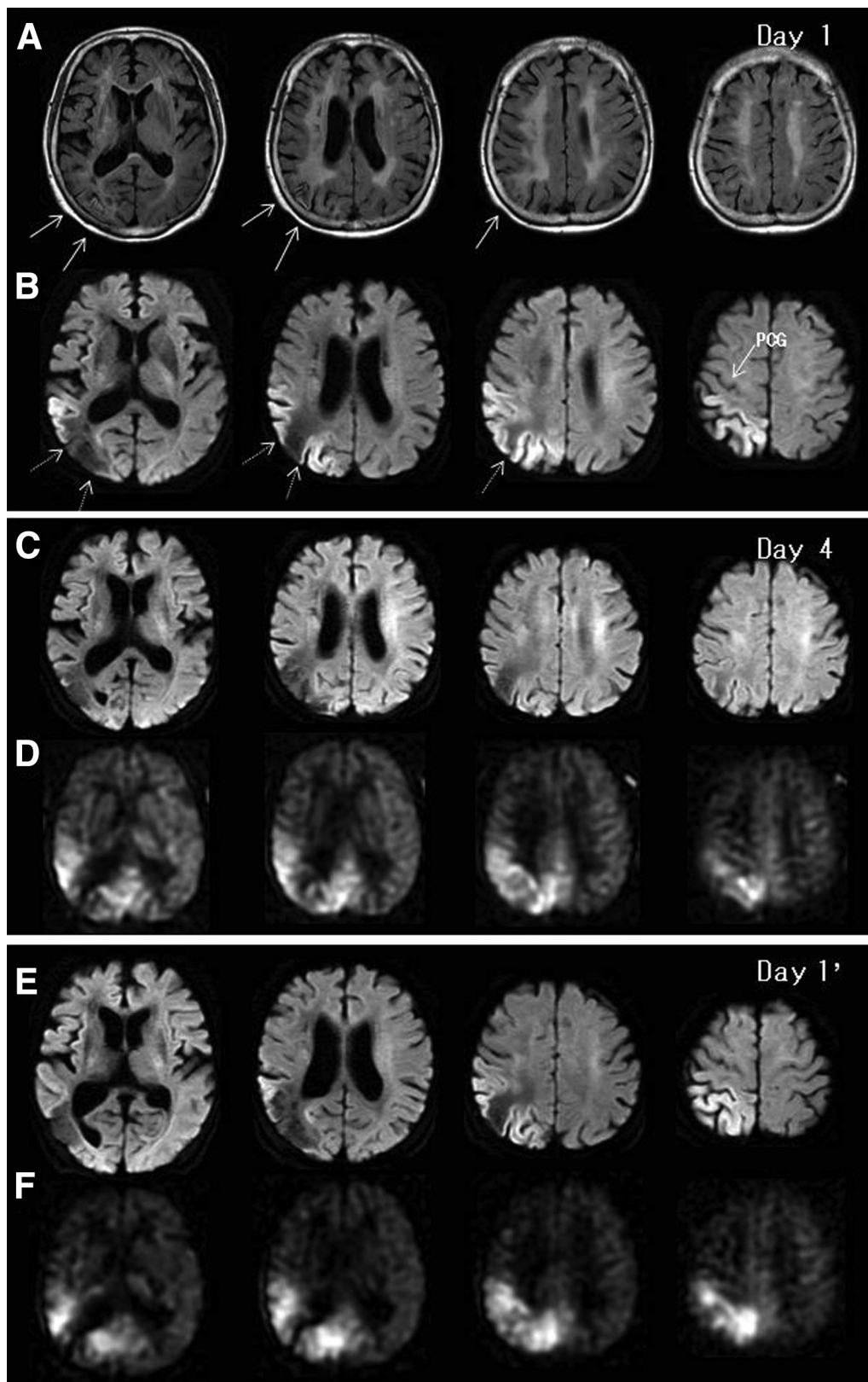
A 74-year-old female developed left hemiparesis and was admitted to us. She was alert on arrival (day 1). She had left hemiparesis and sensory disturbance in the left extremities, although convulsive seizures were not apparent. Emergency MRI with FLAIR revealed multiple old infarctions in the right parietal lobe and deep white matter on the both side (Fig 1, A). The cortex of the old infarction area in the right parietal lobe exhibited cortical laminar necrosis. On DW-MRIs, a hyperintense lesion was noted in the cortex around the old infarction site in the right parietal lobe (Fig 1, B). The precentral gyrus was not involved in this cortical hyperintensity. The tentative diagnosis was recurrent infarction around the old right parietal infarction, and an antithrombin agent (argatroban hydrate) and a free radical scavenger

(edaravone) were administered intravenously. The left hemiparesis and hemisensory disturbance were gradually improved, and DW-MRI on day 4 demonstrated dramatic disappearance of cortical hyperintensity in the right parietal lobe (Fig 1, C). However, ASL clearly showed hyperperfusion in the corresponding area to that of the cortical hyperintensity on DW-MRI of day 1 (Fig 1, D). Diagnosis of symptomatic partial epilepsy was made and intravenous phenytoin followed by oral carbamazepine was administered. On day 5, she completely recovered from left hemiparesis and sensory disturbance, and EEG demonstrated intermittent focal slow wave on the right centroparieto-occipital region (Fig 2, A).

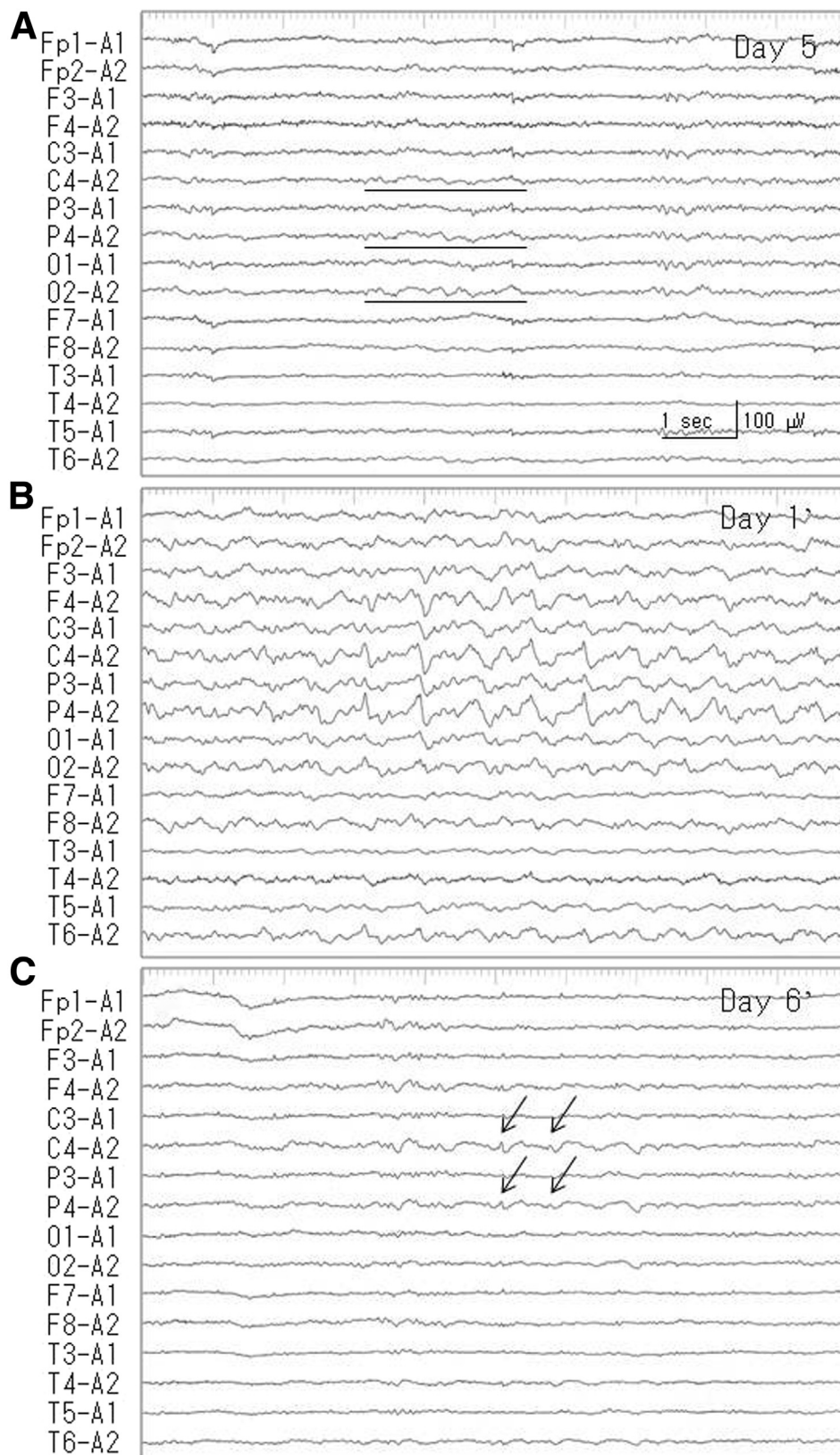
Unfortunately, the patient chose to discontinue carbamazepine treatment when she was transferred to the orthopedic department. Ten months later, she again developed left hemiparesis and hemisensory disturbance (day 1', day 1 of the second episode). On DW-MRIs, the cortical hyperintense lesion was again noted around the old infarction in the right parietal lobe (Fig 1, E). ASL clearly showed hyperperfusion in the corresponding area to that of the cortical hyperintensity on DW-MRI (Fig 1, F). These DW-MRI and ASL findings were quite similar to those at the first episode. Thus, intravenous fosphenytoin followed by oral carbamazepine was administered. Although EEG failed to reveal ictal discharges, frequent interictal paroxysmal activities were noted on the right centroparietal region (Fig 1, B; P4 and C4), which was identical to the area of cortical hyperintensity on DW-MRI and hyperperfusion on ASL. On day 2', she completely recovered from left hemiparesis and sensory disturbance, and EEG of day 6' demonstrated occasional low-amplitude paroxysmal activities in the right centroparietal region (Fig 2, C). With monotherapy of carbamazepine, she was free from epilepsy during the 2 years following her second episode. The cortical hyperintensity on DW-MRI was transient, and subsequent T2 prolonged lesion was not demonstrated on the follow-up images.

### *Case 2*

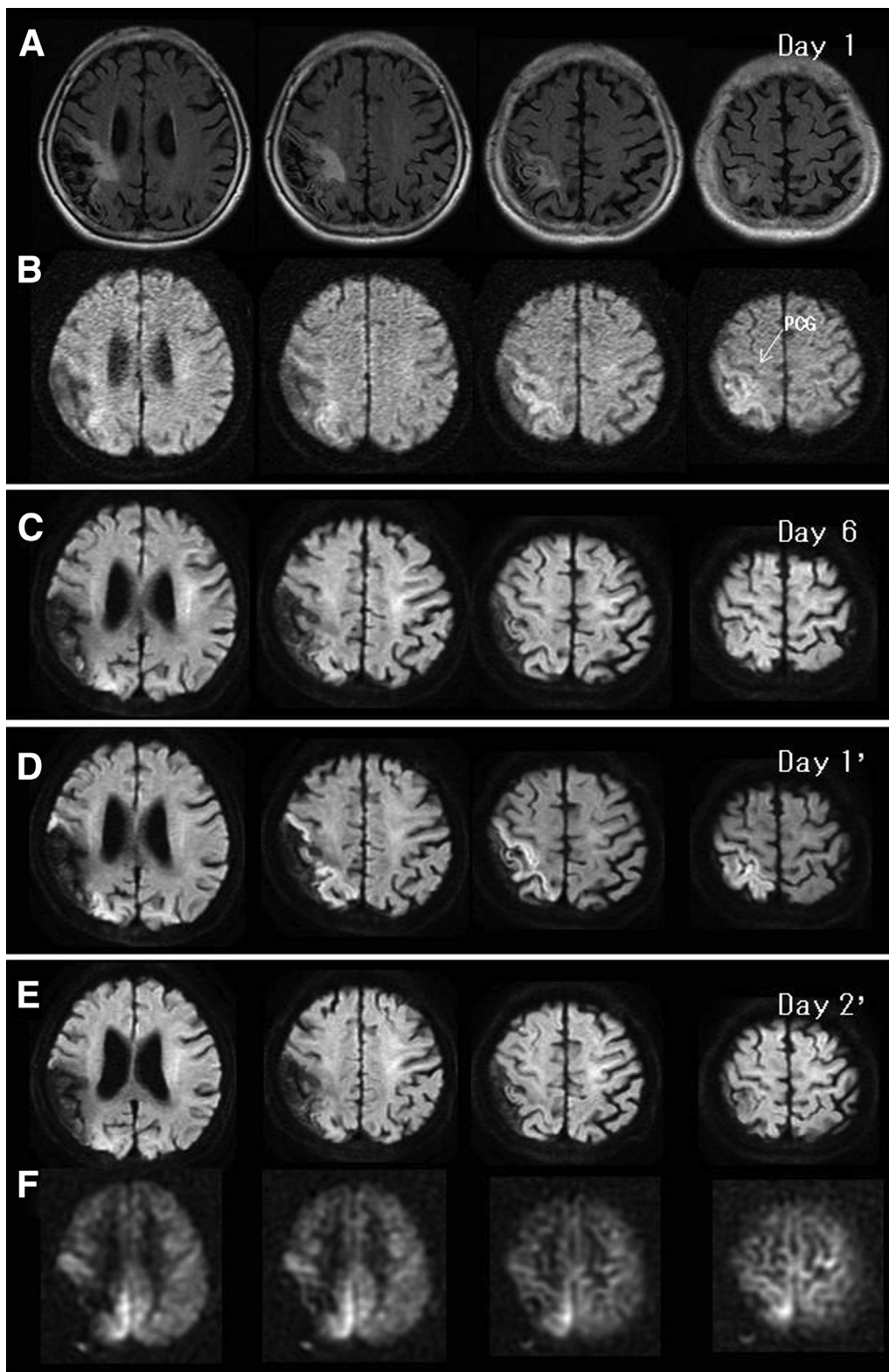
A 74-year-old female with a past history of infarction in the right parietal lobe developed left hemiparesis and sensory disturbance (day 1). She was alert on admission. She had left hemiparesis and sensory disturbance in the left extremities and dressing apraxia, although convulsive seizures were not apparent. FLAIR revealed old infarctions in the right parietal lobe (Fig 3, A). Perilesional gliosis was also noted. On DW-MRI, a gyriform cortical hyperintense lesion was noted around the old infarction in the right parietal lobe (Fig 3, B). The precentral gyrus was not involved. Her abnormal neurological findings were gradually improved. Although epilepsy was highly suspected, antiepileptic drug was not administered as EEG failed to reveal paroxysmal discharges (Fig 4, A).



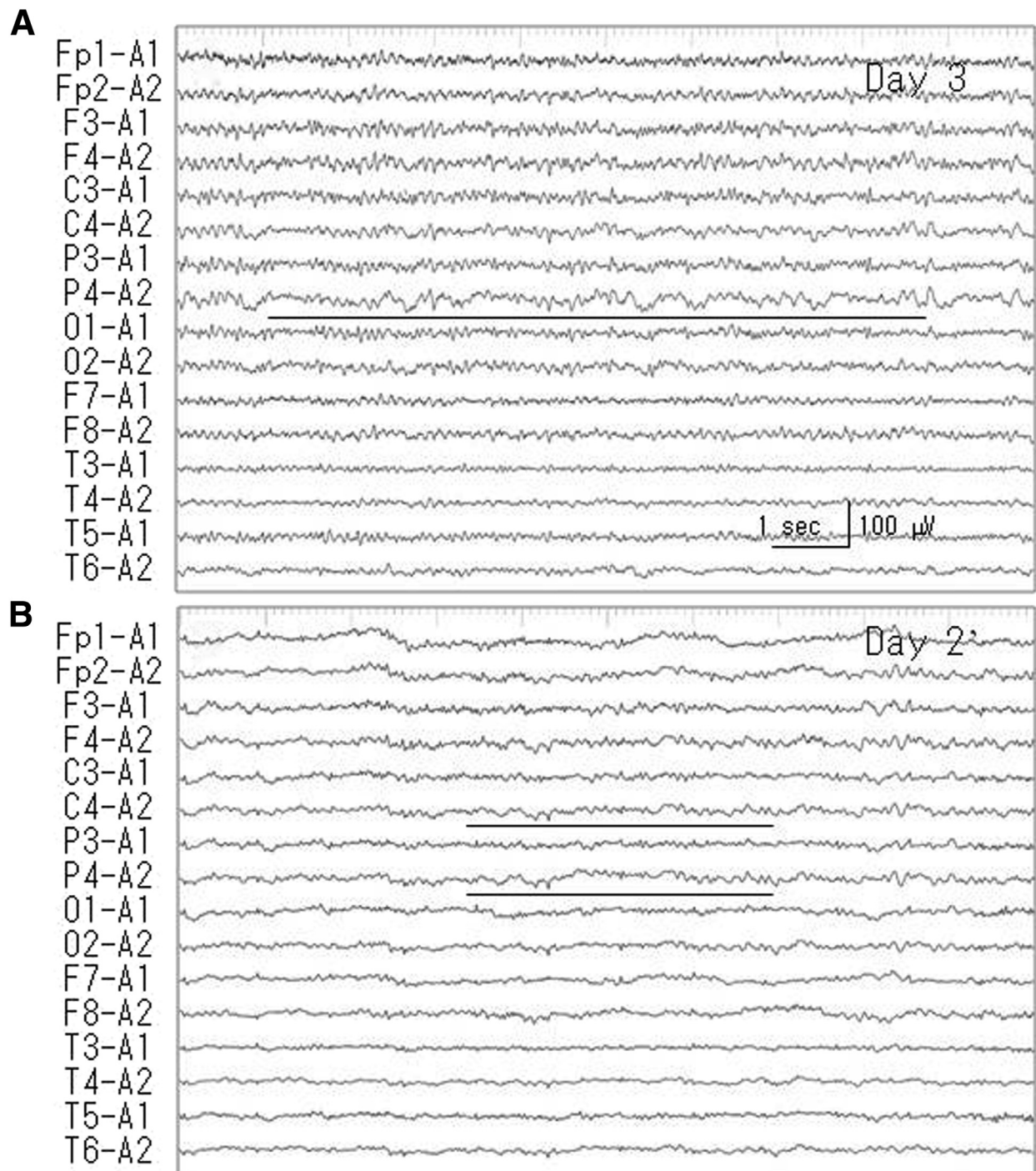
**Figure 1.** (A) Magnetic resonance images (MRI) with fluid-attenuated inversion recovery sequence (FLAIR) on admission (day 1) demonstrated an old infarction as cortical laminar necrosis in the right parietal lobe (solid arrows). Multiple cerebral infarctions were also noted in the bilateral white matter. (B) Diffusion-weighted MRI (DW-MRI) demonstrated gyriform cortical hyperintensity around the old infarction (dotted arrows). The precentral gyrus was not involved with cortical hyperintensity. (C) DW-MRI on day 4 indicated that the cortical hyperintensity had almost disappeared. (D) Perfusion images with arterial spin labeling (ASL) on day 4 showed hyperperfusion in the right parietal lobe that corresponds to the area of cortical hyperintensity on DW-MRI of day 1. (E) On DW-MRIs at the onset (day 1') of the second episode (10 months after the first episode), cortical hyperintensity lesion was noted around the old infarction in the right parietal lobe. (F) ASL clearly showed hyperperfusion in the corresponding area to that of cortical hyperintensity on DW-MRI.



**Figure 2.** Case 1. (A) Electroencephalogram (EEG) on day 5 showed intermittent focal slow waves on the right centroparieto-occipital region (black lines). (B) EEG on day 1 failed to reveal ictal discharges, whereas frequent interictal paroxysmal activities were noted on the right centroparietal region (P4 and C4 of International EEG 10-20 System), which is identical to the area of cortical hyperintensity on DW-MRI and hyperperfusion on ASL. (C) EEG on day 6 revealed occasional small-amplitude paroxysmal activities on the right centroparietal region (arrows).



**Figure 3.** Case 2. (A) Fluid-attenuated inversion recovery sequence of day 2 revealed old infarctions in the right parietal lobe. Perilesional gliosis was also noted. (B) On DW-MRI, a gyriform cortical hyperintense lesion was noted around the old infarction in the right parietal lobe. The precentral gyrus was not involved with the cortical hyperintensity. (C) DW-MRI on day 6 demonstrated a dramatic disappearance of cortical hyperintensity in the right parietal lobe. (D) On DW-MRI at the onset (Day 1') of second episode (4 months after the first episode), a cortical hyperintense lesion was noted around the old infarction in the right parietal lobe. (E) On DW-MRI of day 2' the cortical hyperintensity had disappeared, whereas ASL still depicted hyperperfusion in the area corresponding to that of cortical hyperintensity on DW-MRI of day 1'.



**Figure 4.** Case 2. (A) Electroencephalogram (EEG) of day 3 failed to reveal paroxysmal discharges. Predominantly continuous slow wave activities were noted in the right parietal region (black line). (B) EEG of day 2' showed focal slow waves on the right centroparietal region (black lines).

Predominant continuous slow wave activities were noted on the right parietal region. DW-MRI on day 6 demonstrated dramatic disappearance of cortical hyperintensity in the right parietal lobe (Fig 3, C).

Four months later, she developed left hemiparesis and sensory disturbance again. On DW-MRI on day 1' (day 1 of the second episode), cortical hyperintensity lesion was noted around the old infarction in the right parietal lobe

(Fig 3, D). With administration of carbamazepine, her abnormal neurologic findings were improved. EEG on day 2' failed to reveal paroxysmal discharges and showed focal slow waves on the right centroparietal region (Fig 4, B). On DW-MRI of Day 2', the cortical hyperintensity had disappeared, while ASL still indicated hyperperfusion in the corresponding area to that of cortical hyperintensity on DW-MRI of day 1' (Fig 3, F). With monotherapy of

carbamazepine, she was free from epilepsy during the 2 years from her second episode. Subsequent T2 prolonged lesion was not noted on the follow-up images.

## Discussion

Although “convulsive” SE is easily recognized, in the diagnosis of partial SE without discrete convulsion or such as our cases, capture of the ictal discharge on EEG is considered the gold standard.<sup>12,16,17</sup> However, it is practically difficult to record the ictal discharges without continuous EEG monitoring facilities. In most hospital, routine EEG examination is unavailable outside working hours or on weekends, and the timing of EEG recording is often delayed.<sup>16,17</sup> In the present study, we could not obtain ictal discharges in all 4 episodes of our 2 cases. A further problem in the EEG diagnosis of epilepsy is the sensitivity of post- or interictal EEG. During interictal state, paroxysmal activities are not always recorded. For adults presenting with a first seizure, a routine EEG revealed paroxysmal activities in only approximately 23% of patients.<sup>18</sup> In our study, interictal paroxysmal discharges were recorded only on day 1' in the second episode of case 1. Furthermore, a marked decrease in amplitude of these paroxysmal activities was noted on day 6', and these subtle paroxysms may have been overlooked. In other 3 episodes of our 2 cases, localized slow wave activities on the area corresponding to the old infarction were observed (only indicative of focal dysfunction) as the timing of EEG recordings was obviously delayed.

Theoretically, ictal hyperperfusion is often followed by postictal hypoperfusion, whereas temporal evolution of regional ictal hyperperfusion in the postictal stage has not been clearly defined. On ictal/postictal perfusion single photon emission tomography, Lee et al<sup>19</sup> demonstrated that postictal perfusion abnormalities did not return to the interictal phase at 6 hours after the epilepsy. A previous ASL study also reported that postictal regional hyperperfusion was observed immediately to 5 hours after a single seizure.<sup>6,8,9</sup> In the first episode of our case 1 and the second episode of case 2, postictal ASL hyperperfusion was still observed on day 4 and day 2', respectively, when the cortical hyperintensity on DW-MRI had almost disappeared. Oishi et al<sup>7</sup> reported that postictal ASL hyperperfusion was observed in the medial to lateral cortex of the right occipital lobe on the day of partial SE, when the hyperintensity on DW-MRI was observed in a limited area of the medial occipital lobe. These findings suggest that ictal ASL hyperperfusion persists postictally longer than that for DW-MRI hyperintensity, although this likely depends on the magnitude and duration of the epileptic activities.<sup>4,5</sup> Thus, the combined use of peri-ictal ASL and DW-MRI<sup>4,5,7,20</sup> may overcome the limitations of peri-ictal EEG recording in the diagnosis of nonconvulsive partial SE.

Cortical hyperintensity on DW-MRI should be differentiated from (pseudo) cortical laminar necrosis (CLN) associated with cerebral infarction. Incomplete infarction results in selective neuronal loss in the cortex with the presence of viable cells, glial proliferation, and deposition of paramagnetic substances. In acute infarction, CLN is demonstrated as a gyriform cortical high signal intensity area on DW-MRI,<sup>21</sup> which is quite similar to cortical hyperintensity associated with SE. CLN is an irreversible change and the chronological changes have been well demonstrated on various sequences of serial MRI.<sup>22</sup> In our case 1, the cortex of the old infarction area in the right parietal lobe was demonstrated as CLN on FLAIR image. By contrast, cortical hyperintensity associated SE is transient.<sup>4,5,7,20</sup> Furthermore, the area of cortical hyperintensity on DW-MRI should correspond to the hyperperfused area,<sup>4,5,20</sup> because the ictal hyperperfusion is a secondary change to meet the increased glucose and oxygen demand of the activated cortex. In both our cases, ASL clearly showed hyperperfusion in the area corresponding to that of cortical hyperintensity on DW-MRI at the ictus. Nonconvulsive partial SE can be complicated with stroke both in the acute and chronic stages.<sup>12,16,17</sup> In the present cases, cortical hyperintensity on DW-MRI was transient and subsequent T2 prolonged lesion was not demonstrated on the follow-up images. Therefore, the recurrence of cerebral infarction can be ruled out.

Another advantage of the combined use of ASL and DW-MRI is ability to use the localization data to document the pathophysiologic mechanism of partial epilepsy in each patient.<sup>7,10,20</sup> In our 2 patients, the ASL hyperperfusion and cortical hyperintensity on DW-MRI were observed around the old infarction. This finding clearly depicted the topographic relationship between the epileptogenic lesion (the old infarction) and the activated cortex (right parietal lobe around the old infarction). With this method, it is impossible to localize the epileptogenic focus or area, but the cortical area involved by spread of the epileptic activities in prolonged epilepsy can be clearly localized.<sup>5</sup> Our finding that the precentral gyrus was not involved with the epileptic activities may explain why our 2 patients developed “non-convulsive” SE instead of “convulsive” SE.

In conclusion, combined use of DW-MRI and ASL can provide information complementary to high-resolution structural MRI in the peri-ictal phase of nonconvulsive partial SE that may overcome the limitations of peri-ictal EEG recording and help differentiate this disorder from acute ischemic stroke.

## References

1. Winkler DT, Fluri F, Fuhr P, et al. Thrombolysis in stroke mimics: frequency, clinical characteristics, and outcome. *Stroke* 2009;40:1522-1525.

2. De Reuck J, Van Maele G. Transient ischemic attacks and inhibitory seizures in elderly patients. *Eur Neurol* 2009; 62:344-348.
3. Di Bonaventura C, Bonini F, Fattouch J, et al. Diffusion-weighted magnetic resonance imaging in patients with partial status epilepticus. *Epilepsia* 2009;50:45-52.
4. Flacke S, Wullner U, Keller E, et al. Reversible changes in echo planar perfusion- and diffusion-weighted MRI in status epilepticus. *Neuroradiology* 2000;42:92-95.
5. Szabo K, Poepel A, Pohlmann-Eden B, et al. Diffusion weighted and perfusion MRI demonstrates parenchymal changes in complex partial status epilepticus. *Brain* 2005; 128:1369-1376.
6. Pizzini FB, Farace P, Manganotti P, et al. Cerebral perfusion alterations in epileptic patients during peri-ictal and post-ictal phase: PASL vs DSC-MRI. *Magn Reson Imaging* 2013;31:1001-1005.
7. Oishi M, Ishida G, Morii K, et al. Ictal focal hyperperfusion demonstrated by arterial spin-labeling perfusion MRI in partial epilepsy status. *Neuroradiology* 2012; 54:653-656.
8. Pizzini F, Farace P, Zanoni T, et al. Pulsed-arterial-spin-labeling perfusion 3T MRI following single seizure: a first case report study. *Epilepsy Res* 2008;81:225-227.
9. Pollock JM, Deibler AR, West TG, et al. Arterial spin-labeled magnetic resonance imaging in hyperperfused seizure focus: a case report. *J Comput Assist Tomogr* 2008;32:291-292.
10. Toledo M, Munuera J, Salas-Puig X, et al. Localisation value of ictal arterial spin-labelled sequences in partial seizures. *Epileptic Disord* 2011;13:336-339.
11. Diehl B, Najm I, Ruggieri P, et al. Periictal diffusion-weighted imaging in a case of lesional epilepsy. *Epilepsia* 1999;40:1667-1671.
12. Hamamura T, Morioka T, Sayama T, et al. Cerebral hyperperfusion syndrome associated with non-convulsive status epilepticus following superficial temporal artery-middle cerebral artery anastomosis. Case report. *Neurol Med Chir (Tokyo)* 2010;50:1099-1104.
13. Kim J-A, Chung JI, Yoon PH, et al. Transient MR signal changes in patients with generalized tonicoclonic seizure or status epilepticus: periictal diffusion-weighted imaging. *AJNR Am J Neuroradiol* 2001;22: 1149-1160.
14. Lansberg MG, O'Brien MW, Norbash AM, et al. MRI abnormalities associated with partial status epilepticus. *Neurology* 1999;52:1021-1027.
15. Wieshmann UC, Symms MR, Shorvon SD. Diffusion changes in status epilepticus. *Lancet* 1997;350:493-494.
16. Morioka T, Sayama T, Nukae N, et al. Nonconvulsive status epilepticus during perioperative period of cerebrovascular surgery. *Neurol Med Chir (Tokyo)* 2011;51: 171-179.
17. Morioka T, Sayama T, Shimogawa T, et al. Electroencephalographic evaluation of cerebral hyperperfusion syndrome following superficial temporal artery-middle cerebral artery anastomosis. *Neurol Med Chir (Tokyo)* 2013;53:388-395.
18. Krumholz A, Wiebe S, Gronseth G, et al. Practical parameter: evaluating an apparent unprovoked first seizure in adults (an evidence-based review): report of the Quality Standards Subcommittee of the American Academy of Neurology and the American Epilepsy Society. *Neurology* 2007;69:1996-2007.
19. Lee DS, Lee SK, Kim SK, et al. Late postictal residual perfusion abnormality in epileptogenic zone found on 6-hour postictal SPECT. *Neurology* 2000;55:835-841.
20. Calistri V, Caramia F, Bianco F, et al. Visualization of evolving status epilepticus with diffusion and perfusion MR imaging. *AJNR Am J Neuroradiol* 2003;24: 671-673.
21. Lovblad KO, Wetzel SG, Somon T, et al. Diffusion-weighted MRI in cortical ischaemia. *Neuroradiology* 2004;46:175-182.
22. Kesavadas C, Santhosh K, Thomas B, et al. Signal changes in cortical laminar necrosis. Evidence from susceptibility-weighted magnetic resonance imaging. *Neuroradiology* 2009;51:293-298.