

CASE REPORT

Macular pattern dystrophy and homonymous hemianopia in MELAS syndrome

Radua Kamal-Salah,¹ Isabel Baquero-Aranda,¹ María del Mar Grana-Pérez,¹ Jose Manuel García-Campos²

¹Department of Ophthalmology, Hospital Virgen de la Victoria of Malaga, Spain, Malaga, Malaga, Spain

²Department of Ophthalmology, Centro de Investigaciones Médico-Sanitarias, Malaga, Malaga, Spain

Correspondence to

Professor Jose Manuel García-Campos, raduamohamed@gmail.com

Accepted 20 February 2015

SUMMARY

We report an unusual association of a pattern dystrophy of the retinal pigment epithelium and homonymous hemianopia in a woman diagnosed with mitochondrial myopathy, encephalopathy, lactic acidosis and stroke-like episodes syndrome.

BACKGROUND

The syndrome of mitochondrial myopathy, encephalopathy, lactic acidosis and stroke-like episodes (MELAS) is a maternally inherited disorder due to mitochondrial DNA point mutation affecting transfer RNA. Ophthalmic features, including external ophthalmoplaegia, ptosis, pigmentary retinopathy, pattern dystrophy, myopia, nuclear cataract and optic atrophy, have been described in patients with adenine-guanine 3243 point mutation.^{1 2}

Pigmentary retinopathy, characterised by symmetric areas of depigmentation involving predominantly the posterior pole and midperipheral retina, are the most common ophthalmological findings in these patients.

The aim of this paper is to report an unusual association between homonymous hemianopia and pattern dystrophy of the retinal pigment epithelium (RPE) in a patient with MELAS syndrome.

CASE PRESENTATION

A 24-year-old woman presented with intense oppressive occipital headache, vomiting, sonophobia and photophobia, as well as repeated motor focal seizures with oculocephalic deviation. She was admitted to the neurology unit, where she had the appropriate ancillary tests. Relevant personal history included migraine with aura and primary amenorrhoea with no relevant family history.

Neurological examination was normal except for the left homonymous hemianopia. Blood test showed lactic acidosis. Serology to diverse germs (neurotropic virus, *Syphilis*, *Mycoplasma*, *Borrelia*, *Chlamydia*, *Brucella* and *Rickettsia*) was negative. Brain MRI revealed right temporoparietal-occipital involvement, with significant diffusion restriction (stroke-like) and left parieto-occipital involvement without diffusion restriction. The echocardiogram ruled out cardiomyopathy (left ventricle with good contractility and preserved ejection fraction, right cavities also normal).

A possible mitochondrial encephalopathy MELAS type was suspected. This diagnosis was confirmed by genetic testing (which detected the presence of heteroplasmy in the A3224G mutation).

The patient was referred to our practice due to a decrease in visual acuity to rule out possible ophthalmological lesions. Examination revealed left homonymous hemianopia and best corrected visual acuity of 20/40 in the right eye and of 20/70 in the left eye. Anterior segment biomicroscopy did not reveal significant data. Intraocular pressure was 15 mm Hg in both eyes. The ophthalmoscopy revealed linear pigmentation surrounding the macula with areas of hypopigmentation, consistent with pigment epithelium atrophy, more evident in the right eye (figure 1). Fluorescein angiography demonstrated mottled hyperfluorescent and hypofluorescent central areas indicating multiple window defects in the RPE, with greater involvement of the right eye (figure 2). Electroretinogram showed a reduction of photopic and scotopic b-wave amplitudes with normal implicit times. Therefore, macular pattern dystrophy was diagnosed. Figure 3 shows the results of the autofluorescence and optical coherence tomography images.

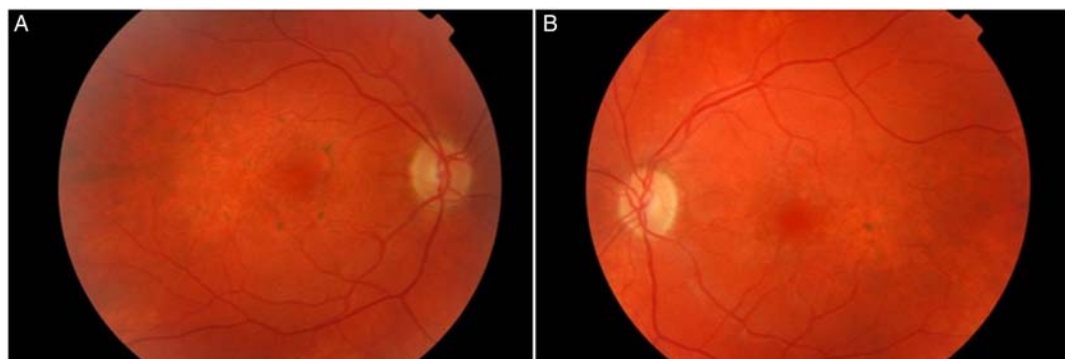

Figure 1 Colour fundus photograph. (A) Right eye. (B) Left eye.



To cite: Kamal-Salah R, Baquero-Aranda I, Grana-Pérez M del M, et al. *BMJ Case Rep* Published online: [please include Day Month Year] doi:10.1136/bcr-2014-206499

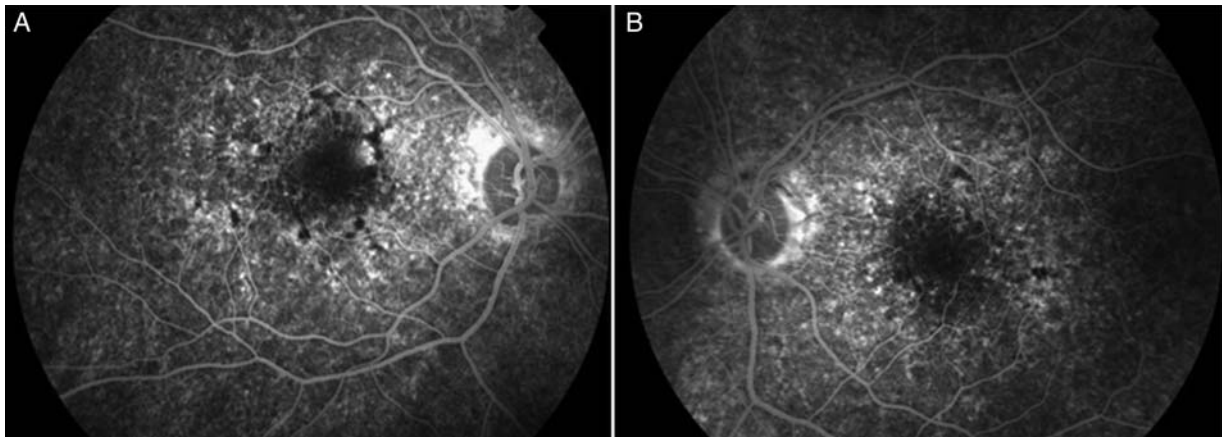


Figure 2 Fluorescein angiography. (A) Right eye. (B) Left eye.

Figure 4 shows the MRI and a visual field test carried out 2 weeks after the stroke-like episode.

DISCUSSION

The clinical criteria for the diagnosis of MELAS syndrome include episodes that mimic stroke and do not correspond to vascular territories; they consist of focal neurological deficits of sudden onset, with a predilection for the occipital area, causing

visual defects; however, motor, sensory or language disorders may appear as well. Other symptoms and signs of this syndrome are muscle weakness, seizures, dementia, episodic vomiting, lactic acidosis, positive family history, ragged red fibres, spongiform degeneration, basal ganglia calcification, short stature, sensorineural hearing loss of cochlear origin and hemicranial headache.³

This disorder is characterised by impaired energy production due to oxidative phosphorylation dysfunction. Mitochondria

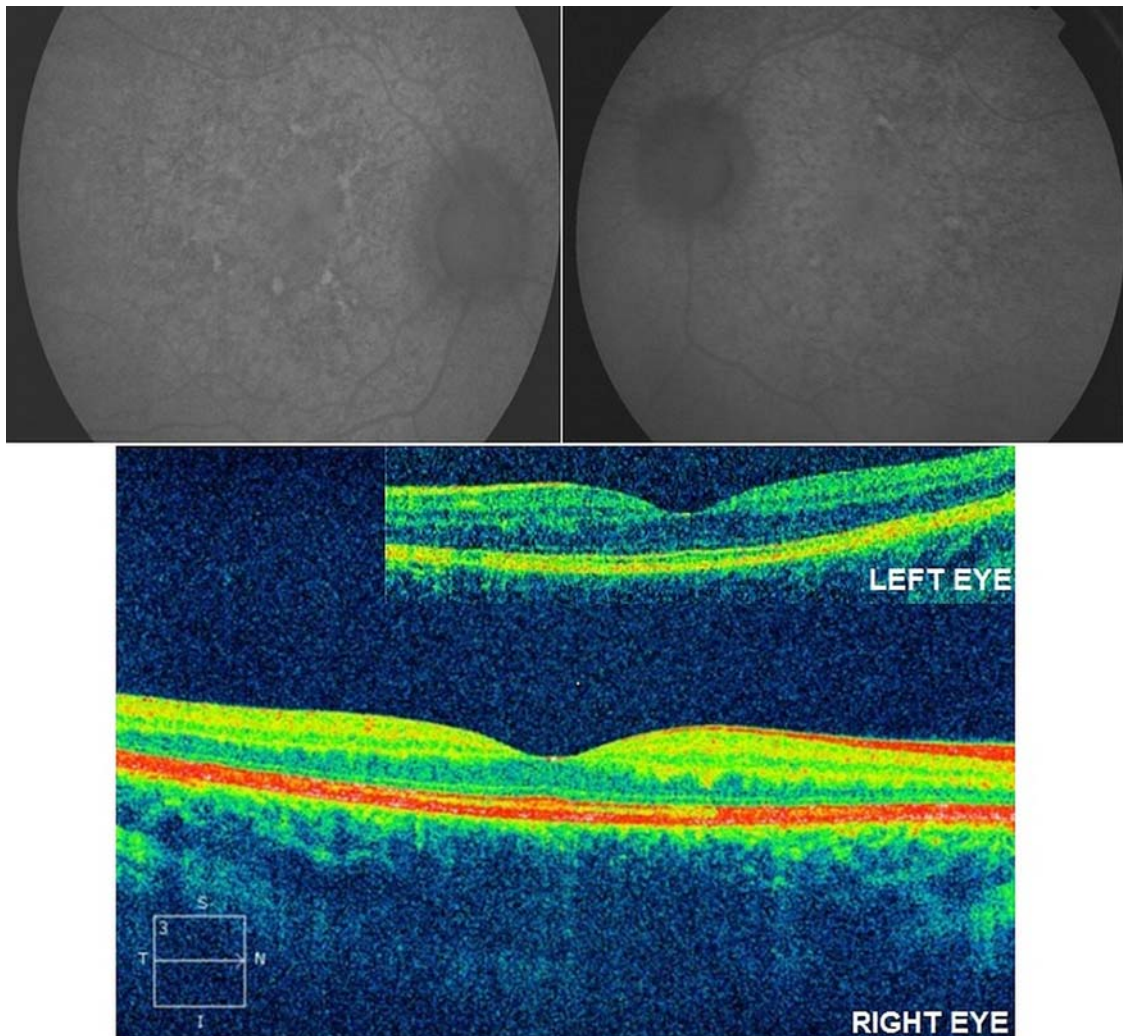


Figure 3 Autofluorescence imaging/optical coherence tomography imaging.

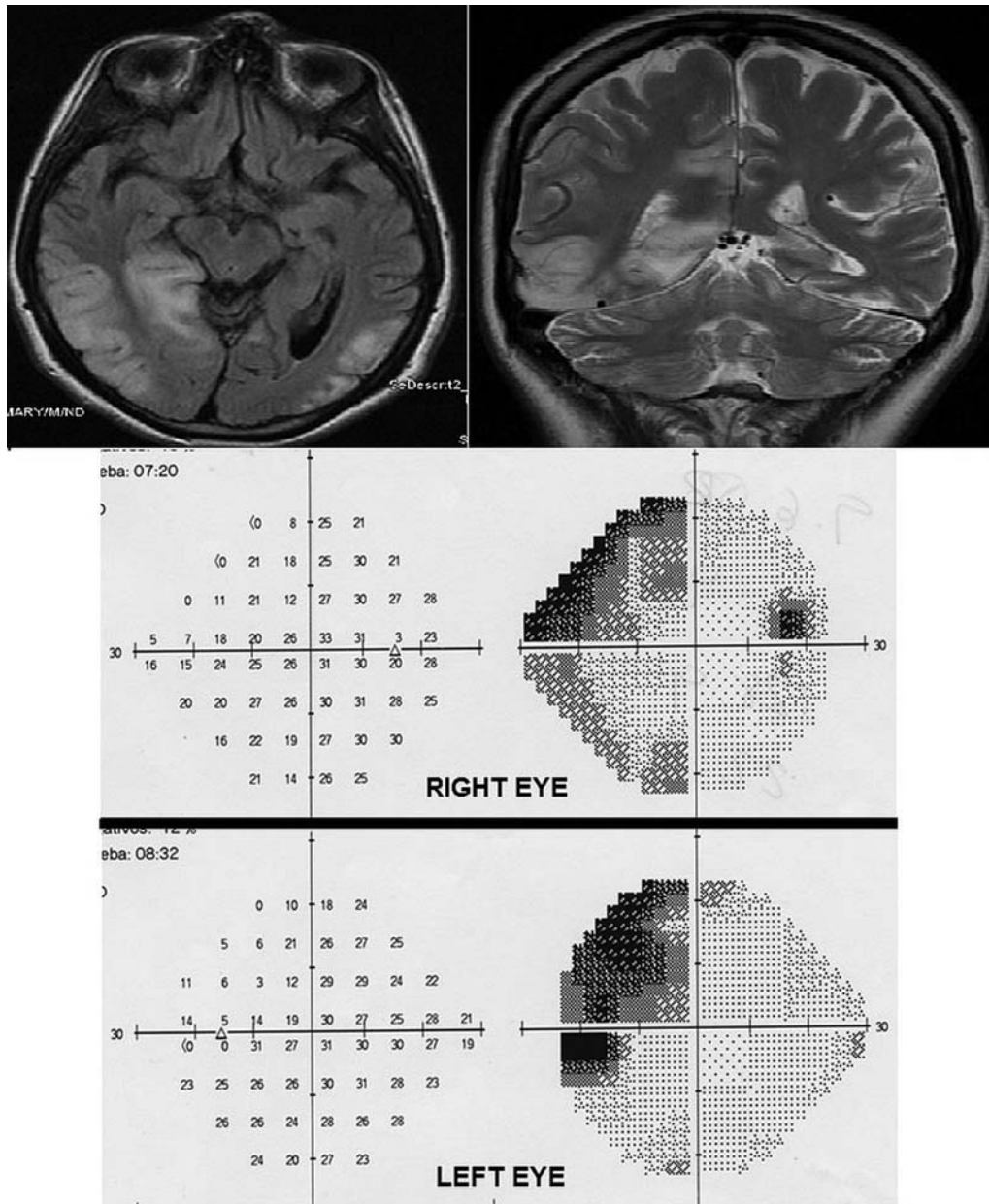


Figure 4 MRI/Humphrey visual field test performed 2 weeks after the stroke-like episode showing left quadrantanopsia.

participate in the synthesis of ATP and in the initiation of apoptosis.² Affected organs are those with a high-energy demand such as the heart, retina and central nervous system.

Histopathological changes include depigmentation and hyperpigmentation of the RPE, degeneration of the choroid and the outer segment of photoreceptors and a reduction in the number of ganglion cells. The photoreceptor degeneration has been reported to be secondary to pigment epithelium loss. Pigment epithelium is involved in the phagocytosis of the shed tips of photoreceptor outer segments and regulation of subretinal volume via ion-coupled fluid absorption. Ions and water are actively transported by this layer and ATP is necessary to maintain this function. A deficiency in intracellular ATP would compromise the normal function of these cells.^{4,5}

Pigmentary retinopathy occurs late in life and is a non-specific finding of mitochondrial disorder. Ocular fundus changes in MELAS syndrome range from mild 'salt and pepper' retinopathy to

severe bone spicule-shaped pigment with atrophy of the pigment epithelium.⁶⁻¹⁰ In our case, a pattern dystrophy was found.

Latkany *et al*¹ and Adjadj *et al*² reported cases of geographic maculopathy in MELAS syndrome. In maternal inherited diabetes and deafness (MIDD), bilateral pattern dystrophy was present in 30 of the 35 patients with MIDD (85.7%). However, only one of the three patients with MELAS syndrome had pattern dystrophy.¹¹ In the studies of Sue *et al*⁸ and Latvala *et al*¹² pattern macular dystrophy was not found.

Our patient presented with an unusual association, left homonymous hemianopia (caused by the stroke-like episode) and pattern dystrophy of the pigment epithelium. To the best of our knowledge, this is the first time the association has been reported in the same patient, although different types of atrophy of the pigment epithelium have been reported. Pigment epithelium abnormalities are less common than sensorineural hearing impairment.^{2,11}

Learning points

- ▶ Retinal manifestations are not uncommon in mitochondrial diseases.
- ▶ It is necessary to perform a complete ophthalmological examination in every patient with mitochondrial disease.
- ▶ Patients must also undergo periodic monitoring for the possible development of lesions, which are mostly asymptomatic and detected by ophthalmoscopy.

Competing interests None.

Patient consent Obtained.

Provenance and peer review Not commissioned; externally peer reviewed.

REFERENCES

- 1 Latkany P, Ciulla TA, Cacchillo PF, *et al.* Mitochondrial maculopathy: geographic atrophy of the macula in the MELAS associated A to G 3243 mitochondrial DNA point mutation. *Am J Ophthalmol* 1999;128:112–14.
- 2 Adjadj E, Mansouri K, Borruat FX. Mitochondrial DNA (mtDNA) A 3243G mutation associated with an annular perimacular retinal atrophy. *Klin Monbl Augenheilkd* 2008;225:462–4.
- 3 Lombes A, Bonilla E, Dimauro S. Mitochondrial encephalomyopathies. *Rev Neurol* 1989;145:671–89.
- 4 Defoe DM, Ahmad A, Chen W, *et al.* Membrane polarity of the NA(+)-K+ pump in primary cultures of Xenopus retinal pigment epithelium. *Exp Eye Res* 1994;59:587–96.
- 5 Hughes BA, Takahira M. ATP-dependent regulation of inwardly rectifying K+ current in bovine retinal pigment epithelial cells. *Am Physiol Soc* 1998;275(5 Pt 1): C1372–83.
- 6 Villafuella IM, Tejada P, García Silva MT, *et al.* Hallazgos oftalmológicos en pacientes con enfermedades mitocondriales. Published in: http://nexusediciones.com/np_ao_1997_7_2_002.htm
- 7 Mojon D. Eye diseases in mitochondrial encephalomyopathies. *Ther Umsch* 2001;58:49–55.
- 8 Sue CM, Mitchell P, Crimmins DS, *et al.* Pigmentary retinopathy associated with the mitochondrial DNA 3243 point mutation. *Neurology* 1997;49:1013–17.
- 9 Jones M, Mitchell P, Wang JJ, *et al.* MELAS A3243G mitochondrial DNA mutation and age related maculopathy. *Am J Ophthalmol* 2004;138:1051–3.
- 10 Isashiki Y, *et al.* Retinal manifestations in mitochondrial diseases associated with mitochondrial DNA mutations. *Acta Ophthalmol Scand* 1998;76:6–13.
- 11 Massin P, Virally-Monod M, Vialettes B, *et al.* Prevalence of macular pattern dystrophy in maternally inherited diabetes and deafness. GEDIAM Group. *Ophthalmology* 1999;106:1821–7.
- 12 Latvala T, Mustonen E, Uusiato R, *et al.* Pigmentary retinopathy in patients with the MELAS mutation 3243A-G in mitochondrial DNA. *Graefes Arch Clin Exp Ophthalmol* 2002;240:795–801.

Copyright 2015 BMJ Publishing Group. All rights reserved. For permission to reuse any of this content visit <http://group.bmj.com/group/rights-licensing/permissions>.

BMJ Case Report Fellows may re-use this article for personal use and teaching without any further permission.

Become a Fellow of BMJ Case Reports today and you can:

- ▶ Submit as many cases as you like
- ▶ Enjoy fast sympathetic peer review and rapid publication of accepted articles
- ▶ Access all the published articles
- ▶ Re-use any of the published material for personal use and teaching without further permission

For information on Institutional Fellowships contact consortiasales@bmjgroup.com

Visit casereports.bmj.com for more articles like this and to become a Fellow