

# Writing Tremor Secondary to Ischemic Stroke: A Report on a Case With a Remarkable Response to Topiramate

Juan P. Paviolo, MD, Gabriela B. Raina, MD, Eugenia Conti, MD, and Federico Micheli, MD, PhD

**Abstract:** Writing tremor (WT) is a task-specific tremor that occurs only or mostly while writing with the dominant hand. Secondary cases are extremely uncommon. We report on a patient who, after developing a WT after an ischemic stroke, had a remarkable response to topiramate (TPM).

**Case:** A 65-year-old right-handed man with a history of arterial hypertension, dyslipidemia, and coronary heart disease presented dizziness and headache followed by a loss of consciousness and then a right hemiparesis. He regained his strength on the fifth day. Fourteen days after stroke, he developed a WT as well as other complications with activities such as welding (he is a welder) and using a spoon. He was treated with 50 mg/d of TPM with marked improvement in WT. A few weeks after TPM was discontinued, the WT symptoms reappeared and he was retreated, showing the same beneficial reaction.

Electromyographic record showed a 5- to 6-Hz tremor in his right hand, and a magnetic resonance imaging showed bilateral small frontoparietal subcortical infarcts.

**Conclusions:** Primary WT pathophysiology is not well known, and secondary WT as a result of stroke is even less considered. Although patients with essential tremor benefit with TPM and WT could be a variant of essential tremor, we used TPM with our patient and there was a marked benefit.

**Key Words:** writing tremor, task-specific tremor, secondary writing tremor, stroke, topiramate

(*Clin Neuropharm* 2015;38: 57–59)

A task-specific tremor is a form of tremor that appears while performing or attempting to perform a particular task. The most common form is writing tremor (WT) that manifests only or mostly during writing with the dominant hand. It is classified into type A when the tremor appears while writing and type B when the hand adopts the writing position.<sup>1,2</sup> It is controversial whether primary WT is a variant of essential tremor, which is a type of focal dystonia or a separate nosological entity because its pathogenesis remains poorly understood.<sup>3</sup>

We could find only 1 case of WT secondary to a discrete cortical infarction in the literature.<sup>4</sup> Here, we report on a patient who developed WT after an ischemic stroke and showed a remarkable improvement with topiramate (TPM).

## CASE REPORT

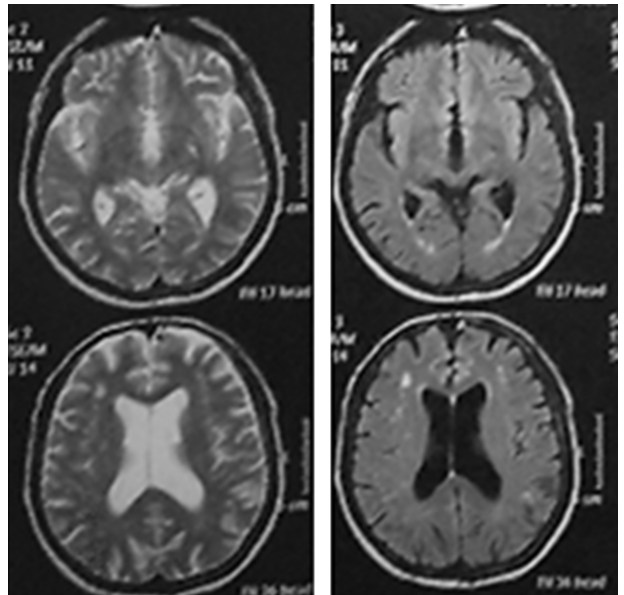
A 65-year-old right-handed man with a history of arterial hypertension, dyslipidemia, and coronary heart disease had an ischemic stroke 2 years before coming to our movement disorder

Parkinson's Disease and Movement Disorders Program, Hospital de Clínicas José de San Martín, University of Buenos Aires, Buenos Aires, Argentina. Address correspondence and reprint requests to Federico Micheli, MD, PhD, Parkinson's Disease and Movement Disorders Program, Hospital de Clínicas José de San Martín, Juncal 1695 Piso 5 J, 1062 Buenos Aires, Argentina; E-mail: fmicheli@fibertel.com.ar.

Conflicts of Interest and Source of Funding: The authors have no conflicts of interest to declare.


Copyright © 2015 Wolters Kluwer Health, Inc. All rights reserved.

DOI: 10.1097/WNF.0000000000000069




**FIGURE 1.** Magnetic resonance image performed 2 years after stroke: multiple bilateral small images in frontoparietal subcortical and periventricular region, hyperintense on T2 and Flair sequences.

center. He had experienced dizziness and headache for several hours followed by a sudden loss of consciousness. When he recovered consciousness, he had a right hemiparesis. Five days later, he had completely recovered his strength. Two weeks after this, he developed a mild WT that was initially present only on certain occasions, but after several days, it became present every time he attempted to write. In addition, a few days later, other specific activities such as welding (the patient is a welder by profession) or using a spoon to consume soup also triggered the tremor. This tremor remained stable for almost 2 years. He had no personal or family history of tremor before the stroke. A therapeutic



A



B

**FIGURE 2.** A, Patient writing before treatment. B, Patient writing 7 days after taking 50 mg/d of TPM.

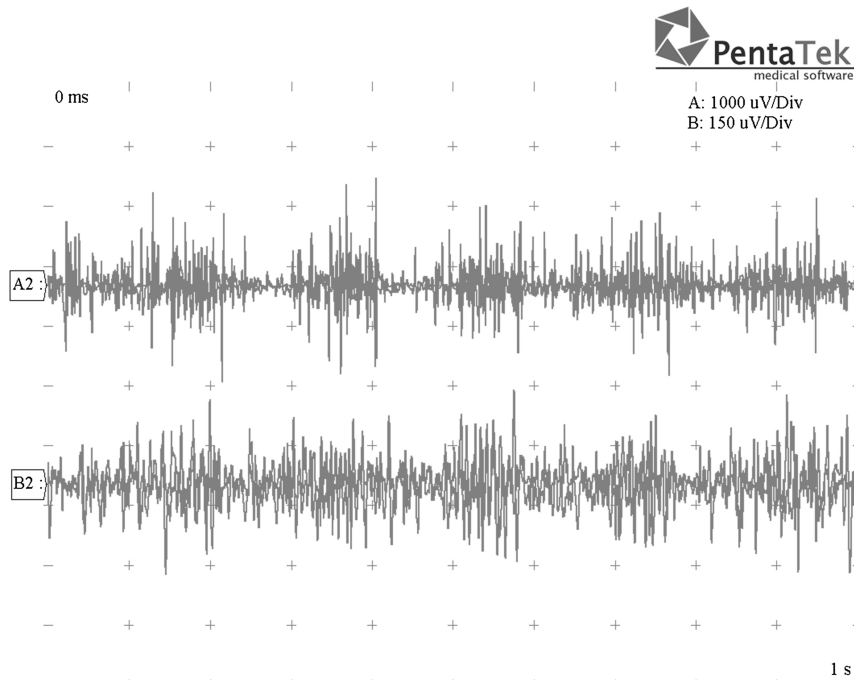


FIGURE 3. Electromyographic recording: 5- to 6-Hz tremor on his right hand when writing.

attempt with levodopa-carbidopa was made without any improvement. When we first saw him, he had no paresis, ataxia, or sensory disturbances. He had no resting tremor, and he only exhibited tremor when writing or adopting a writinglike posture.

The magnetic resonance imaging performed 2 years after the stroke showed multiple bilateral small images, which were hyperintense on T2 and Flair sequences in the frontoparietal subcortical regions (Fig. 1). He was treated with 50 mg/d of TPM in which he reported a remarkable improvement on tremor (Fig. 2) of up to 80%. After a few months, TPM was discontinued, but the tremor reappeared and only improve again when the drug was reintroduced (Fig. 3).

## DISCUSSION

Only 1% to 4% of the manifestations of stroke are movement disorders, and of these poststroke involuntary movements, tremor represents only a small percentage.<sup>5-7</sup> The time at onset of movement disorders after a stroke is quite variable, ranging from the same day to several years after stroke. It is assumed that the delay between the stroke and the onset of the involuntary movement is caused by the time required for the partial recovery of motor function and the development of a pathological circuitry.<sup>5,8,9</sup> Although we cannot be absolutely sure that the development of tremor in our patient was not a coincidence, it is highly suggestive to be a poststroke tremor because it began 14 days after a stroke and the patient had no personal or family history of tremor. Another feature of poststroke involuntary movements is that they usually start gradually and get progressively worse for weeks or months and then stabilize, as has happened with our patient.<sup>9</sup> Primary WT physiopathology is unknown and even less is known about poststroke WT. Poststroke movement disorders have been associated with lesions in different locations, although the most common locations are the basal ganglia and thalamus.<sup>8</sup> Small vessel disease, with small deep infarcts, is the most common subtype leading to involuntary movements.<sup>6-8</sup> To our knowledge, this is the second case of WT secondary to an ischemic stroke. Our case

is different from the previously reported case because we could not identify the causal lesion, whereas the previous case had a discrete cortical infarct in the left frontal lobe between the central and precentral sulci<sup>4</sup> that was responsible for the tremor. In our patient, we observed multiple bilateral small images in the frontoparietal subcortical region, which were hyperintense on T2 and Flair sequence on magnetic resonance imaging.

Essential tremor and other hyperkinetic movements such as vascular chorea may respond to treatment with TPM. This drug has complex action mechanisms, which include blocking voltage-gated sodium channels, augmenting  $\gamma$ -aminobutyric acid (GABA) activity at the GABA-A receptors, antagonizing the  $\alpha$ -amino-3-hydroxy-5-methyl-4-isoxazolepropionic acid/kainate glutamate receptors, and inhibiting the carbonic anhydrase enzyme.<sup>10</sup>

It is postulated that the mechanism by which TPM improves vascular chorea could be through GABAergic potentiation of the indirect pathway of the basal ganglia in vascular chorea.<sup>11</sup> For the essential tremor, TPM is believed to act by facilitating GABAergic transmission on olive and cerebellar-thalamic-cortical pathways. Furthermore, it has been postulated that, for symptomatic dystonic tremor resembling essential tremor, therapeutic strategies are the same for essential tremor.<sup>12</sup> It is for this latter mechanism of action that we assume our patient improved so greatly.

## REFERENCES

1. Deuschl G, Heinen P, Brin M. Consensus statement of the Movement Disorder Society on tremor. Ad Hoc Scientific Committee. *Mov Disord.* 1998;13:2-23.
2. Bain PG, Findley LJ, Britton TC, et al. Primary writing tremor. *Brain.* 1995; 118:1461-1472.
3. H Chen, Y Wang, H Wei, et al. Advances in primary writing tremor. *Parkinsonism Relat Disord.* 2010;16:561-565.
4. Kim JS, Lee MC. Writing tremor after discrete cortical infarction. *Stroke.* 1994;25:2280-2282.

5. Alarcón F, Zijlmans JC, Dueñas G, et al. Post-stroke movement disorders: report of 56 patients. *J Neurol Neurosurg Psychiatry*. 2004; 75:1568–1574.
6. Ghika-Schmid F, Ghika J, Regli F, et al. Hyperkinetic movement disorders during and after acute stroke: the Lausanne Stroke Registry. *J Neurol Sci*. 1997;10(146):109–116.
7. Mehanna R, Jankovic J. Movement disorders in cerebrovascular disease. *Lancet Neurol*. 2013;12:597–608.
8. Handley A, Medcalf P, Hellier K, et al. Movement disorders after stroke. *Age Ageing*. 2009;38:260–266.
9. Kim JS. Delayed onset mixed involuntary movements after thalamic stroke: clinical, radiological and pathophysiological findings. *Brain*. 2001; 124:299–309.
10. Hedera P, Cibulčík F, Davis TL. Pharmacotherapy of essential tremor. *J Cent Nerv Syst Dis*. 2013;5:43–55.
11. Kim JA, Jung S, Kim MJ, et al. A case of vascular hemichorea responding to topiramate. *J Mov Disord*. 2009;2(2):80–81.
12. Gironell A, Kulisevsky J. Diagnosis and management of essential tremor and dystonic tremor. *Ther Adv Neurol Disord*. 2009;2(4): 215–222.