

# Reversible cerebral vasoconstriction in Guillain–Barré syndrome



Diana Y. Wei\*, Justin Kao, Teddy Y. Wu, Jennifer A. Pereira, Neil E. Anderson, P. Alan Barber

Department of Neurology, Auckland City Hospital, Auckland, New Zealand

## ARTICLE INFO

### Article history:

Received 5 October 2014

Accepted 9 December 2014

### Keywords:

Autonomic dysfunction

Guillain–Barré

Headache

Reversible cerebral vasoconstriction syndrome

## ABSTRACT

We present a 51-year-old woman with clinical and neurophysiological evidence of Guillain–Barré syndrome (GBS) who developed a generalised headache and autonomic dysfunction with sinus tachycardia, hypertension, gastrointestinal motility symptoms and urinary retention. MRI/MRA demonstrated cerebral vasoconstriction and a small convexity subarachnoid haemorrhage which resolved after 3 months. Reversible cerebral vasoconstriction syndrome (RCVS) is characterised by headache, focal neurological deficits or seizures, and reversible cerebral vasoconstriction. To our knowledge, this is the first reported case of RCVS complicating autonomic dysfunction in GBS. This case depicts a rare complication of a common condition and also sheds light on the potential mechanism of RCVS. Neurologists should be aware that autonomic dysfunction can lead to RCVS in GBS.

© 2015 Elsevier Ltd. All rights reserved.

## 1. Introduction

Autonomic dysfunction, including cardiac arrhythmias, hypertension, hypotension and sphincteric disturbance occurs in approximately two thirds of people with Guillain–Barré syndrome (GBS) and contributes to mortality [1,2]. Cardiovascular instability in GBS has been attributed to impaired regulation of sympathetic output secondary to demyelination of baroreceptor afferent nerve fibres [3]. We report a patient with GBS and autonomic dysfunction who developed reversible cerebral vasoconstriction syndrome (RCVS) leading to convexial subarachnoid haemorrhage (SAH).

## 2. Case description

A 51-year-old woman presented with 8 days of numbness and tingling in her limbs, 6 days of vomiting and diarrhoea and 5 days of progressive lower limb weakness. She then developed urinary retention, constipation and a generalised headache, not thunder-clap in onset. There was no antecedent illness. She had a background of well-controlled hypertension on enalapril. She denied recreational drug use.

On examination, she was alert, afebrile and there was no meningism. Her pulse was 90/min and regular and blood pressure was 200/100 mmHg. She had bilateral lower facial weakness, dysarthria and neck flexion weakness. Limb tone was normal. She had global limb weakness (MRC grade 4/5 in the upper limbs and 3/5 in the lower limbs). Tendon reflexes were absent with flexor plantar responses. Light touch and pain sensation was reduced in a stocking distribution. Proprioception and vibration sensation were impaired distally.

Serum sodium was 118 mmol/L, serum osmolality 245 mmol/kg (normal range: 280–300) and urine osmolality 324 mmol/kg (normal range: 50–1200). Cerebrospinal fluid examination showed  $<1 \times 10^6$  white blood cells/L,  $211 \times 10^6$  red blood cells/L, elevated bilirubin absorbance 24 mAU (milli-absorbance unit; normal range: 0–7) and protein 1.49 g/L. Nerve conduction studies showed changes consistent with an acute demyelinating

polyradiculoneuropathy. Intravenous immunoglobulin 2 g/kg was given over 5 days.

Brain MRI showed a small amount of convexity SAH (Fig. 1a) and MRA showed variation in the calibre of branches of the right middle and left anterior cerebral arteries (Fig. 1b).

Sinus tachycardia persisted and the systolic blood pressure remained elevated between 180–200 mmHg until controlled with intravenous labetalol, and oral felodipine, cilazapril and hydrochlorothiazide. Serum sodium increased to 129 mmol/L over 48 hours with fluid restriction and then normalised by 2 weeks.

After 6 weeks in hospital, the limb weakness persisted but she was able to mobilise independently. The sensory symptoms had significantly improved. A repeat MRI and MRA at 3 months showed resolution of the segmental narrowing of the cerebral arteries with residual cerebral convexity siderosis (Fig. 1c). At 7 months, she had no symptoms and a normal neurologic examination apart from absent tendon reflexes.

## 3. Discussion

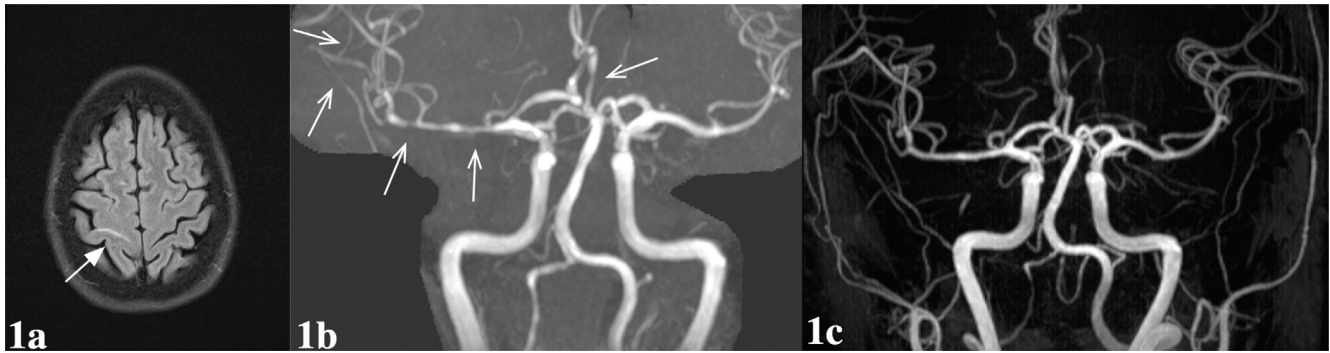
We present a woman with GBS complicated by autonomic dysfunction. This patient also met the proposed diagnostic criteria for RCVS with recent onset headaches and cerebral vasoconstriction in at least two different arteries which resolved within 3 months [4]. We hypothesise that the autonomic dysfunction was the cause of RCVS in this woman. This patient also had convexity SAH which was the most frequently associated radiological finding in RCVS in a prospective series of 67 patients [4,5].

Hyponatraemia in this patient could have been a complication of either the GBS or SAH. Both conditions can lead to the syndrome of inappropriate antidiuretic hormone secretion. SAH can also cause hyponatraemia through cerebral salt wasting and GBS-associated autonomic dysfunction can lead to hyponatremia by renal salt wasting [6].

To our knowledge, this is the first reported case of RCVS complicating GBS. The presumptive mechanism for RCVS in this patient is failure of cerebral autoregulation due to hypertension. RCVS occurring as the result of a sudden rise in systemic blood pressure has been reported in a patient with autonomic dysfunction following traumatic cervical cord injury [7]. The most common association of RCVS is exposure to vasoactive substances [4]. Less common precipitants of RCVS are head trauma and cerebral hyperperfusion

\* Corresponding author. Address: Southmead Hospital, Department of Neurology, Southmead Road, Bristol, BS10 5NB, UK. Tel.: +44 7887845789; fax: +44 117 414 9475.

E-mail address: dianawei@doctors.org.uk (D.Y. Wei).



**Fig. 1.** Brain MRI brain and MRA demonstrating reversible cerebral vasoconstriction syndrome. (a) Brain MRI T2-weighted fluid attenuated inversion recovery axial image at presentation demonstrating convexity subarachnoid haemorrhage within a right central sulcus (arrow). (b) Brain MRA coronal image at presentation demonstrating moderate diffuse calibre variation of the right M1 segment and proximal middle cerebral artery branches and left A2 (arrows) consistent with cerebral vasoconstriction. (c) Brain MRA coronal image at 3 months follow-up with resolution of the segmental narrowing of the cerebral vessels.

following carotid endarterectomy [8]. No cause is found in approximately one third of patients [4].

There are no randomised controlled trials to guide treatment of RCVS. Aggressive management of hypertension and the removal of any precipitants are the mainstays of therapy. Nimodipine has been advocated but there is no firm evidence of benefit [5].

Our case demonstrates a rare complication of GBS and an unusual cause of RCVS. It also sheds light on the potential mechanism of RCVS. Neurologists should be aware that patients with GBS and autonomic dysfunction can develop RCVS.

#### Conflicts of Interest/Disclosures

The authors declare that they have no financial or other conflicts of interest in relation to this research and its publication.

<http://dx.doi.org/10.1016/j.jocn.2014.12.012>

#### References

- [1] Hughes RA, Cornblath DR. Guillain–Barré syndrome. *Lancet* 2005;366:1653–66.
- [2] van Doorn PA, Ruts L, Jacobs BC. Clinical features, pathogenesis, and treatment of Guillain–Barré syndrome. *Lancet Neurol* 2008;7:939–50.
- [3] Ropper AH, Wijdicks EF. Blood pressure fluctuations in the dysautonomia of Guillain–Barré syndrome. *Arch Neurol* 1990;47:706–8.
- [4] Ducros A, Boukobza M, Porcher R, et al. The clinical and radiological spectrum of reversible cerebral vasoconstriction syndrome. A prospective series of 67 patients. *Brain* 2007;130:3091–101.
- [5] Ducros A. Reversible cerebral vasoconstriction syndrome. *Lancet Neurol* 2012;11:906–17.
- [6] Lenhard T, Grimm C, Ringleb PA. Renal salt wasting as part of dysautonomia in Guillain–Barré syndrome. *J Neurol Neurosurg Psychiatry* 2011;82:1051–3.
- [7] Edvardsson B, Persson S. Reversible cerebral vasoconstriction syndrome associated with autonomic dysreflexia. *J Headache Pain* 2010;11:277–80.
- [8] Wu TY, Anderson NE, Barber PA. Neurological complications of carotid revascularisation. *J Neurol Neurosurg Psychiatry* 2012;83:543–50.

## Occult temporal lobe encephalocoele into the transverse sinus



Hamed Asadi<sup>a,\*</sup>, Andrew Morokoff<sup>b</sup>, Frank Gaillard<sup>a,c</sup>

<sup>a</sup> Department of Radiology, Royal Melbourne Hospital, Parkville, VIC, Australia

<sup>b</sup> Department of Neurosurgery, Royal Melbourne Hospital, Parkville, VIC, Australia

<sup>c</sup> Department of Radiology, University of Melbourne, Parkville, VIC, Australia

#### ARTICLE INFO

##### Article history:

Received 29 December 2014

Accepted 4 January 2015

##### Keywords:

Encephalocoele  
Neuroradiology  
Neurosurgery

#### ABSTRACT

In this article we present a case of an incidental encephalocoele protruding through a dural defect into the transverse sinus. Encephalocoeles are usually described as a herniation of the meninges and brain parenchyma through a bony defect of the cranium or base of skull. To our knowledge, there are only a few patients reported in the literature of occult encephalocoeles through dural defects. Our case study highlights that encephalocoele should be a differential diagnosis for a filling defect in this location.

© 2015 Elsevier Ltd. All rights reserved.

#### 1. Introduction

An encephalocoele is traditionally defined as a herniation of the meninges and brain parenchyma through a defect of the cranium or base of skull. However, they can also occur through a dural

\* Corresponding author. Tel.: +61 3 93427000.

E-mail address: [asadi.hamed@gmail.com](mailto:asadi.hamed@gmail.com) (H. Asadi).