

Periodic eye opening and upward eye deviation accompanied by burst-suppression, as an isolated clinical manifestation of acute post-hypoxic myoclonus

Nese Dericioglu, Ethem Murat Arsava,
Mehmet Akif Topcuoglu

Hacettepe University Faculty of Medicine, Ankara, Turkey

Received September 19, 2014; Accepted January 29, 2015

ABSTRACT – Various movement disorders have been described following hypoxic-ischaemic brain injury. Here, we present a 72-year-old female patient who developed periodic opening and upward deviation of the eyes as an isolated clinical finding, within 24 hours after cardio-pulmonary arrest. These movements were accompanied by burst-suppression on EEG, and both clinical and electrophysiological findings were suppressed 18 hours after intravenous levetiracetam infusion. The strictly periodic nature of both EEG discharges and eye opening with vertical deviation suggest a cause due to either activation of a subcortical/brainstem pacemaker reciprocally stimulating the cortex, or, alternatively, post-anoxic burst activity of viable cortical neural networks, somehow stimulating the relevant oculomotor nuclei. Together with previous similar cases, our case expands the spectrum of post-resuscitation myoclonus syndromes with the addition of this rare isolated oculopalpebral subtype. [*Published with video sequence*]

Key words: cardio-pulmonary arrest, post-hypoxic myoclonus, periodic eye opening, burst-suppression, levetiracetam

Many different movement disorders have been described following hypoxic-ischaemic brain injury, such as dystonia, chorea, tics, tremor, athetosis, parkinsonism and myoclonus (Venkatesan and Frucht, 2006). Acute post-

hypoxic myoclonus typically begins within the first 24 hours after hypoxia-ischaemia, and is usually characterized by diffuse, massive body jerks in comatose patients (Hallett, 2000). When prolonged and accompanied by epileptiform EEG



Correspondence:

Nese Dericioglu
Hacettepe University Hospitals,
Department of Adult Neurology,
Sihhiye 06100,
Ankara, Turkey
<neseDericioglu@yahoo.com>

discharges, the scenario is termed “myoclonic status epilepticus”. This is reported to occur in 30-40% of comatose adult survivors of cardiopulmonary resuscitation (CPR) (Venkatesan and Frucht, 2006). The EEG findings may vary in time, however, generalized periodic discharges or a burst-suppression pattern are frequently encountered (Thömke *et al.*, 2002). The entity is generally difficult to control with medications and is usually associated with a grave prognosis. Autopsy findings in these patients are consistent with severe neuronal injury in the cerebral cortex, deep grey matter, hippocampus and cerebellum (Hui *et al.*, 2005). Here, we present repetitive paroxysms of eyelid opening and upward eye deviation, accompanied by a burst-suppression EEG pattern, in a patient with hypoxic-ischaemic brain injury. To the best of our knowledge, this peculiar sign has only rarely been described (Wolf, 1977; McCarty and Marshall, 1981; Jordan *et al.*, 1982; Mori *et al.*, 1983; Nelson *et al.*, 1986; Reeves *et al.*, 1997; Thömke *et al.*, 2002; Fernandez-Torre *et al.*, 2008; Ferrara *et al.*, 2012).

Case study

A 72-year-old female patient with amyotrophic lateral sclerosis developed cardio-pulmonary arrest soon after her arrival to the hospital with severe respiratory insufficiency. She responded quickly to CPR and spontaneous systemic circulation was re-established within two minutes. However, she did not wake up; neurological examination revealed a GCS score of 3/15, along with preserved brain stem reflexes. The following day, she was noted to have periodic eye opening and upward eye deviation without other accompanying clinical signs. In order to rule out the presence of non-convulsive status epilepticus, she underwent long-term video-EEG monitoring in the intensive care unit. At the onset of recording (31 hours after cardiac arrest), she was reported to have generalized high-amplitude spike-and-sharp-wave complexes, lasting 1-2.5 seconds, that recurred every 15-21 seconds on a low-amplitude background activity (*figure 1A*). Her eyes opened and deviated upwards, 450-500 msec-onds after the onset of generalized epileptic activity, followed by eye closure at or within 0.5-1 seconds of cessation of discharges. The prolonged rhythmic character of the discharges was clearly demonstrated by amplitude-integrated EEG (*figure 2A*). Due to the epileptic nature of these findings, the patient was administered a loading dose of 3000 mg of IV levetiracetam (LEV), followed by a 2 × 1500-mg maintenance dose. Eye opening and upward deviation ceased 12 hours after the initiation of LEV, despite continuing discharges that recurred more frequently, every 5-7 seconds (*figure 2B*). Eight hours after drug load-

ing, infrequent isolated sharp waves were also noticed over the left frontal area. These discharges became more frequent with time, assuming a periodic character within three hours, and at times were accompanied by less common right frontal sharp waves, giving the impression of bilateral independent periodic discharges or BIPDs (*figure 1B*; 50 hours after arrest). The periodic generalized activity became less intensive, with shorter duration and lower amplitude, eventually turning into infrequent, brief slow wave paroxysms that ceased altogether, approximately 18 hours after IV loading of LEV, and were followed by disappearance of periodic lateralized discharges within a couple of hours (*figure 2C*). The frequency of EEG discharges at any time during the recording did not correlate with the heart rhythm. Cranial MR imaging, obtained one week after the arrest, revealed widespread hypoxic damage of the cerebral cortex and basal ganglia. The patient did not regain consciousness and died of multiple organ failure with septic origin, 75 days after admission.

Discussion

Involvement of the levator palpebrae superioris or other extraocular muscles in patients suffering from post-anoxic coma has been previously reported in several cases (Wolf, 1977; McCarty and Marshall, 1981; Jordan *et al.*, 1982; Mori *et al.*, 1983; Nelson *et al.*, 1986; Reeves *et al.*, 1997; Thömke *et al.*, 2002; Fernandez-Torre *et al.*, 2008; Ferrara *et al.*, 2012). Of these, vertical eye movements accompanied by eyelid opening were reported in seven patients (McCarty and Marshall, 1981; Jordan *et al.*, 1982; Mori *et al.*, 1983; Reeves *et al.*, 1997; Ferrara *et al.*, 2012) and involvement of jaw muscles or swallowing movements reported in five patients (Wolf, 1977; Reeves *et al.*, 1997; Fernandez-Torre *et al.*, 2008). At this point, one could argue that the lack of generalized jerks in our patient could be assigned to motor weakness, secondary to amyotrophic lateral sclerosis. However, prior to admission, she was not totally paretic and might still have been able to demonstrate convulsive activity. Our case, together with the similar previous cases, expands the spectrum of post-resuscitation myoclonus syndromes with the addition of this rare isolated oculopalpebral subtype. It has been previously argued whether eyelid opening and closing associated with generalized burst activity is a convulsive manifestation or a release phenomenon (McCarty and Marshall, 1981). Wolf proposed that periodic synchronous and stereotyped myoclonus after post-anoxic coma originates in the upper oblongata (Wolf, 1977); whereas Ferrara *et al.* suggested that injury to structures within or above the upper midbrain might play a role (Ferrara *et al.*, 2012).

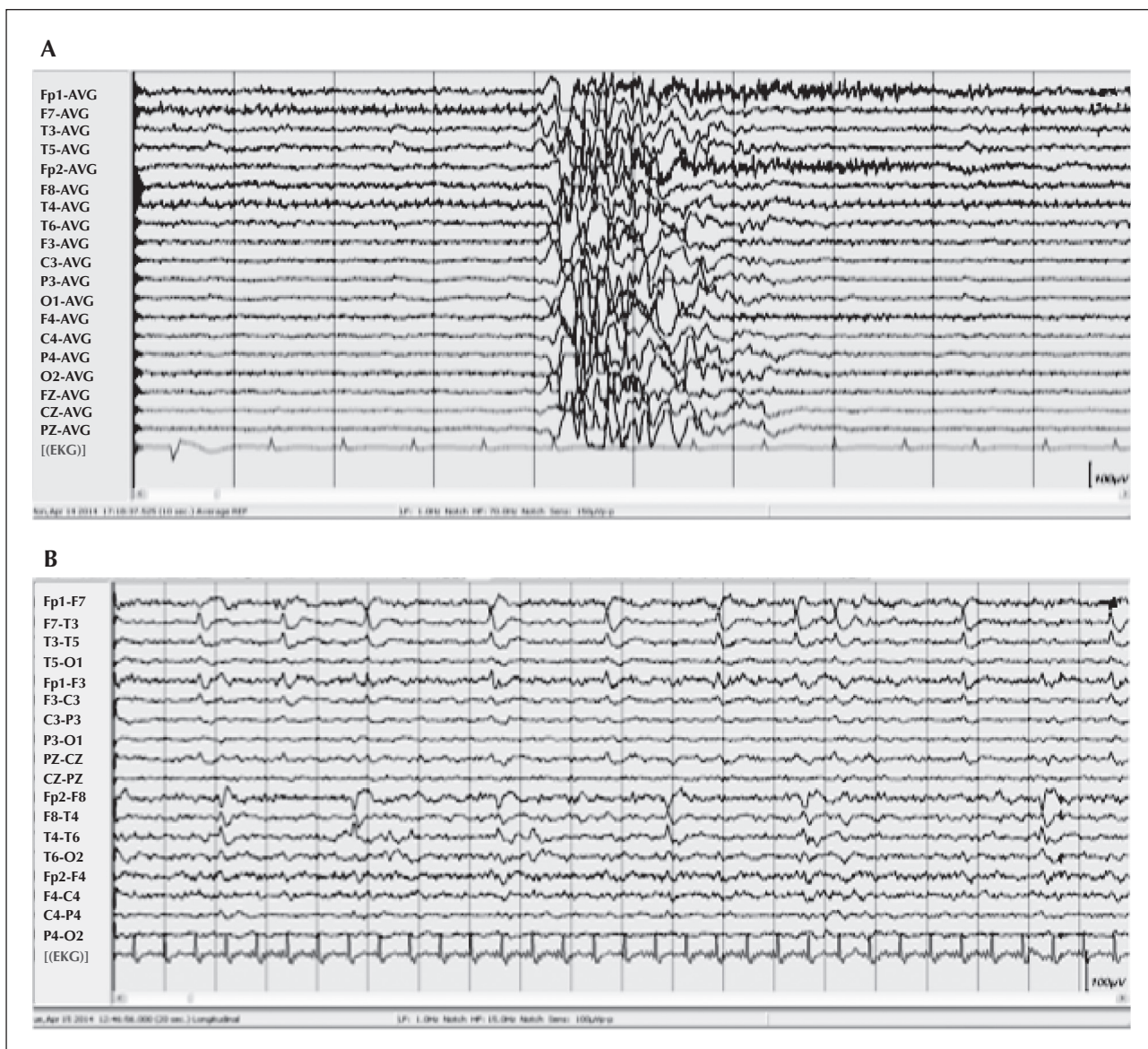


Figure 1. (A) Referential montage, depicting generalized high-amplitude slow waves, mixed with sharp waves and spikes on a low-amplitude background activity, consistent with a burst-suppression pattern (31 hours after cardiac arrest). High-pass filter: 1.0 Hz; low-pass filter: 70 Hz; notch filter: 50 Hz; vertical bar: 100 μ V; recording speed: 10 sec/page. (B) Bilateral independent periodic discharges with maximum negativity in the frontal leads (50 hours after arrest). High-pass filter: 1.0 Hz; low-pass filter: 15 Hz; notch filter: 50 Hz; vertical bar: 100 μ V; recording speed: 10 sec/page.

Due to widespread cortical damage, it has also been postulated previously that myoclonic activity is generated by a released brainstem “pacemaker” (Hallett, 2000). However, in post-hypoxic myoclonus, cortical myoclonus may coexist with brainstem myoclonus (Borg, 2006). Besides, a sufficient number of cortical pyramidal neurons have to be activated in order for scalp EEG to reflect epileptiform discharges. Although not a proof of concept, the long-lasting and strictly periodic nature of EEG discharges, as evidenced by digital trend analysis methods in our patient, also sug-

gests that these burst activities were correlated with a generator that has inherent rhythmic oscillatory capabilities. Such pacemakers are usually located within the brainstem nuclei or thalamus. Tonic or clonic upward eye deviation, on the other hand, have also been observed shortly after the onset of EEG discharges during absence seizures that are thought to occur as a result of thalamo-cortical activation (Bogacz *et al.*, 2000). The burst-suppression pattern has also been attributed in some cases to recurrent activation of thalamo-cortical networks (Chatrian and Turella, 2003).

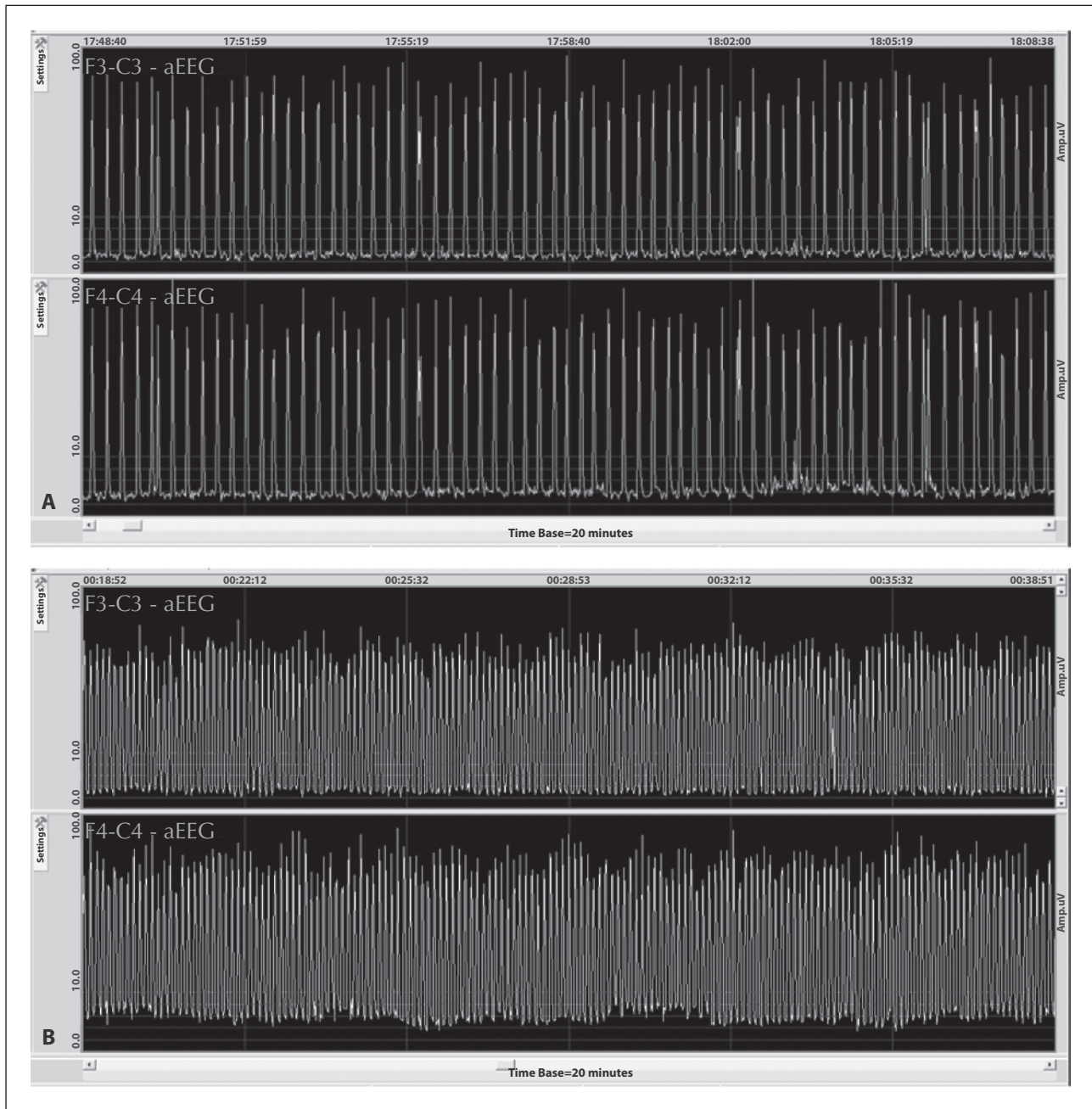


Figure 2. (A) Amplitude-integrated EEG involving F3-C3 and F4-C4 channels reveal the periodic nature of discharges shown in figure 1, that tend to recur every 15-21 seconds. (B) Generalized periodic discharges occurring more frequently, every 5-7 seconds.

Interestingly, however, Steriade and co-workers have previously shown in anaesthetized cats that almost 95% of cortical cells entered burst-suppression, closely related in time to already synchronized EEG activity, compared to only 60-70% of thalamic cells (Steriade *et al.*, 1994). Also, in a study based on chick spinal cord, it was reported that cycling activity can arise from the interplay between excitatory connectivity

and fast synaptic depression; *i.e.*, the activity does not depend on specialized connectivity or intrinsic bursting neurons and is generated by a network of functionally excitatory connections (Tabak *et al.*, 2000). Whether a similar mechanism in severely damaged cortex may lead to transient burst-suppression pattern in humans is an intriguing possibility. Recently, van Putten and van Putten modelled burst scalp EEG

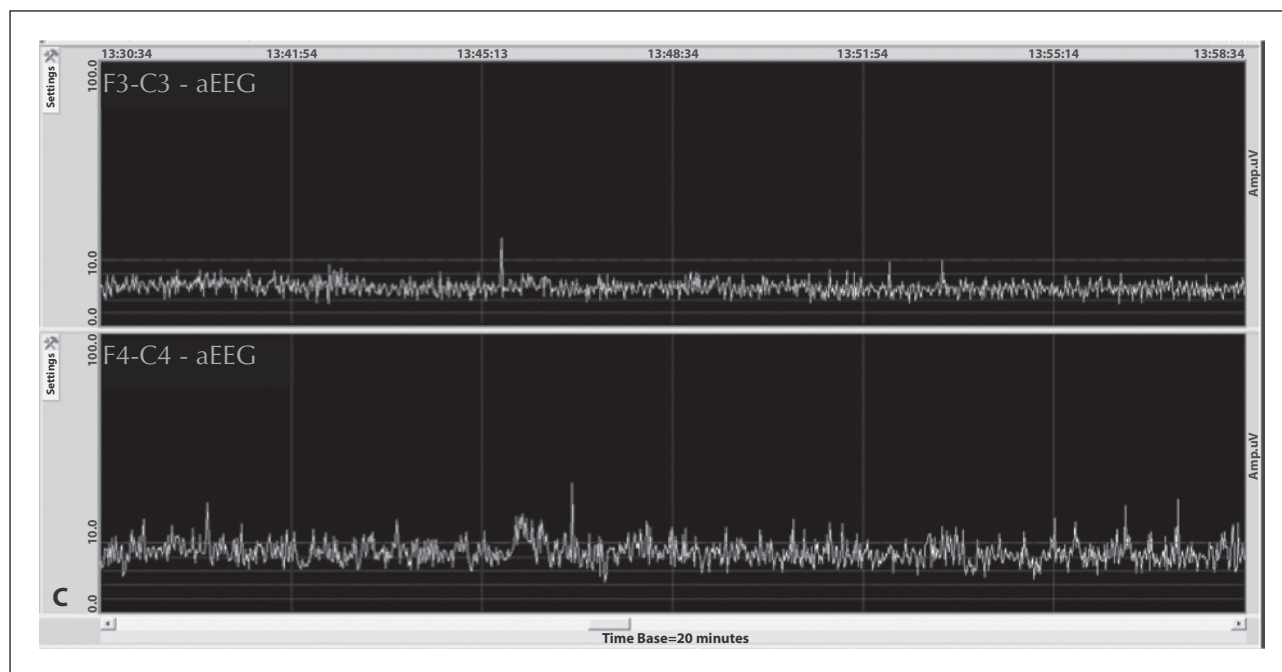


Figure 2. (Continued). (C) Cessation of generalized periodic activity (time base: 20 minutes).

activity in two patients with post-anoxic encephalopathy using different parameters, such as activity of a recurrent excitatory network, neuronal connectivity, and fast and slow synaptic depression, indicating that this brain state is low dimensional and correlates with irreversible loss of brain function and consciousness (van Putten and van Putten, 2010). The mechanisms determining the quasi-periodicity of bursts have been linked to hyperexcitability which results from reduction of cortical inhibition due to decreased activity of GABA-A inhibitory synapses and leads to excitatory-inhibitory imbalance, leaning towards excitation (Amzica, 2009). It is thought that the burst process is self-limited in time because of depletion in extracellular cortical calcium levels that are incompatible with synaptic transmission, thus leading to flat EEG. Neuronal pumps that restore interstitial calcium levels allow for the next cycle to reoccur. Loss of the integrity of the blood-brain barrier after severe hypoxia may impair the ability of the nervous system to maintain extracellular calcium, and perhaps other ionic concentrations, at normal levels (Amzica, 2009). Together with ongoing neuronal loss, this may cause altered temporal EEG dynamics (Thömke *et al.*, 2002) in patients with post-anoxic burst-suppression EEG. Taken together, all these findings suggest that a sub-cortical/brainstem pacemaker may trigger discharges in the cortex, or, alternatively, increased excitability and bursts in viable cortical neurons may lead to the observed burst-suppression pattern. Eye opening and upward eye deviation are probably secondary to exci-

tation of the relevant cortical areas with involvement of part of the oculomotor nucleus.

Both the clinical features and EEG findings (burst-suppression) were abolished by propofol infusion in one of the previous cases (Fernandez-Torre *et al.*, 2008). We did not wish to treat our patient aggressively and instead proceeded treatment with intravenous anti-convulsants. Levetiracetam is also known to possess anti-myoclonic activity. Several hours after drug infusion, both eyelid opening with upward eye deviation, and then burst-suppression, were abolished. Interestingly, however, the generalized discharges became more frequent soon after LEV infusion, and then transformed into BIPDs. It may be that the evolving EEG findings were a reflection of the natural course of the post-anoxic state, although this evolution pattern was not similar to those described previously by Thömke and co-workers (Thömke *et al.*, 2002). Whether LEV influenced EEG patterns (and if so, how?) in our patient is a matter of debate, since it has been shown previously that eye opening (Jordan *et al.*, 1982; Ferrara *et al.*, 2012) or burst-suppression (Jordan *et al.*, 1982) could also cease spontaneously within one day. The eyelid-opening phenomenon in comatose post-hypoxic patients has been accepted as an ominous sign in previous publications in which most of the patients were reported to die within 1-9 days. Unlike these cases, our patient survived much longer in the intensive care unit, and died due to other reasons, not primarily of hypoxic-ischaemic encephalopathy. Similar to our patient, several authors have described cases

that survived beyond the acute post-hypoxic phase (Jordan *et al.*, 1982; Mori *et al.*, 1983; Thömke *et al.*, 2002; Bouwes *et al.*, 2012), arguing that EEG burst-suppression associated with eye opening does not necessarily imply imminent death.

In summary, paroxysms of eye opening and vertical eye deviations may occur in isolation after hypoxic-ischaemic brain injury. Prolonged video-EEG monitoring clearly indicates this infrequent clinical entity, demonstrating its temporal relationship with EEG discharges. It is still not clear whether burst-suppression (with or without periodic oculomotor manifestations) after ischaemia originates from activation of a subcortical/brainstem pacemaker that reciprocally stimulates the cortex, or occurs due to quasi-rhythmic burst activity of viable cortical neural networks. □

Acknowledgements and disclosures.

This study was supported by Hacettepe University Research Fund Grant No. 1-801 105 001 (Dr. Nese Dericioglu).

The authors have no conflicts of interest to disclose.

Legend for video sequence

Periodic eye opening and upward eye deviation, without other motor manifestations, recurring every 15-21 seconds, and accompanied by a burst-suppression pattern on EEG.

Key words for video research on www.epilepticdisorders.com

Phenomenology: anoxic seizure; eye deviation

Localisation: not applicable

Epilepsy syndrome: epileptic encephalopathy not otherwise classified

Aetiology: hypoxic-ischemic encephalopathy

References

- Amzica F. Basic physiology of burst-suppression. *Epilepsia* 2009; 50(12): 38-9.
- Bogacz J, Bogacz D, Bogacz A. Oculomotor phenomena in petit-mal. *Clin Neurophysiol* 2000; 111: 959-63.
- Borg M. Symptomatic myoclonus. *Neurophysiol Clin* 2006; 36: 309-18.
- Bouwes A, van Poppel D, Koelman JH, *et al.* Acute posthypoxic myoclonus after cardiopulmonary resuscitation. *BMC Neurol* 2012; 12: 63.
- Chatrian GE, Turella GS. Electrophysiological evaluation of coma, other states of diminished responsiveness, and brain death. In: Ebersole JS, Pedley TA. *Current practice of clinical electroencephalography*. Philadelphia: Lippincott Williams and Wilkins, 2003: 405-62.
- Fernandez-Torre JL, Calleja J, Infante J. Periodic eye opening and swallowing movements associated with postanoxic burst-suppression EEG pattern. *Epileptic Disord* 2008; 10(1): 19-21.
- Ferrara JM, Houghton DJ, Rao S. Periodic eyelid opening associated with burst-suppression electroencephalography due to hypoxic ischemic injury. *Neurocrit Care* 2012; 17: 408-11.
- Hallett M. Physiology of human posthypoxic myoclonus. *Mov Disord* 2000; 15(1): 8-13.
- Hui ACF, Cheng C, Lam A, Mok V, Joynt GM. Prognosis following postanoxic myoclonus status epilepticus. *Eur Neurol* 2005; 54: 10-3.
- Jordan JE, Parrish DC, Cliett JB, Isbell SA. Suppression burst associated with eye opening. *Arch Neurol* 1982; 39(9): 602.
- McCarty GE, Marshall DW. Transient eyelid opening associated with postanoxic EEG suppression-burst pattern. *Arch Neurol* 1981; 38: 754-6.
- Mori E, Yamadori A, Tsuruta H, Ogawa K. Transient eye opening with EEG suppression-burst pattern in postanoxic encephalopathy. *Arch Neurol* 1983; 40: 189.
- Nelson KR, Brenner RP, Carlow TJ. Divergent-convergent eye movements and transient eyelid opening associated with an EEG burst-suppression pattern. *J Clin Neuroophthalmol* 1986; 6: 43-6.
- Reeves AL, Westmoreland BF, Klass DW. Clinical accompaniments of the burst-suppression EEG pattern. *J Clin Neurophysiol* 1997; 14: 150-3.
- Steriade M, Amzica F, Contreras D. Cortical and thalamic cellular correlates of electroencephalographic burst-suppression. *Electroencephalogr Clin Neurophysiol* 1994; 90: 1-16.
- Tabak J, Senn W, O'Donovan MJ, Rinzel J. Modeling of spontaneous activity in developing spinal cord using activity-dependent depression in an excitatory network. *J Neuroscience* 2000; 20(8): 3041-56.
- Thömke F, Brand A, Wielemann SL. The temporal dynamics of postanoxic burst-suppression EEG. *J Clin Neurophysiol* 2002; 19(1): 24-31.
- van Putten MJAM, van Putten MHPM. Uncommon EEG burst-suppression in severe postanoxic encephalopathy. *Clin Neurophysiol* 2010; 121: 1213-9.
- Venkatesan A, Frucht S. Movement disorders after resuscitation from cardiac arrest. *Neurol Clin* 2006; 24: 123-32.
- Wolf P. Periodic synchronous and stereotyped myoclonus with postanoxic coma. *J Neurol* 1977; 215: 39-47.

TEST YOURSELF



- (1) What are the movement disorders that can be observed after hypoxic-ischaemic brain injury?
- (2) What are the mechanisms of burst-suppression pattern, with or without periodic eye opening, after cardiac arrest?
- (3) How should we approach a patient with burst-suppression EEG and periodic eye opening movements?
- (4) Does periodic eye opening after cardiac arrest has a prognostic value?