

Transient Visual Hallucinations due to Posterior Callosal Stroke

Gaurav Nagarajan Ghosh, MBBS,* Victor Wycoco, FRANZCR,†
and Soumya Ghosh, FRACP*‡

Background: Stroke of the corpus callosum is uncommon, known to be associated with disturbance of higher brain function including hemifacial metamorphosis, but has never been reported to cause visual hallucinations. **Methods:** We report on a case of a 71-year-old woman who presented to the emergency department with a 3-day history of intermittent, formed visual hallucinations in the left visual field, often triggered by eye closure or darkness. **Results:** Neurologic examination was normal including cognition and affect, visual acuity, and visual fields. Electroencephalogram was normal. Magnetic resonance imaging scan of her brain showed a small stroke in the right inferior forceps major. Hallucinations resolved on day 2 of her admission, and she remains well more than a year later. **Conclusions:** This is the first report of transient visual hallucinations after a callosal stroke, which is an uncommon territory of stroke and a rare presentation of stroke. **Key Words:** Stroke—corpus callosum—forceps major—visual hallucinations.
Crown Copyright © 2015 Published by Elsevier Inc. on behalf of National Stroke Association. All rights reserved

A 71-year-old woman presented to the emergency department with a 3-day history of transient formed visual hallucinations in the left visual field. The symptoms were of sudden onset noticed on waking. She described seeing vivid images of people, buses, children in the playground, flowers in a vase, and other scenes in her left visual field, some recognizable and others not. She did not report any metamorphosis. She saw the images infre-

quently when her eyes were open but they became more frequent when her eyes were closed or when she was in the dark. There were no other neurologic symptoms. Medical history was significant for hypertension, type 2 diabetes mellitus, Crohn's disease, and asthma. Medications on admission were irbesartan, metformin, linagliptin, mesalazine, and inhaled budesonide and formoterol. On examination, she had normal attention, concentration, memory, and affect. There were no visual field defects, and funduscopy was normal. There was no difficulty with naming objects. She had normal eye movements and normal visual acuity with prescription glasses. The rest of the neurologic examination was normal.

Magnetic resonance imaging brain scan (Fig 1) revealed a focus of fluid-attenuated inversion recovery signal hyperintensity in the right inferior forceps major posterior to the right ventricular trigone associated with diffusion restriction and minimal mass effect. This was not seen on the computerized tomography scan. Magnetic resonance angiography did not show any evidence of focal stenosis or occlusion of arteries. Electroencephalogram was normal (including episodes of visual hallucinations). Visual hallucinations resolved on day 2 of her admission,

From the *Department of Neurology, Sir Charles Gairdner Hospital, Nedlands, Western Australia; †Department of Neuroradiology, Sir Charles Gairdner Hospital, Nedlands, Western Australia; and ‡Centre for Restorative Neurology, WA Neuroscience Research Institute, QEII Medical Centre, Nedlands, Western Australia, Australia.

Received January 22, 2015; revision received February 5, 2015; accepted February 10, 2015.

No financial interest or conflict of interest declared by authors.

Address correspondence to Soumya Ghosh, FRACP, Department of Neurology, Sir Charles Gairdner Hospital, Hospital Avenue, Nedlands, WA 6009, Australia. E-mail: Soumya.Ghosh@health.wa.gov.au.
1052-3057/\$ - see front matter

Crown Copyright © 2015 Published by Elsevier Inc. on behalf of National Stroke Association. All rights reserved

<http://dx.doi.org/10.1016/j.jstrokecerebrovasdis.2015.02.012>

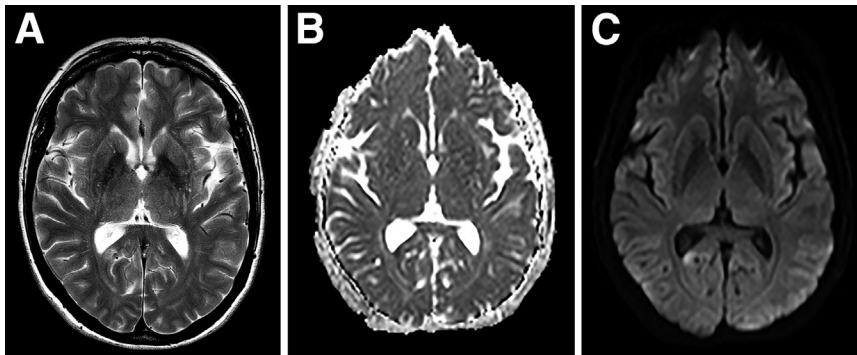


Figure 1. MRI brain scan. MRI (1.5 T) scan (transverse sections) of the brain showing a left posterior callosal (forceps major) lesion, hyperintense in the FLAIR (A) and diffusion-weighted (C) images and with decreased ADC values (B). Abbreviations: ADC, apparent diffusion coefficient; FLAIR, fluid-attenuated inversion recovery; MRI, magnetic resonance imaging.

and headache improved over the next few days. She was discharged on clopidogrel, atorvastatin, and vitamin D and calcium supplements. At 1-month follow-up and then 1 year later, she had no recurrence of her symptoms.

Lesions of the corpus callosum are known to produce disturbance of higher brain function such as left hand apraxia (constructional and ideomotor), agraphia, alien hand syndrome, hemifacial metamorphosis, tactile and visual anomia, and auditory extinction.¹⁻³ Stroke of the posterior corpus callosum is a rare clinical entity.¹ To our knowledge, this is the first report of visual hallucinations caused by an acute posterior corpus callosum infarction or lesion. Lesions of the splenium of the corpus callosum have been reported to cause limb paresthesia and hypesthesia,^{4,5} headache, dysarthria, and encephalopathy (altered behavior and confusion).^{6,7} Unilateral hemorrhage or infarction of the splenium, retrosplenial area, and forceps major has been described to cause transient hemifacial metamorphosis involving the opposite half of the face.^{2,3} In this study, right retrosplenial infarct caused visual hallucinations in the contralateral visual field. Visual hallucinations are rarely described after stroke (eg, peduncular hallucinosis), but more often likely to be ascribed to seizures, psychosis, or cognitive disturbance.⁸ Lesions that cause deafferentation of the visual system may lead to cortical release phenomenon, including visual hallucinations.⁹ The loss of callosal visual afferents to the occipital cortex may cause transient visual symptoms in the contralateral field as shown in this and previous studies.^{2,3}

Acknowledgments: The patient gave informed consent to publish the case report without identifying her. The au-

thors thank her and all the health personnel involved in her care during her hospital admission.

References

1. Giroud M, Dumas R. Clinical and topographical range of callosal infarction: a clinical and radiological correlation study. *J Neurol Neurosurg Psychiatry* 1995; 59:238-242.
2. Ebata S, Ogawa M, Tanaka Y, et al. Apparent reduction in the size of one side of the face associated with a small retrosplenial haemorrhage. *J Neurol Neurosurg Psychiatry* 1991;54:68-70.
3. Saito Y, Matsunaga A, Yamamura O, et al. A case of left hemi-facial metamorphosis induced by infarction of the right side of the splenium of the corpus callosum. *Rinsho Shinkeigaku* 2014;54:637-642.
4. Bocher AL, Caron S, Cordonnier C. Transient splenial DWI abnormality of the corpus callosum during a stroke-like episode. *Acta Neurol Belg* 2008;108: 27-28.
5. Chang TP, Huang CF. Unilateral paresthesia after isolated infarct of the splenium: case report. *Acta Neurol Taiwan* 2010;19:116-119.
6. Singh P, Gogoi D, Vyas S, et al. Transient splenial lesion: further experience with two cases. *Indian J Radiol Imaging* 2010;20:254-257.
7. Park MK, Hwang SH, Jung S, et al. Lesions in the splenium of the corpus callosum: clinical and radiological implications. *Neurology Asia* 2014;19: 79-88.
8. Teeple RC, Caplan JP, Stern TA. Visual hallucinations: differential diagnosis and treatment. *Prim Care Companion J Clin Psychiatry* 2009;11:26-32.
9. Burke W. The neural basis of the Charles Bonnet hallucinations: a hypothesis. *J Neurol Neurosurg Psychiatry* 2002; 73:535-541.