

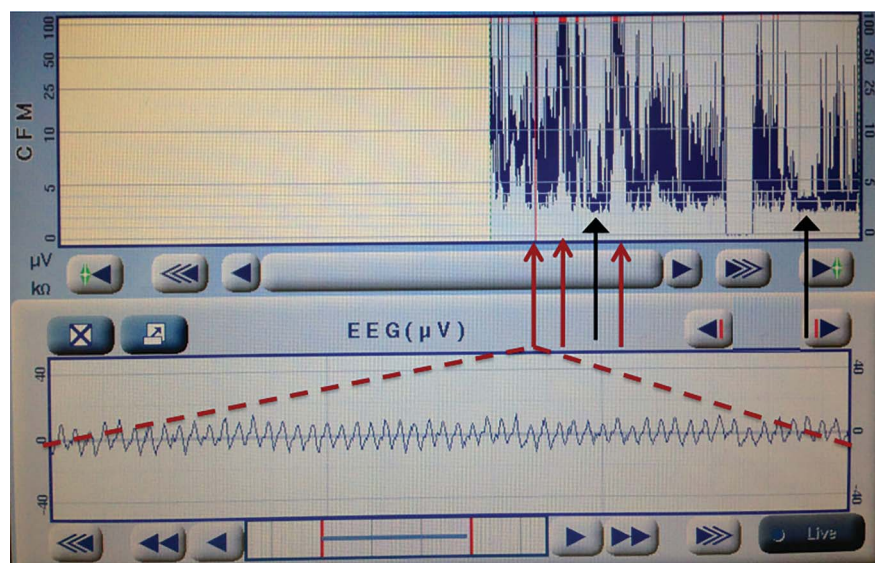
# Teaching Video *NeuroImages*: Nonepileptic myoclonus in a neonate following severe hypoxic-ischemic injury



Brian H. Walsh, MB  
BCh, PhD  
Fiona M. Baumer, MD  
Miya E. Bernson-Leung,  
MD  
Paul Lerou, MD  
Jurriaan M. Peters, MD

Correspondence to  
Dr. Walsh:  
brian.walsh2@childrens.harvard.  
edu

**Figure** Amplitude-integrated EEG



Amplitude-integrated EEG monitoring shows transient increases in amplitude concerning for possible seizures (red arrows) in contrast to baseline (black arrows). Concurrent raw EEG trace (dashed lines) shows an intermittent rhythmic pattern time-locked to the paroxysmal limb movements.

A newborn boy had a profound hypoxic-ischemic insult at birth. He developed rhythmic myoclonus within 1 hour, which was initially assumed to be seizures, but was unresponsive to escalating antiepileptic therapy. On careful examination, it was evident that myoclonus could be induced and suppressed. Amplitude-integrated (figure) and video EEG (video on the *Neurology*® Web site at Neurology.org) demonstrated a suppressed background with intermittent rhythmic pattern correlating with the movements. Laterality of this pattern changed with head positioning, suggesting artifact from pressure on dependent electrodes. Care was ultimately redirected when neuroimaging confirmed severe injury.

Nonepileptic myoclonus is a brainstem release phenomena<sup>1</sup> that can be difficult to distinguish from seizures without detailed clinical examination combined with EEG.<sup>2</sup> Timely diagnosis can prevent unnecessary treatment and can inform prognosis.

## AUTHOR CONTRIBUTIONS

Dr. Walsh drafted the manuscript, created the figure, and approved all final changes. Dr. Baumer edited the manuscript, created the PowerPoint, and approved all final changes. Dr. Bernson-Leung edited the manuscript and approved all final changes. Dr. Lerou edited the manuscript and approved all final changes. Dr. Peters edited the manuscript, created the video file, and approved all final changes.

## STUDY FUNDING

No targeted funding reported.

## DISCLOSURE

B. Walsh and F. Baumer report no disclosures. M. Bernson-Leung is a member of the Editorial Board of the *Neurology*® Resident & Fellow Section. P. Lerou and J. Peters report no disclosures. Go to Neurology.org for full disclosures.

## REFERENCES

1. Huntsman RJ, Lowry NJ, Sankaran K. Nonepileptic motor phenomena in the neonate. *Paediatr Child Health* 2008;13: 680–684.
2. Mizrahi EM, Kellaway P. Characterization and classification of neonatal seizures. *Neurology* 1987;37:1837–1844.

**Supplemental data**  
at **Neurology.org**

**Download teaching slides:**  
**Neurology.org**

From the Division of Newborn Medicine (B.H.W.) and the Department of Neurology (F.M.B., M.E.B.-L., J.M.P.), Boston Children's Hospital; and the Department of Pediatric Newborn Medicine (B.H.W., P.L.), Brigham and Women's Hospital, Boston, MA.

# Neurology®

**Teaching Video NeuroImages: Nonepileptic myoclonus in a neonate following severe hypoxic-ischemic injury**

Brian H. Walsh, Fiona M. Baumer, Miya E. Bernson-Leung, et al.

*Neurology* 2015;84:e90

DOI 10.1212/WNL.0000000000001397

**This information is current as of March 23, 2015**

*Neurology*® is the official journal of the American Academy of Neurology. Published continuously since 1951, it is now a weekly with 48 issues per year. Copyright © 2015 American Academy of Neurology. All rights reserved. Print ISSN: 0028-3878. Online ISSN: 1526-632X.



<b>Updated Information &amp; Services</b>	including high resolution figures, can be found at: <a href="http://www.neurology.org/content/84/12/e90.full.html">http://www.neurology.org/content/84/12/e90.full.html</a>
<b>Supplementary Material</b>	Supplementary material can be found at: <a href="http://www.neurology.org/content/suppl/2015/03/21/WNL.0000000000001397.DC1.html">http://www.neurology.org/content/suppl/2015/03/21/WNL.0000000000001397.DC1.html</a> <a href="http://www.neurology.org/content/suppl/2015/03/21/WNL.0000000000001397.DC2.html">http://www.neurology.org/content/suppl/2015/03/21/WNL.0000000000001397.DC2.html</a>
<b>References</b>	This article cites 2 articles, 1 of which you can access for free at: <a href="http://www.neurology.org/content/84/12/e90.full.html##ref-list-1">http://www.neurology.org/content/84/12/e90.full.html##ref-list-1</a>
<b>Subspecialty Collections</b>	This article, along with others on similar topics, appears in the following collection(s): <b>EEG</b> <a href="http://www.neurology.org/cgi/collection/eeg">http://www.neurology.org/cgi/collection/eeg</a> <b>Myoclonus</b> <a href="http://www.neurology.org/cgi/collection/myoclonus">http://www.neurology.org/cgi/collection/myoclonus</a> <b>Myoclonus; see Movement Disorders/myoclonus</b> <a href="http://www.neurology.org/cgi/collection/myoclonus_see_movement_disorders-myoclonus">http://www.neurology.org/cgi/collection/myoclonus_see_movement_disorders-myoclonus</a> <b>Neonatal</b> <a href="http://www.neurology.org/cgi/collection/neonatal">http://www.neurology.org/cgi/collection/neonatal</a> <b>Neonatal seizures</b> <a href="http://www.neurology.org/cgi/collection/neonatal_seizures">http://www.neurology.org/cgi/collection/neonatal_seizures</a>
<b>Permissions &amp; Licensing</b>	Information about reproducing this article in parts (figures,tables) or in its entirety can be found online at: <a href="http://www.neurology.org/misc/about.xhtml#permissions">http://www.neurology.org/misc/about.xhtml#permissions</a>
<b>Reprints</b>	Information about ordering reprints can be found online: <a href="http://www.neurology.org/misc/addir.xhtml#reprintsus">http://www.neurology.org/misc/addir.xhtml#reprintsus</a>

*Neurology*® is the official journal of the American Academy of Neurology. Published continuously since 1951, it is now a weekly with 48 issues per year. Copyright © 2015 American Academy of Neurology. All rights reserved. Print ISSN: 0028-3878. Online ISSN: 1526-632X.

