

## Intracerebral Hemorrhage due to Venous Thrombosis of Developmental Venous Anomaly during Pregnancy

Morinobu Seki, MD, PhD, Mamoru Shibata, MD, PhD, Yoshiaki Itoh, MD, PhD,  
and Norihiro Suzuki, MD, PhD

---

**Background:** Nowadays, developmental venous anomaly (DVA) is recognized as the most common cerebral vascular malformation. Most DVAs are diagnosed incidentally on routine brain imaging, but they are occasionally symptomatic. We report the case of a 26-year-old Japanese woman with intracerebral hemorrhage due to venous thrombosis of DVA. **Methods:** We examined her neurologic examinations carefully. We also observed her laboratory data, brain computed tomography (CT), and magnetic resonance imaging (MRI) findings. **Results:** She was 8 weeks pregnant and suffered from nausea, vomituration, and appetite loss because of hyperemesis gravidarum. She presented with a sudden generalized seizure and was referred to our hospital. Brain CT showed a small hemorrhage and a tubular high-density structure compatible with an acutely thrombosed collecting vein in the right frontal lobe. T2\*-weighted MRI also revealed a thrombosed collecting vein along with multiple medullary veins, which looked like caput medusa. She was diagnosed with an intracerebral hemorrhage and symptomatic epilepsy secondary to thrombosis of the DVA. After the acute phase of the disease, systemic anticoagulation therapy was administered to the patient to prevent the recurrence of venous thrombosis. We suspected that hyperemesis gravidarum with intravascular dehydration might have increased the risk of thrombosis in this patient. **Conclusions:** Thrombosis of the collecting vein of DVA is extremely rare. This is the first report regarding DVA thrombosis during pregnancy, to our knowledge. **Key Words:** Developmental venous anomaly—venous thrombosis—pregnancy—hemorrhage. © 2015 by National Stroke Association

---

Intracerebral developmental venous anomalies (DVAs) were once considered rare vascular malformations. However, since the introduction of computed tomography (CT) and magnetic resonance imaging (MRI), DVAs have become the most frequent cerebral vascular malformations, with a reported incidence of 2.6% in a series of 4069 brain autopsies.<sup>1</sup> Although they are asymptomatic and diagnosed incidentally in most cases, there are

some recent articles reporting that DVAs can cause neurologic symptoms.<sup>2</sup>

### Case Report

A 26-year-old Japanese woman who was 8 weeks pregnant had been suffering from nausea, vomituration, and appetite loss due to hyperemesis gravidarum. She was a

---

From the Department of Neurology, Keio University School of Medicine, Tokyo, Japan.

Received January 23, 2015; revision received February 10, 2015; accepted March 18, 2015.

This study was not sponsored or funded by any industry, government, or institution.

Address correspondence to Morinobu Seki, MD, PhD, Department of Neurology, Keio University School of Medicine, 35 Shinanomachi, Shinjuku-ku, Tokyo 160-8582, Japan. E-mail: [sekimori709@gmail.com](mailto:sekimori709@gmail.com). 1052-3057/\$ - see front matter

© 2015 by National Stroke Association

<http://dx.doi.org/10.1016/j.jstrokecerebrovasdis.2015.03.035>

primipara and had no history of miscarriages. She had no relevant medical history including thromboembolic diseases or family history. She suddenly lost her consciousness and developed a generalized seizure while she was riding her bicycle. She recovered spontaneously within a short time and showed no abnormal neurologic findings on arrival at the emergency room. A noncontrast brain CT scan performed after her informed consent was obtained showed a small hemorrhage and a large tubular hyperdense structure converging toward the superior sagittal sinus in the right frontal lobe (Fig 1, A). The subsequent MRI revealed a thrombosed collecting vein along with multiple medullary veins, which looked like caput medusa (Fig 1, B). No cavernous malformation was identified on MRI.

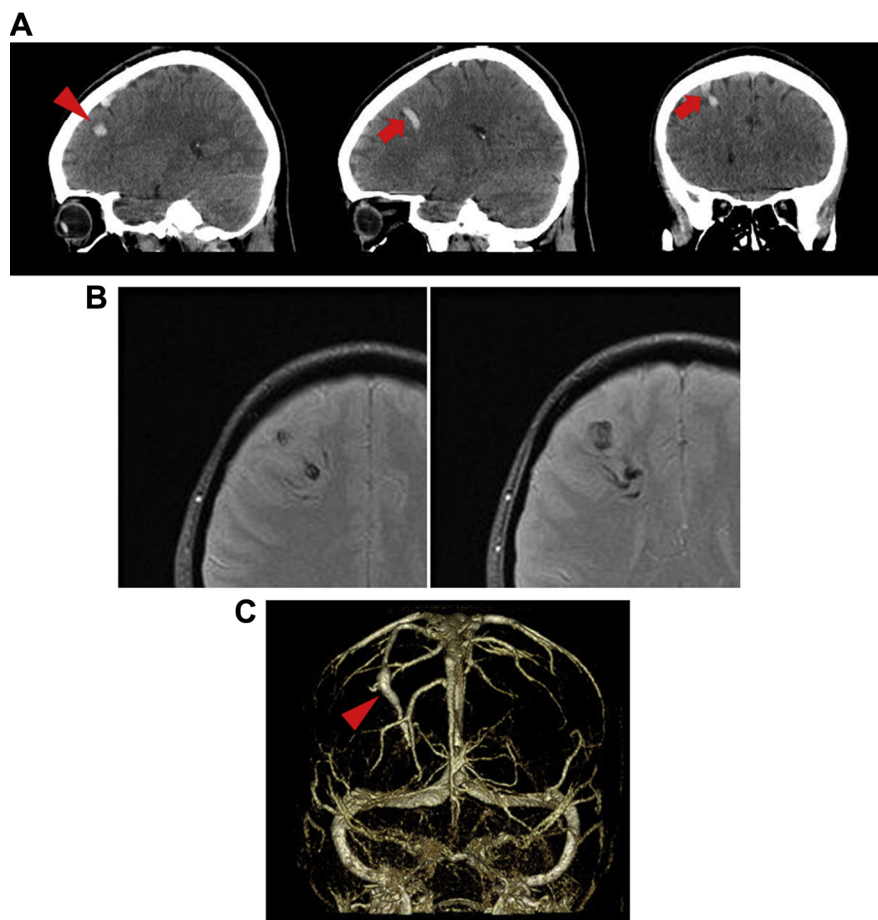
We diagnosed the patient with an intracerebral hemorrhage and symptomatic epilepsy secondary to thrombosis in the collecting vein of the DVA. Her laboratory findings showed elevated fibrin/fibrinogen degradation products (6.5  $\mu\text{g/mL}$ ), D-dimer (2.5  $\mu\text{g/mL}$ ), and thrombin-antithrombin complex (10.4  $\text{ng/mL}$ ), and the serum protein S level was low (38%). Other factors for thrombus formation, such as protein C, antithrombin III, antiphospholipid antibody, and anticardiolipin  $\beta_2$ -glycoprotein-1 complex antibody were within the normal range. As she had a

convulsive seizure again after admission, she was treated with an intravenous administration of phenytoin (250 mg/day). Anticoagulation therapy for venous thrombosis was not started immediately because of the possible expansion of the intracerebral hemorrhage.

After the patient was discharged without any neurologic deficits, a subcutaneous heparin calcium injection was administered to prevent the recurrence of venous thrombosis. Subcutaneous heparin injection of 10,000 U was started 1 month after the cerebral hemorrhage and discontinued before delivery. Activated partial thromboplastin time was monitored monthly to exclude overdose. After she had a normal delivery, we performed three-dimensional CT angiography, which confirmed the thrombosed collecting vein of the DVA (Fig 1, C).

## Discussion

DVAs are characterized by a cluster of venous radicles that converge into a dilated vein called the collecting vein and form the so-called caput medusa appearance.<sup>2</sup> After converging into a collecting vein, a DVA may drain centrifugally to the superficial cerebral venous system or centripetally to the deep venous system. Neuroimaging findings suggested the former mechanism in the



**Figure 1.** Noncontrast brain CT images (sagittal and coronal), brain MRI (T2\*-weighted image), and three-dimensional CT angiography. The sagittal noncontrast brain CT scan showed a small intracranial hemorrhage in the right frontal lobe (A, arrowhead). Coronal and sagittal noncontrast CT scans revealed a hyperdense tubular structure that was located dorsal to the hemorrhage and converged toward the superior sagittal sinus (A, arrow). This was consistent with acute thrombosis of the collecting vein in DVA. Axial T2\*-weighted MRI, which used a hemosiderin or deoxyhemoglobin-sensitive sequence, demonstrated a hypointense vascular structure in the right frontal lobe (B). It had a typical caput medusa appearance with some radiating medullary veins converging into one large collecting vein. No other vascular malformations were found. Three-dimensional CT angiography performed after the patient gave birth demonstrated the thrombosed collecting vein of the DVA (C, arrowhead). Abbreviations: CT, computed tomography; DVA, developmental venous anomaly; MRI, magnetic resonance imaging.

present case. Although DVAs are typically asymptomatic and follow a benign clinical course, they can occasionally develop neurologic symptoms.

Cavernous malformations, which are frequently associated with DVAs,<sup>3</sup> are now thought to be responsible for the vast majority of symptomatic DVA cases presenting with hemorrhage or seizure.<sup>4</sup> Quite rarely, DVAs may compress adjacent intracranial structures with the dilated collecting vein, resulting in neurologic symptoms. Thrombosis of the collecting vein of a DVA is extremely rare, but it may cause hemorrhage or ischemic infarction around a DVA. A review of the literature revealed 19 documented cases of symptomatic thrombosed DVAs presenting with venous ischemic infarction (53%), parenchymal hemorrhage (37%), or a subarachnoid or intraventricular hemorrhage (5%).<sup>2</sup>

Although the precise mechanism of thrombosis in DVA is still unclear, risk factors for cerebral venous sinus thrombosis may also be involved. In the present case, intravascular dehydration due to hyperemesis gravidarum during pregnancy might have increased the risk of thrombosis. The low concentration of protein S, which is often found in normal pregnancy, might also reflect acute thrombosis in the present case. Hereditary protein S deficiency is well known to cause venous thrombosis but may not be involved in the present patient because she had no notable medical history and no family history of thromboembolism. Only 5 case reports stated that the hypercoagulable state in the puerperium period or the use of an oral contraceptive might have contributed to the thrombosis of a DVA.<sup>5-9</sup> To our knowledge, thrombosis of DVA during the first trimester of pregnancy has never been reported.

As in most reported cases of thrombosed DVAs, the present patient was treated with anticoagulation after stabilization of the cerebral hemorrhage. Further large

studies are needed to assess the efficacy and safety and the optimal timing of systemic anticoagulation therapy for thrombosed DVAs.

In conclusion, a DVA may give rise to symptoms through thrombosis of the collecting vein triggered by a hypercoagulable state during pregnancy.

## References

1. Sarwar M, McCormick WF. Intracerebral venous angioma. Case report and review. *Arch Neurol* 1978;35:323-325.
2. Ruiz DS, Yilmaz H, Gailloud P. Cerebral developmental venous anomalies: current concepts. *Ann Neurol* 2009;66:271-283.
3. Huber G, Henkes H, Hermes M, et al. Regional association of developmental venous anomalies with angiographically occult vascular malformations. *Eur Radiol* 1996;6:30-37.
4. McLaughlin MR, Kondziolka D, Flickinger JC, et al. The prospective natural history of cerebral venous malformations. *Neurosurgery* 1998;43:195-200. discussion -1.
5. Hammoud D, Beauchamp N, Wityk R, et al. Ischemic complication of a cerebral developmental venous anomaly: case report and review of the literature. *J Comput Assist Tomogr* 2002;26:633-636.
6. Thobois S, Nighoghossian N, Mazoyer JF, et al. [Cortical thrombophlebitis and developmental venous anomalies]. *Rev Neurol (Paris)* 1999;155:48-50.
7. Yamamoto M, Inagawa T, Kamiya K, et al. Intracerebral hemorrhage due to venous thrombosis in venous angioma—case report. *Neurol Med Chir (Tokyo)* 1989;29:1044-1046.
8. Abarca-Olivas J, Botella-Asuncion C, Concepcion-Aramendia LA, et al. [Two cases of brain haemorrhage secondary to developmental venous anomaly thrombosis. Bibliographic review]. *Neurocirugia (Astur)* 2009;20:265-271.
9. Sepelyak K, Gailloud P, Jordan LC. Thrombosis of a developmental venous anomaly with hemorrhagic venous infarction. *Arch Neurol* 2010;67:1028.