

# Teaching NeuroImages: Acute generalized suppression on continuous EEG heralds clinical and radiologic deterioration

Tadeu Fantaneanu, MD  
Vincent Alvarez, MD  
Jong Woo Lee, MD, PhD

Correspondence to  
Dr. Lee:  
jlee38@partners.org

A 79-year-old woman was admitted to the hospital following 2 generalized tonic clonic seizures and a large right intracerebral hemorrhage (ICH). She deteriorated 72 hours later, losing her right pupillary reflex. A CT scan at that time showed stable ICH volume with effacement of the right suprasellar cistern, concerning for impending herniation. Interestingly, her continuous EEG (cEEG) showed a marked change 90 minutes prior to her clinical deterioration, characterized by acute generalized suppression of cerebral activity (figure). cEEG changes in patients with raised intracranial pressure vary by etiology, ranging from lateralized periodic discharges in the acute phase of injury to bifrontally predominant generalized rhythmic delta activity to suppression of EEG activity. cEEG changes may precede clinical and radiographic deterioration and should be followed closely in patients with elevated intracranial pressure (ICP).<sup>1</sup> Identification of cEEG changes in critically ill patients with changes in ICP should be treated with greater clinical vigilance and may lead to early interventions such as hyperosmolar therapy or even surgical interventions such as hematoma evacuation or decompressive craniectomy.<sup>2</sup>

## AUTHOR CONTRIBUTIONS

Dr. Fantaneanu contributed to the design/conceptualization of this study, interpretation of the data, and the drafting/revision of the manuscript. Dr. Alvarez contributed to the design/conceptualization of this study, interpretation of the data, and the drafting/revision of the manuscript. Dr. Lee contributed to the design/conceptualization of this study, interpretation of the data, and the drafting/revision of the manuscript. Dr. Lee has access to all the data and takes responsibility for the data, accuracy of the data analysis, and the conduct of this research.

## STUDY FUNDING

No targeted funding reported.

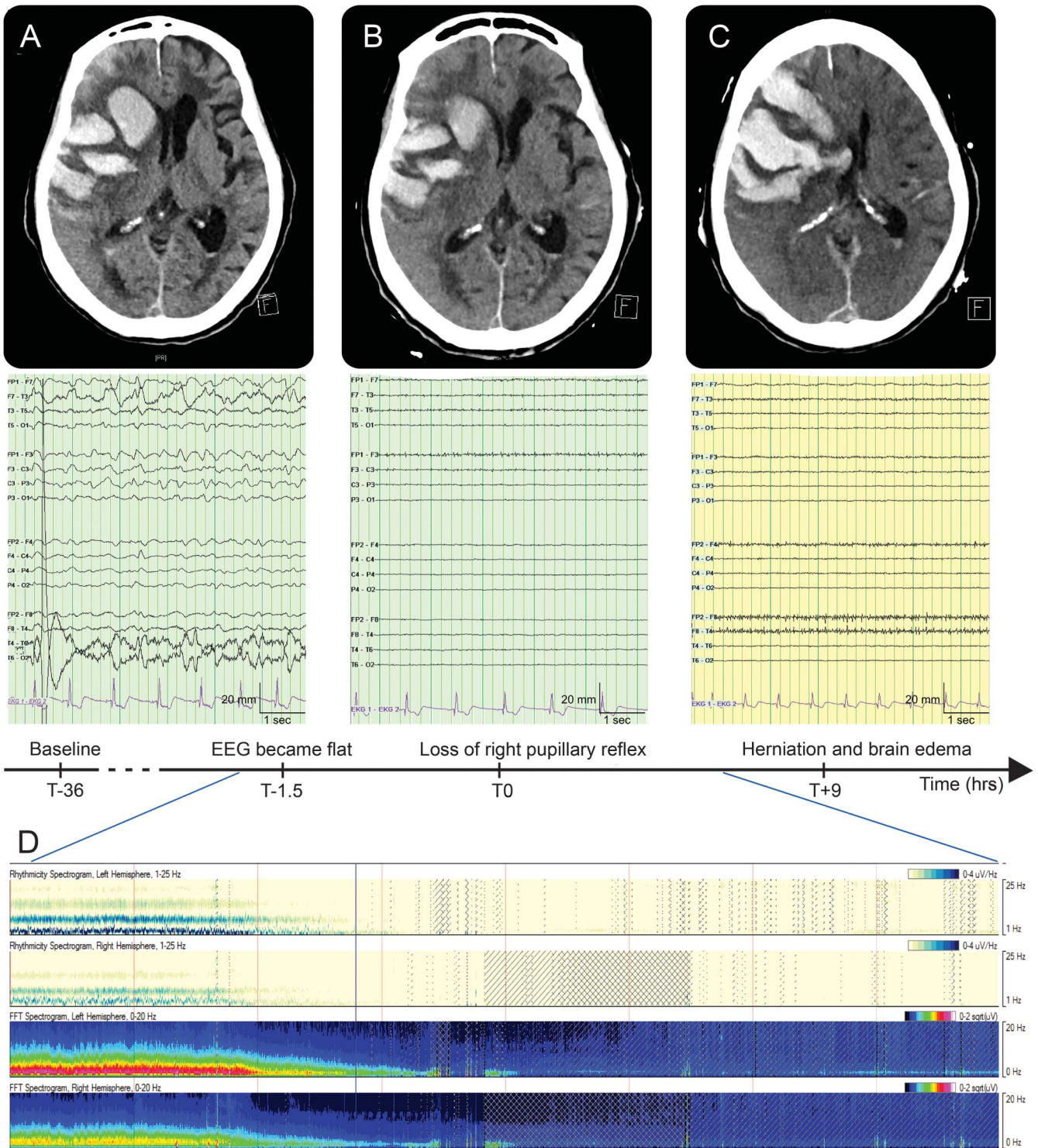
## DISCLOSURE

T. Fantaneanu and V. Alvarez report no disclosures relevant to the manuscript. J. Lee has received research funding from UCB, Inc., the Duke Clinical Research Institute, and Sunovion, Inc. He is a consultant for SleepMed/DigiTrace. Go to [Neurology.org](http://Neurology.org) for full disclosures.

## REFERENCES

1. Newey CR, Sarwal A, Hantus S. Continuous electroencephalography (cEEG) changes precede clinical changes in a case of progressive cerebral edema. *Neurocrit Care* 2013;18:261–265.
2. Perez-Barcena J, Llompart-Pou JA, O'Phelan KH. Intracranial pressure monitoring and management of intracranial hypertension. *Crit Care Clin* 2014;30:735–750.

**Figure** Timeline of radiographic and cEEG monitoring record with spectral analysis



(A) Admission CT: right intracerebral hemorrhage; continuous EEG (cEEG): paradoxical left lateralized periodic discharges and intermixed rhythmic delta activity as well as bilateral, but right greater than left, hemispheric slowing and attenuation. (B) CT at time of clinical change; cEEG: suppression. (C) Diffuse edema and herniation 9 hours later. (D) EEG spectral analysis (8 hours) shows loss of cerebral activity 1.5 hours before clinical change (T0).