



ELSEVIER

Contents lists available at ScienceDirect

Pediatric Neurology

journal homepage: www.elsevier.com/locate/pnu

Visual Diagnosis

“Wrong Side” Tongue Deviation in Hemiplegia From Stroke

Riddhiben Patel MD^{a,*}, Aimee F. Luat MD^b, Kumar Rajamani MD^c^a Pediatric Neurology Department, Children’s Hospital of Michigan, Detroit, Michigan^b Children’s Hospital of Michigan, Wayne State University School of Medicine, Detroit, Michigan^c Department of Neurology, Wayne State University School of Medicine, Detroit, Michigan

Patient description

A previously healthy 10-year-old right-handed male presented with acute left arm and leg weakness soon after football practice. Examination revealed dense left hemiplegia sparing the face associated with ipsilateral tongue deviation (Fig A), vertical upbeat nystagmus, left hyporeflexia, and a left Babinski reflex. Magnetic resonance imaging of the brain and cervical cord showed restricted diffusion and the corresponding hypointensity in the apparent diffusion coefficient at the left caudal anterior medulla and left anterolateral cervicomedullary junction resulting from acute ischemic infarction in left anterior spinal artery distribution (Fig B,C). An extensive stroke evaluation including magnetic resonance angiogram of intracranial vessels was unremarkable. One month later, tongue and limb weakness had improved considerably.

Discussion

Tongue deviation can result from a unilateral hypoglossal nerve lesion at its supranuclear, nuclear, or infranuclear location. Medullary lesions typically cause “crossed hemiplegia” with tongue weakness and deviation away from the hemiplegic side.¹ Supranuclear lesions cause contralateral hemiplegia with tongue deviation toward the hemiplegic side.² Our patient was unique and presented with hemiplegia (facial sparing) and tongue deviation to the hemiplegic side (ipsilateral glossoplegia). The ipsilateral glossoplegia was due to the involvement of the intramedullary portion of hypoglossal nerve in the caudal medulla. The left hemiplegia (without facial involvement) was presumably caused by a lesion of the pyramidal tract at the cervicomedullary junction after its medullary decussation.

There are no real or perceived potential conflicts of interest for any of the authors. The first draft was written by Dr. Patel and she received no honorarium, grant or any other form of payment to prepare this manuscript.

* Communications should be addressed to: Dr. Patel; Pediatric Neurology Department; Pediatric Neurology Resident; Children’s Hospital of Michigan; 3rd Floor Main Building; Detroit, MI.

E-mail address: drriddhu1734@gmail.com

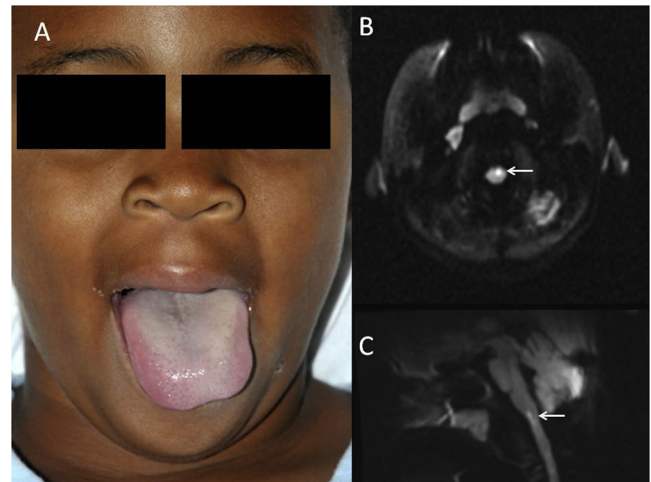


FIGURE.

(A) Tongue deviation to the left side. (B) Magnetic resonance imaging brain axial diffusion-weighted image showing hyperintensity (arrow) in the left caudal medulla. (C) Magnetic resonance imaging brain sagittal diffusion-weighted image showing hyperintensity (arrow) at the cervicomedullary junction. (The color version of this figure is available in the online edition.)

The pattern of ischemia noted on magnetic resonance imaging is in the distribution of the anterior spinal artery. Because the symptoms started soon after exercise, he could have experienced an arterial dissection although vascular imaging did not corroborate that.

This is the first description of a child with a stroke involving the left caudal medulla and cervicomedullary junction presenting with hemiplegia and tongue deviation ipsilateral to the lesion. Presence of glossoplegia ipsilateral to hemiplegia without facial weakness (or “wrong side” tongue deviation in hemiplegia) could point to an ipsilateral lesion of the caudal medulla and cervicomedullary junction. This child illustrates the importance of careful neuroanatomical evaluation of the side of tongue weakness and deviation to determine

appropriate neuroimaging in patients with suspected stroke.

The authors wish to acknowledge Dr. Salman Rashid, who provided images for the figure used in the article.

References

1. Brazis P, Masdeu JC, Biller J. *Localization in clinical neurology*. Philadelphia, PA: Lippincott Williams and Wilkins; 2011:377-379.
2. Umapathi T, Venketasubramanian N, Leck KJ, et al. Tongue deviation in acute ischaemic stroke: a study of supranuclear twelfth cranial nerve palsy in 300 stroke patients. *Cerebrovasc Dis*. 2000;10:462-465.