




ELSEVIER

Official Journal of the European Paediatric Neurology Society



Case Study

Hemispherotomy for isolated infantile spasms following perinatal ischemic stroke



Delphine Taussig^{a,*}, Georg Dorfmueller^{a,b,c,d}, Jessica Save^{a,b,c,d},
Martine Fohlen^a, Mathilde Chipaux^a, Sarah Ferrand-Sorbets^a,
Olivier Delalande^a, Christine Bulteau^{a,b,c,d}

^a Fondation Ophtalmologique A. de Rothschild, Pediatric Neurosurgery Department, 75019 Paris, France

^b Inserm U1129, “Infantile Epilepsies and Brain Plasticity” Paris, France

^c PRES, Sorbonne Paris Cité, France

^d CEA, Gif sur Yvette, France

ARTICLE INFO

Article history:

Received 27 August 2014

Received in revised form

11 January 2015

Accepted 11 April 2015

Keywords:

Infantile spasms

Middle cerebral artery stroke

EEG-video monitoring

Hemispherotomy

Neuropsychology

ABSTRACT

Background: Infantile spasms (IS) are a severe epileptic encephalopathy. In patients with early focal ischemia and refractory IS, a preoperative evaluation is required even if IS are the only ictal manifestation.

Methods: We report three such patients who presented with IS between 5 and 7 months of age without any other focal seizure types. Imaging exhibited a perinatal middle cerebral artery (MCA) stroke.

Results: All patients had hemiparesis and experienced psychomotor regression after the onset of IS. Scalp video-electroencephalogram (EEG) monitoring for presurgical assessment showed interictal and ictal EEG characteristics between the pathological and the healthy hemisphere and surgery was proposed despite the lack of any focal seizures. The three patients underwent hemispherotomy at a mean age of 27 months and became seizure-free without medication (follow-up 49–144 months). The two patients who underwent early hemispherotomy acquired normal verbal intelligence, whereas the third, operated on at 38 months of age, remained with severe mental retardation.

Conclusion: Early hemispherotomy in drug-resistant epilepsy related to a perinatal MCA may cure the seizures even if the patient has IS as sole type and prevent mental retardation in some children.

© 2015 European Paediatric Neurology Society. Published by Elsevier Ltd. All rights reserved.

* Corresponding author. Fondation Ophtalmologique A. de Rothschild, Pediatric Neurosurgery Department, 25 rue Manin, 75940 Paris Cedex 19, France. Tel.: +33 1 48036943; fax: +33 1 48036562.

E-mail address: dtaussig@fo-rothschild.fr (D. Taussig).

<http://dx.doi.org/10.1016/j.ejpn.2015.04.003>

1090-3798/© 2015 European Paediatric Neurology Society. Published by Elsevier Ltd. All rights reserved.

1. Introduction

Surgery for refractory infantile spasms (IS) related to various focal or hemispheric epilepsies has been increasingly performed in the last twenty years.² Infantile spasms (IS) are often associated with severe encephalopathy in infancy (West syndrome) but do not necessarily indicate generalized epilepsy.⁹ Patients must be considered as potential candidates for epilepsy surgery, particularly when MRI exhibits unilateral and/or focal abnormalities. A pre-surgical evaluation is required with clinical and neurological data, imaging, EEG and discussion with a multidisciplinary paediatric team to decide upon the appropriate surgical strategy among a variety of options.⁷ Hemispherotomy is an efficient treatment of drug-resistant epilepsy associated with perinatal stroke in terms of seizure outcome as well as development.⁶ However, pre-operative assessment of patients with isolated drug-resistant IS associated with perinatal stroke has seldom been described in detail and the long term evolution after hemispherotomy in this situation has been rarely addressed. We describe three patients with unilateral perinatal middle cerebral artery (MCA) stroke who presented refractory IS as the sole seizure type associated with cognitive regression. We performed the pre-surgical assessment at our institution, which gave us the opportunity to report the pattern of epileptiform discharges (interictal and ictal) and the longitudinal neuropsychological outcomes.

2. Case studies

We retrospectively analysed the files of three patients from a series of 215 who underwent hemispherotomy between 1990 and 2009. These three patients presented with IS without any focal seizures in the history apart from neonatal seizures. Magnetic resonance imaging (MRI) showed an MCA stroke without any other lesion (Fig. 1A). IS began between three and seven months of age and were associated with severe psychomotor regression, but none had hypsarrhythmia when IS began. Clinical evaluation revealed hemiparesis and probable lateral homonymous hemianopia contralateral to the damaged hemisphere and mild psychomotor delay. Prolonged EEG-video (3–4 days) recorded IS, and no other seizure type was recorded or suspected. All three patients underwent vertical parasagittal hemispherotomy (VPH) according to Delalande et al.'s procedure.³ Neurological status remained unchanged after surgery. All three patients became seizure free without any medication with a post-operative follow-up of 49–144 months. Long term cognitive outcome exhibited improvement in the two patients who underwent earlier VPH. Table 1 summarizes the clinical, neurophysiological and neuropsychological data.

2.1. Patient #1

She was born by caesarean section at full term with macrosomia. Apgar score was 8–10. At the age of three days she experienced right clonic seizures treated with phenytoin

followed with carbamazepine. At the age of 5 months epilepsy began with symmetric IS which did not respond to vigabatrin, carbamazepine or clobazam. At the age of 13 months, she could sit although balance was poor; she had good affective and visual contact but global psychomotor delay. She underwent left VPH at the age of 14 months. Drug treatment was stopped at the age of 25 months. At 13.2 years, she had recovered subnormal verbal intellectual efficiency, attended a special school and displayed no behavioural problems.

2.2. Patient #2

He was born after an uneventful pregnancy and full term delivery. Apgar score was 10/10. At the age of 4 months the mother noticed that he could not open his right hand, and at the age of 7 months a cerebral infantile hemiplegia was diagnosed. At this age development was normal, but he began to have IS, which remained unchanged until surgery. Despite treatment with steroids, vigabatrin, valproate and topiramate he had several clusters a day associated with severe cognitive regression. At the age of 21 months, although he could remain sitting, he could not sit or stand up by himself. He had good visual contact but could not play, and he had frequent stereotypies. He did not speak. Left VPH was performed at the age of 29 months. Treatment was stopped at the age of 3.5 years. At the age of 6.7 years, psychometric assessment showed normal intellectual efficiency with dissociation between verbal and non-verbal performance in favour of language abilities. He attended a regular school.

2.3. Patient #3

He was born at full term by caesarean section because of bradycardia and labour stagnation. Apgar score was 9–10. At the age of 3 days he had a poorly described episode with cyanosis. EEG recorded several seizures involving the right central region. Seizures were controlled by phenobarbital followed by valproate. At the age of 7 months epilepsy began with IS which were not controlled by vigabatrin, clonazepam, topiramate, valproate, or steroids. At this time he had a clear-cut left hemiparesis with stagnation of psychomotor development. At the age of 2.9 years, the child could not stand up alone but could walk independently since the age of 26 months, and IS caused traumatic falls. He had a good visual contact but a speech delay, producing only isolated words. He underwent right VPH at 3 years and 2 months. Drug treatment was stopped at the age of 3 years and 10 months. At 7.3 years he still had global impairment.

3. Discussion

We presented three patients with isolated IS related to a unilateral perinatal stroke whose seizures were treated by hemispherotomy. This report raises several questions: what were the criteria for hemispherotomy? Is surgery in this case as efficient as with focal seizures for epilepsy and for development?

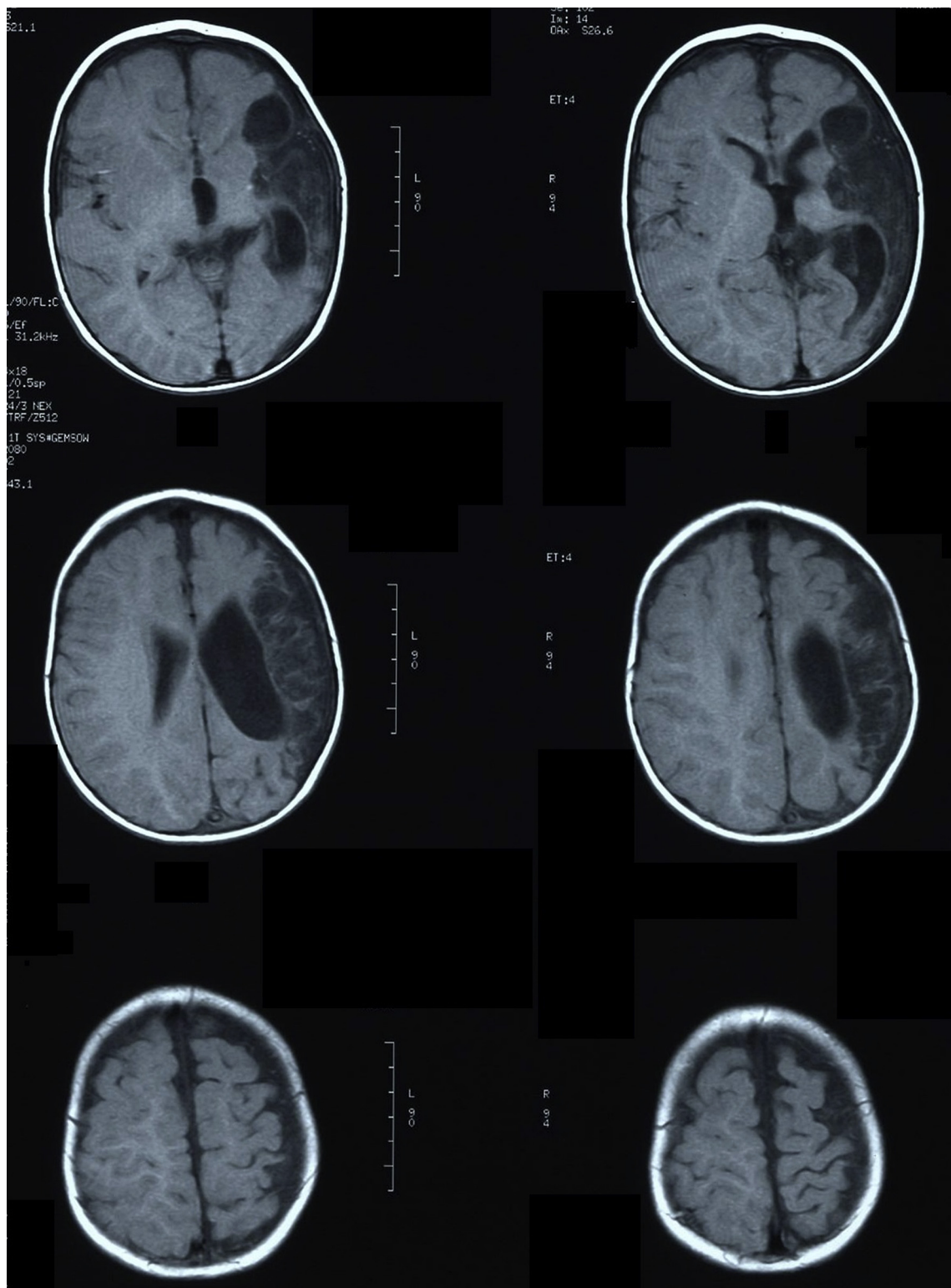


Fig. 1 – Imaging and EEG data in patient 2. **A:** preoperative MRI (axial views; T1-weighted images). **B:** cluster onset (longitudinal montage); ↑: bursts of fast activity on the left hemisphere maximal on the posterior region without any clinical feature. **C:** cluster of IS; ↑: IS with polyphasic potential preceded by a burst of fast activity on the left hemisphere; on the myogram, exclusive contraction of the right deltoid (EMD: right deltoid; EMG; left deltoid).

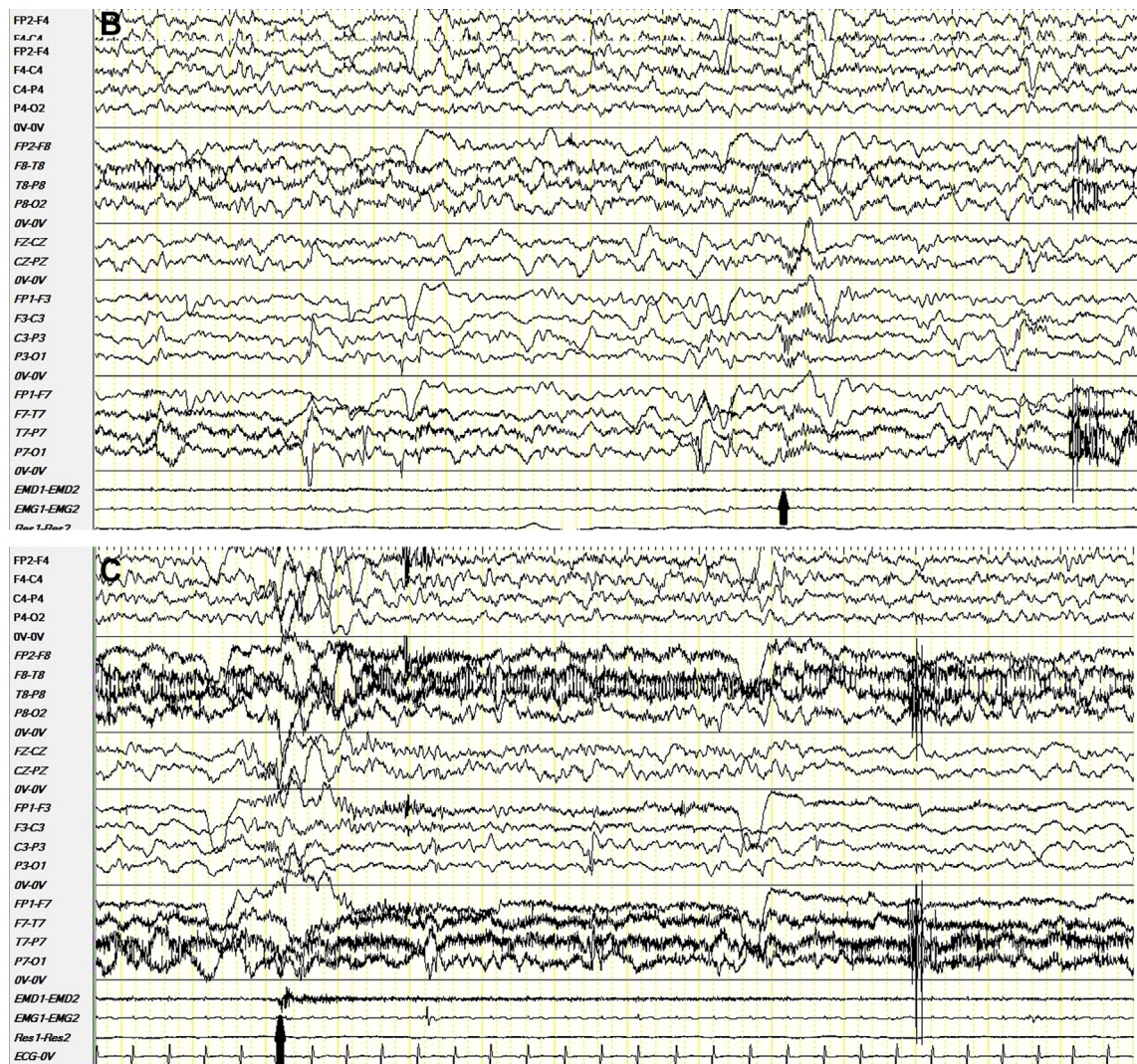


Fig. 1 – (continued).

Our criteria for hemispherotomy were similar to those for patients having focal seizures.³ Preoperatively, neurological examination of all patients revealed hemiparesis and probable lateral homonymous hemianopsia. They experienced cognitive regression throughout the duration of IS. Interictal EEG of the pathological and healthy hemispheres differed. Physiological EEG activity was absent over the pathological hemisphere with multifocal spikes. On the healthy hemisphere, physiological sleep rhythm was normal and no independent spike was recorded with the exception of the third patient (exceptional independent spikes) who was the oldest and had the longest duration of epilepsy. Bilateral synchronous EEG findings were not a contraindication for epilepsy surgery. No contralateral lesion was observed on MRI.

Epilepsy surgery was successful in terms of seizures in our three patients; in encephalomalacia in general around 70% of patients are seizure free.³

The impact of intractable epilepsy extends far beyond the seizures to result in intellectual disability and psychiatric comorbidity. Two of the children improved dramatically after

hemispherotomy while the oldest patient at time of surgery had the poorest neuropsychological outcome, particularly for language, which cannot be accounted for by the side of the stroke since it affected the right hemisphere. Neuropsychological improvement after various epilepsy surgeries has been correlated in some series with the precocity of intervention.^{5,8} Our team obtained the same results in a series of hemispherotomies.³ Comparing children with and without IS, Jonas et al.⁵ concluded that both of them improved equally postoperatively.

In our patients, age at surgery is clearly not the only predictive factor for the neuropsychological outcome. Contralateral MRI abnormalities affect seizure as well as cognitive outcome.¹ Although the MRIs showed a similar MCA stroke in all patients without any other visible lesion, one cannot exclude the coexistence of small diffuse anoxic lesions, in particular in patient # 3. However, it is unclear whether mild abnormalities have the same pejorative prognosis as obvious ones.¹ Secondly, the etiology and time of occurrence of the stroke is unknown. Ultimately the neonatal

Table 1 – Neurophysiological and neuropsychological data.

Patient	#1	#2	#3
Age at EEG-video (months)	11	21	34
Length of video-EEG recording (days)	3	4	3
Background rhythm			
Pathological H	None	Present, slow	Present, slow
Normal H	Present	Present	Present
Physiological Sleep rhythm			
Pathological H	None	None	None
Normal H	Present	Present	Present
Spikes on the pathological H	Continuous, multifocal	Continuous, multifocal	Continuous, multifocal
Bilateral synchronous spikes	No	Yes	Yes
Independent spikes on the normal H	No	No	Exceptional
Clinical Seizures	Symmetric spasms	Asymmetric spasms	Asymmetric spasms
Ictal EEG	Polyphasic potential maximal on the <u>pathological</u> H	Repetitive bursts of fast activity occurring several minutes before clinical onset marked by polyphasic potential of spasm (see Fig. 1B and C)	Polyphasic complex <u>on the pathological hemisphere</u> or bilateral
Preoperative Neuropsychology ^a	GDQ 51	GDQ 41	GDQ 54
Age at surgery (months)	14	29	38
Post-operative follow up (months)	144	49	49
Postoperative neuropsychology ^b	VIQ 72, PIQ 62	VIQ 102, PIQ 73	VIQ 50, PIQ 47

IS: Infantile Spasm H: Hemisphere.

^a Brunet–Lezine test; GDQ: global developmental quotient.

^b Wechsler scale; VIQ: verbal intellectual quotient; PIQ: performance intellectual quotient.

complications could have played a supplementary negative role.

IS occur infrequently in patients with perinatal stroke. In a cohort of perinatal strokes, 5 patients (8%) had IS with onset at a median age of seven months; three of the five patients later developed severe seizures.⁴ Keeping in mind the selection bias of patients addressed to our surgical department, in the 46 patients with ischemic sequels who underwent a hemispherotomy between 1990 and 2009, 12 (26%) had IS in the history and only the three patients reported here had isolated IS.

Our study demonstrates that hemispherotomy is efficient to cure isolated IS related to a post-ischemic lesion and could prevent mental retardation, just as in patients with similar etiology experiencing focal seizures. Further prospective studies are needed to improve predictive factors for a favorable post-operative development.

Conflict of interest

None of the authors has any conflicts of interest to disclose.

Acknowledgements

We are indebted to the EEG technologists Mrs M. Benghezal and Mrs I. Cheramy. We thank Dr Ville (CHU Lyon), Dr Napuri (CHU Rennes) and Dr Millet (CH Lannion) for having referred these children to our institution. We thank Pr Dulac for reviewing the manuscript. We thank Mrs Elizabeth Rowley-

Jolivet who is a native English speaker for language revision of the manuscript.

REFERENCES

1. Boshuizen K, van Schooneveld M, et al. Contralateral MRI abnormalities affect spasms: excellent long-term outcomes. *Clin Neurol Neurosurg* 2010;113:213–7.
2. Chugani H, Schewnon A, et al. Surgery for intractable infantile spasms: neuroimaging perspectives. *Epilepsia* 1993;34:764–71.
3. Delalande O, Bulteau C, et al. Vertical parasagittal hemispherotomy: surgical procedures and clinical long-term outcomes in a population of 83 children. *Neurosurgery* 2007;60(Suppl 1):ONS19–32.
4. Golomb M, Garg B, et al. Perinatal stroke and the risk of developing childhood epilepsy. *J Pediatr* 2007;151:409–13.
5. Jonas R, Asarnow R, et al. Surgery for symptomatic infant-onset epileptic encephalopathy with and without infantile spasms. *Neurology* 2005;64:746–50.
6. Krynauw RA. Infantile hemiplegia treated by removing one cerebral hemisphere. *J Neurol Neurosurg Psychiatry* 1950;13:243–67.
7. Lega B, Mullin J, Wyllie E, Bingaman W. Hemispheric malformations of cortical development: surgical indications and approach. *Childs Nerv Syst* 2014;30:1831–7.
8. Loddenkemper T, Holland K, et al. Developmental outcome after epilepsy surgery in infancy. *Pediatrics* 2007;119:930–5.
9. Wyllie E, Lachhwani DK, et al. Successful surgery for epilepsy due to early brain lesions despite generalized EEG findings. *Neurology* 2007;24:389–97.