

## CASE REPORT

## Successful treatment of a giant pediatric fusiform basilar trunk aneurysm with surpass flow diverter

Peter Kan,<sup>1</sup> Maxim Mokin,<sup>2</sup> Ajit S Puri,<sup>3</sup> Ajay K Wakhloo<sup>4,5</sup><sup>1</sup>Department of Neurosurgery, Baylor College of Medicine, Houston, Texas, USA<sup>2</sup>Department of Neurosurgery and Brain Repair, USF, Tampa, Florida, USA<sup>3</sup>Department of Radiology, University of Massachusetts, Worcester, Massachusetts, USA<sup>4</sup>Department of Radiology, New England Center for Stroke Research and Division Neuroimaging and Intervention, Worcester, Massachusetts, USA<sup>5</sup>Division of Neuroimaging and Intervention, University of Massachusetts Medical School, Worcester, Massachusetts, USA**Correspondence to**

Dr P Kan, Department of Neurosurgery, Baylor College of Medicine, 7200 Cambridge St, Suite 9B, Houston, TX 77030, USA; peter.kan@bcm.edu

Accepted 23 April 2015

**SUMMARY**

Fusiform aneurysms present a unique challenge to traditional microsurgical and endovascular treatment because of the lack of a discernible neck and the involvement of parent vessel. Flow diversion has increasingly become the treatment of choice for fusiform aneurysms in the anterior circulation, but its results in the posterior circulation are variable. We report successful treatment of a giant fusiform upper basilar trunk aneurysm with the Surpass flow diverter in an adolescent, and discuss the potential advantages of this emerging technology in the treatment of fusiform posterior circulation aneurysms.

**BACKGROUND**

Pediatric intracranial aneurysms often have different morphologies and etiologies compared with their adult counterparts.<sup>1–3</sup> Previous reports suggest that fusiform aneurysms originating from dissection are more common in the pediatric population.<sup>1–3</sup> Fusiform aneurysms present a unique challenge to traditional microsurgical and endovascular treatment because of their morphology and the involvement of the parent vessel. Recently, flow diversion has been advocated as the treatment of choice for fusiform aneurysms in the anterior circulation, but its results in the posterior circulation are variable.<sup>4–5</sup>

In this report, we describe successful treatment of a giant fusiform upper basilar trunk aneurysm with the Surpass flow diverter (FD) in an adolescent, and discuss the potential advantages of this emerging technology in the treatment of posterior circulation aneurysms.

**CASE PRESENTATION**

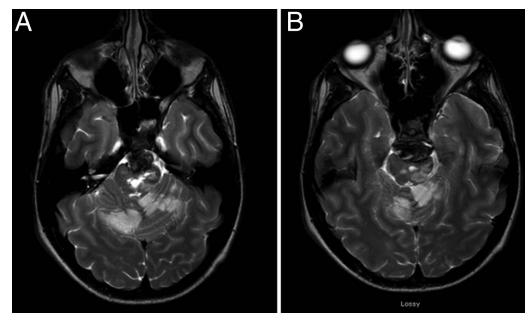
The patient is a 16-year-old boy, previously healthy, who presented with diplopia, ataxia, dysarthria, dysphagia, and right hemiparesis. CT imaging of the brain did not detect any subarachnoid hemorrhage, but MRI demonstrated multiple brainstem and cerebellar infarcts and a partially thrombosed upper basilar trunk aneurysm with mass effect (figure 1). Digital subtraction angiography (DSA) revealed a giant fusiform upper basilar trunk aneurysm with mild proximal stenosis (figure 2). The patient underwent a complete rheumatology workup for connective tissue disorder, including serum markers and a lumbar puncture, that were negative. The patient did not have a history of significant trauma. The aneurysm was considered not amenable to conventional microsurgical and endovascular treatment, and flow diversion was offered

as an alternative. The variability of its efficacy in posterior circulation aneurysms was fully discussed with the patient and his parents.

**TREATMENT**

The patient was pretreated with dual antiplatelet therapy, consisting of 325 mg of aspirin daily and 75 mg of clopidogrel daily for 5 days prior to the procedure. The degree of P2Y12 inhibition and aspirin response were tested with VerifyNow (Accumetrics, San Diego, California, USA) on the day of treatment. His aspirin response unit and P2Y12 reaction units were 384 and 100, respectively, suggestive of an appropriate level of platelet inhibition for treatment. The repeated test at 3 months showed continued stable inhibition. Systemic heparin was administered to achieve an activated clotting time of >250 s during the procedure.

Under general anesthesia, bilateral femoral access was obtained. To ensure robust proximal support for FD deployment, a triaxial system consisting of a Neuron MAX 088 guide catheter (Penumbra Inc, Alameda, California, USA) in the right V2 segment and a 5 F distal delivery catheter in the right V4 segment, was used. A 5 F diagnostic catheter was placed in the left vertebral artery so that adequate angiographic runs could be performed during FD deployment. We navigated past the aneurysm with an SL10 microcatheter (Stryker, Kalamazoo, Michigan, USA) and a Synchro Standard wire (Boston Scientific, Natick, Massachusetts, USA). The microcatheter was then exchanged for a 3×25 mm Surpass FD (Stryker Neurovascular, Fremont, California, USA), which was then deployed starting from the left P1 segment. The device did not fully cover the fusiform portion of the aneurysm, and thus a second 3×25 mm device

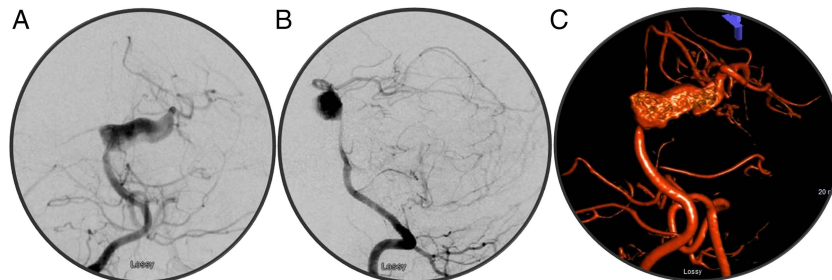


**Figure 1** MRI revealed multiple brainstem and cerebellar infarcts, and a partially thrombosed upper basilar trunk aneurysm with mass effect.

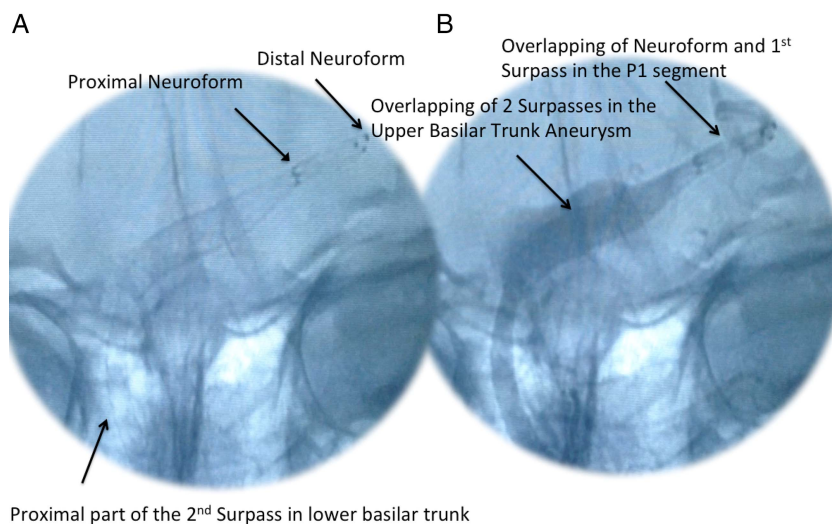


**To cite:** Kan P, Mokin M, Puri AS, et al. *BMJ Case Rep* Published online: [please include Day Month Year] doi:10.1136/bcr-2015-011718

**Figure 2** Digital subtraction angiography (A, B) with three-dimensional reconstruction (C) showing giant fusiform upper basilar trunk aneurysm with mild proximal stenosis.



**Figure 3** (A, B) Digital subtraction angiography showing the final construct with two 3×25 mm Surpass flow diverters.



was deployed to overlap the first device in the fusiform segment of the aneurysm. A 3.5×10 mm Neuroform stent (Stryker) was then deployed to overlap the distal portion of the first device to ensure patency of the left posterior cerebral artery (figure 3). The microwire straightened the left P1 segment thus creating an ‘infolding’ or ‘pseudo’ stenosis of the artery just distal to the Surpass device.

There was concern that when the wire was withdrawn, blood flow may be compromised at the distal transition between Surpass and the P1 segment if the vessel were to re-fold on itself just distal to the Surpass device. The Neuroform stent was deployed to allow a smooth transition between the FD and the distal artery. A Neuroform stent was chosen over a short Surpass device because of the lower cost associated with the Neuroform stent and less metal coverage of the P1 segment and its perforators compared with an additional FD.

DSA on postoperative day 1 showed no filling of the aneurysm and a patent construct. The patient remained in hospital for a total of 6 weeks, 5 of which were for acute inpatient rehabilitation. His postoperative course was uneventful and he did not suffer any additional neurologic deficits.

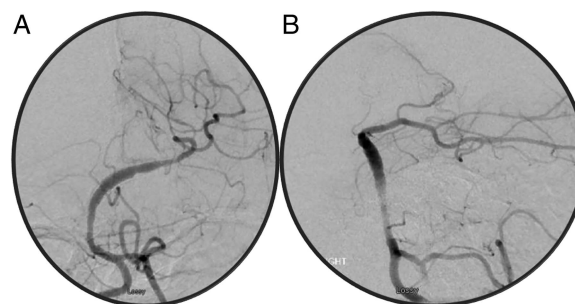
#### OUTCOME AND FOLLOW-UP

At 6 months, the patient’s diplopia and dysphagia had resolved (he never required a gastrostomy tube). He had residual dysarthria and ataxia but was ambulatory without assist. His right-sided strength was normal, with only residual spasticity at 6 months. His 6 month angiogram revealed that the aneurysm remained obliterated and the construct remained patent with no stenosis (figure 4). Follow-up CT at 4 months also showed an overall reduction in aneurysm size and mass effect (figure 5). The

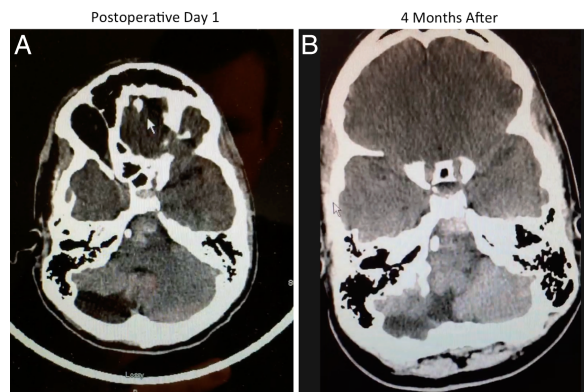
patient was treated with daily dual antiplatelet therapy consisting of aspirin (325 mg) and clopidogrel (75 mg) for 6 months after the procedure. Clopidogrel was then discontinued, and he remained on an aspirin regimen (81 mg daily), which will be continued throughout his life. After DSA at 1 year, we propose non-invasive annual imaging with MRI (short echo time (TE) with gadolinium-diethylenetriamine pentaacetic acid).

#### DISCUSSION

We have reported a case of successful treatment of a symptomatic giant fusiform basilar aneurysm with the Surpass FD in an adolescent. The literature on the use of FD in the treatment of pediatric cerebral aneurysms is sparse.<sup>6,7</sup> Although the use of the Surpass FD has been reported in the treatment of posterior circulation aneurysms,<sup>8</sup> its use has not been reported in pediatric patients in



**Figure 4** Angiogram obtained at the 6 month follow-up examination, showing complete aneurysm obliteration and patent construct with no stenosis.



**Figure 5** CT at 4 months (B) revealed overall reduction in aneurysm size and mass effect compared with the initial postoperative study (A).

this location. FDs have been advocated as the firstline treatment for fusiform aneurysms in the anterior circulation; however, the results of flow diversion in the treatment of posterior circulation aneurysms have uniformly been worse compared with anterior circulation aneurysms.<sup>4 5 9</sup> Phillips *et al*<sup>5</sup> treated 32 posterior circulation aneurysms with the pipeline embolization device (PED) and reported a permanent neurological complication rate of 9.4%, with perforator infarcts occurring in 14% of patients with basilar artery aneurysms. Similar results have been reported in the International Retrospective Study of the PED.<sup>4</sup> In 55 posterior circulation aneurysms treated with a PED, Kallmes *et al*<sup>4</sup> reported neurologic morbidity and mortality of 16.4% and an ischemic stroke rate of 7.3%. Among posterior circulation aneurysms, fusiform basilar aneurysms appear to have the highest treatment risks, likely because of extensive involvement of brainstem perforators.<sup>5 10</sup>

Surpass FD is an alternative FD that has received regulatory approval in the European Economic Area and is undergoing evaluation for approval in the USA. We believe that, compared with the PED, the Surpass FD has several potential advantages in the treatment of long fusiform basilar aneurysms, as in our case. First, the Surpass FD is available in longer lengths (up to 50 mm), thereby potentially allowing the use of a single device and minimizing the coverage of perforators. We originally planned to use a single 4 mm device to minimize perforator coverage (the longest 4 mm device is 50 mm). However, the final measurement of the vessel distal to the aneurysm was only 2.6 mm and thus we decided to use a 3 mm device instead to avoid a large mismatch. The longest 3 mm device currently is 25 mm, and to cover the aneurysm, a second device was needed. Longer 3 mm devices in the future would eliminate this problem. Second, compared with the PED, there is less device foreshortening,<sup>8</sup> especially in fusiform aneurysms where the device will expand to nominal diameters with maximal foreshortening. With less foreshortening and more predictable length of the device, it again reduces the need of telescoping multiple devices, thus enhancing the chance of perforator preservation.

Although our patient was treated successfully with an excellent clinical result, our case represents a single case experience,

and a larger patient population with longer follow-up is necessary to further assess the safety and efficacy of this emerging device in the treatment of posterior circulation aneurysms. Additional long term follow-up is also necessary to look for recurrence and document cure in our patient.

### Learning points

- ▶ Fusiform aneurysms present a challenge to traditional surgical clipping or conventional endovascular coil embolization because they lack a discernible neck and there is circumferential involvement of the parent vessel.
- ▶ In the treatment of fusiform aneurysms, flow diversion offers the advantage of endoluminal vessel reconstruction, leading to aneurysm obliteration and healing of the parent vessel.
- ▶ The results of flow diversion in the treatment of posterior circulation aneurysms have uniformly been worse compared with anterior circulation aneurysms, likely due to perforator rich zones.
- ▶ Nevertheless, in select cases, flow diversion can offer successful treatment of fusiform aneurysms in the posterior circulation.

**Contributors** Each of the authors contributed significantly to the preparation of this case report.

**Competing interests** PK: consultant for Stryker Neurovascular, Covidien, and Microvention. MM: education grant from Toshiba. ASP: consultant for Codman and Covidien. AKW: consultant for Stryker Neurovascular; research grant from Phillips Healthcare and Wyss Institute; and speaker for Harvard Postgraduate Course and Miami Cardiovascular Institute.

**Patient consent** Obtained.

**Provenance and peer review** Not commissioned; externally peer reviewed.

### REFERENCES

- 1 Meyer FB, Sundt TM Jr, Fode NC, *et al*. Cerebral aneurysms in childhood and adolescence. *J Neurosurg* 1989;70:420–5.
- 2 Ostergaard JR. Aetiology of intracranial saccular aneurysms in childhood. *Br J Neurosurg* 1991;5:575–80.
- 3 Proust F, Toussaint P, Garnier J, *et al*. Pediatric cerebral aneurysms. *J Neurosurg* 2001;94:733–9.
- 4 Kallmes DF, Hanel R, Lopes D, *et al*. International retrospective study of the pipeline embolization device: a multicenter aneurysm treatment study. *AJNR Am J Neuroradiol* 2015;36:108–15.
- 5 Phillips TJ, Wenderoth JD, Phatouros CC, *et al*. Safety of the pipeline embolization device in treatment of posterior circulation aneurysms. *AJNR Am J Neuroradiol* 2012;33:1225–31.
- 6 Navarro R, Brown BL, Beier A, *et al*. Flow diversion for complex intracranial aneurysms in young children. *J Neurosurg Pediatr* 2015;15:276–81.
- 7 Burrows AM, Zipfel G, Lanzino G. Treatment of a pediatric recurrent fusiform middle cerebral artery (MCA) aneurysm with a flow diverter. *J Neurointerv Surg* 2013;5:e47.
- 8 Wakhloo AK, Lylyk P, de Vries J, *et al*. Surpass flow diverter in the treatment of intracranial aneurysms: a prospective multicenter study. *AJNR Am J Neuroradiol* 2015;36:98–107.
- 9 D'Urso PI, Lanzino G, Cloft HJ, *et al*. Flow diversion for intracranial aneurysms: a review. *Stroke* 2011;42:2363–8.
- 10 Siddiqui AH, Abila AA, Kan P, *et al*. Panacea or problem: flow diverters in the treatment of symptomatic large or giant fusiform vertebrobasilar aneurysms. *J Neurosurg* 2012;116:1258–66.

Copyright 2015 BMJ Publishing Group. All rights reserved. For permission to reuse any of this content visit <http://group.bmj.com/group/rights-licensing/permissions>.  
BMJ Case Report Fellows may re-use this article for personal use and teaching without any further permission.

Become a Fellow of BMJ Case Reports today and you can:

- ▶ Submit as many cases as you like
- ▶ Enjoy fast sympathetic peer review and rapid publication of accepted articles
- ▶ Access all the published articles
- ▶ Re-use any of the published material for personal use and teaching without further permission

For information on Institutional Fellowships contact [consortiasales@bmjgroup.com](mailto:consortiasales@bmjgroup.com)

Visit [casereports.bmj.com](http://casereports.bmj.com) for more articles like this and to become a Fellow