



## An unusual complication of atrial fibrillation ablation: case report

Mentor Petrela, MD,<sup>1</sup> Arben Rroji, MD,<sup>2</sup> Eugen Enesi, MD,<sup>2</sup> Artur Xhumari, MD,<sup>1</sup> and Artid Lame, MD<sup>1</sup>

Departments of <sup>1</sup>Neurosurgery and <sup>2</sup>Radiology, University Hospital Centre "Mother Teresa," Tirana, Albania

The authors report a complication of catheter ablation that, to their knowledge, has never been previously reported. A 63-year-old man had undergone successful transvenous catheter thermoablation for atrial fibrillation. The patient remained well until 3 days prior to further admission when he noticed itching in the right frontal area of his scalp. On palpating his scalp, he discovered a metallic body projecting out of it and he proceeded to extract 20 cm of wire from his head. The following day a progressive left hemiplegia developed, and the patient experienced a deteriorating level of consciousness. A CT scan of the brain showed a right frontotemporal intraparenchymal hemorrhage and revealed a metallic structure in the middle of the hematoma. The hematoma was evacuated and a decompressive craniotomy was performed. The guidewire was identified, but it was only possible to extract part of it. It was covered by fibrous tissue, secondary to inflammatory reaction. To the authors' knowledge, this is the first report of guidewire-induced brain hemorrhage. The guidewire apparently had not been removed and had spontaneously migrated from the heart to the brain and beyond to the scalp where it then exited the patient's head. The patient had been well before he attempted to pull out the wire. Earlier identification of the iatrogenic complication of a retained guidewire might have prevented the fatal outcome in this case.

<http://thejns.org/doi/abs/10.3171/2014.12.JNS141932>

**KEY WORDS** guidewire; atrial fibrillation; intracerebral hemorrhage; interventional neurosurgery

**A**TRIAL fibrillation is the most common disturbance of cardiac rhythm encountered in clinical practice.<sup>6</sup> It has been estimated that 2.2 million people in United States and 4.5 million people in the European Union have paroxysmal or persistent atrial fibrillation.<sup>4</sup> During the past 20 years, there has been a 66% increase in hospital admissions for atrial fibrillation<sup>5,9</sup> due to a combination of factors.

Even though catheter ablation is a relatively safe treatment, complications, such as iatrogenic cardiac and pericardial complications; acute myocardial infarction; and vascular, respiratory, and neurological complications, can still occur.<sup>1</sup> Here, we report here a complication of catheter ablation that, to our knowledge, has not been previously reported.

### Case Report

#### History and Presentation

A 63-year-old Caucasian man who was obese and hypertensive, with high alcohol and smoking consumption, and with known rheumatic aortic and mitral valve disease underwent transvenous catheter thermoablation for atrial

fibrillation in 2011 at a different, foreign institution. The technical information about this procedure is complete as a file but it was not detailed. Despite our request, the institution where the procedure was performed declined to provide us with further details. One year later, the patient was admitted to the same institution with severe dyspnea and tachycardia. Findings from complete cardiological workup, including blood analysis and transesophageal and transthoracic echocardiography, were unremarkable. However, a chest radiograph revealed a right parasternal linear structure that was interpreted as a ventriculoperitoneal shunt by the reporting radiologist, who was unaware of the patient's medical history (Fig. 1). Since the patient was not compliant with anticoagulant treatment, his Coumadin therapy was replaced with aspirin therapy.

The patient remained well until 3 days prior to further admission when he noticed itching in the right frontal area of his scalp. On palpating his scalp, he discovered a metallic body projecting out of it and he proceeded to extract 20 cm of wire from his head (Fig. 2A and B). The following day, the patient presented to our emergency department with a progressive left hemiplegia and a deteriorating level of consciousness.

**ABBREVIATION** DS = digital subtraction.

**SUBMITTED** August 20, 2014. **ACCEPTED** December 9, 2014.

**INCLUDE WHEN CITING** Published online June 5, 2015; DOI: 10.3171/2014.12.JNS141932.

**DISCLOSURE** The authors report no conflict of interest concerning the materials or methods used in this study or the findings specified in this paper.

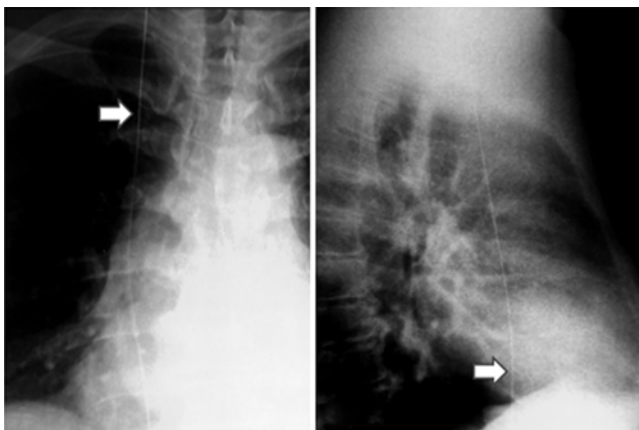
### Imaging Findings

CT scanning of the brain showed a right frontotemporal intraparenchymal hemorrhage (Fig. 2C and D), and the patient was referred to our department for neurosurgical evaluation. Further examination of the CT scan revealed a metallic structure that did not look like a ventricular catheter in the middle of the intraparenchymal right frontotemporal hematoma. A CT angiogram of the chest was then obtained (Fig. 3A) and showed a metallic wire in the superior and inferior venae cavae. The scout CT scan of the head (Fig. 3B) showed that the wire ran from the scalp and calvaria through the hematoma, down to the internal jugular vein, superior vena cava, and right atrium, and ending in the inferior vena cava. At the level of the jugular bulb (Fig. 3F), the metallic structure went through the foramen lacerum of the carotid canal without any evidence of dehiscence on CT scanning (Fig. 3C) or arterial injury confirmed on digital subtraction (DS) angiography (Fig. 3E). We speculated that the guidewire had worked itself into the brain parenchyma because of the increase in intraabdominal pressure rather than venous flux or carotid pulse, had perforated both the basal dura mater and the venous wall, and ultimately penetrated the skull and scalp (Fig. 3D). Presumably, the guidewire had been used during the prior transvenous thermoablation procedure and had not been withdrawn and ultimately led to intracranial migration and spontaneous exteriorization. The patient did not provide detail to suggest the opposite course of the wire from the head.

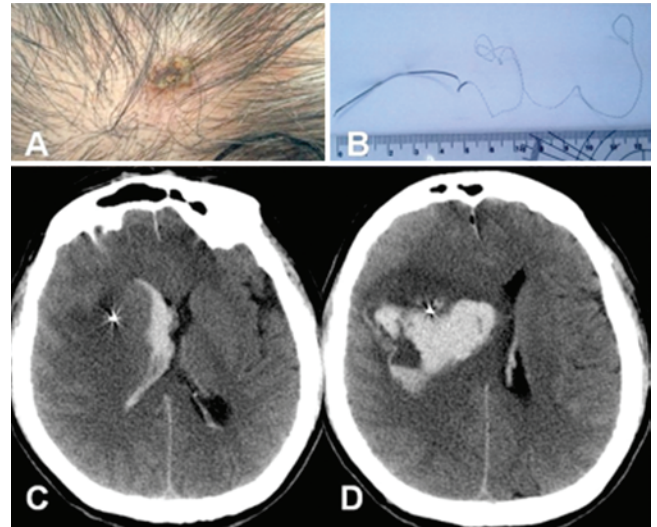
### Operation

As the patient's clinical and neurological status deteriorated, the hematoma was evacuated and a decompressive craniotomy was performed. The guidewire was identified, but it was only possible to extract part of it. It was stiff and covered by fibrous tissue, secondary to inflammatory reaction. The wire was cut and the end was wrapped with hemostatic gauze (Video 1).

**VIDEO 1.** Intraoperative video. Evacuation of hematoma and cutting of the metallic guidewire. Copyright Mentor Petrela. Published with permission. [Click here to view with Media Player.](#) [Click here to view with Quicktime.](#)



**FIG. 1.** Chest radiographs in posteroanterior (left) and laterolateral (right) projections showing the metallic wire (arrows) in the trajectory of the superior and inferior venae cavae (previously interpreted as a ventriculoperitoneal shunt).



**FIG. 2.** Photographs of the frontal point of exteriorization (A) and metallic wire (B) extracted by the patient himself. Plain CT scans showing intraparenchymal metallic wire surrounded by hemorrhage with intraventricular inundation (C and D).

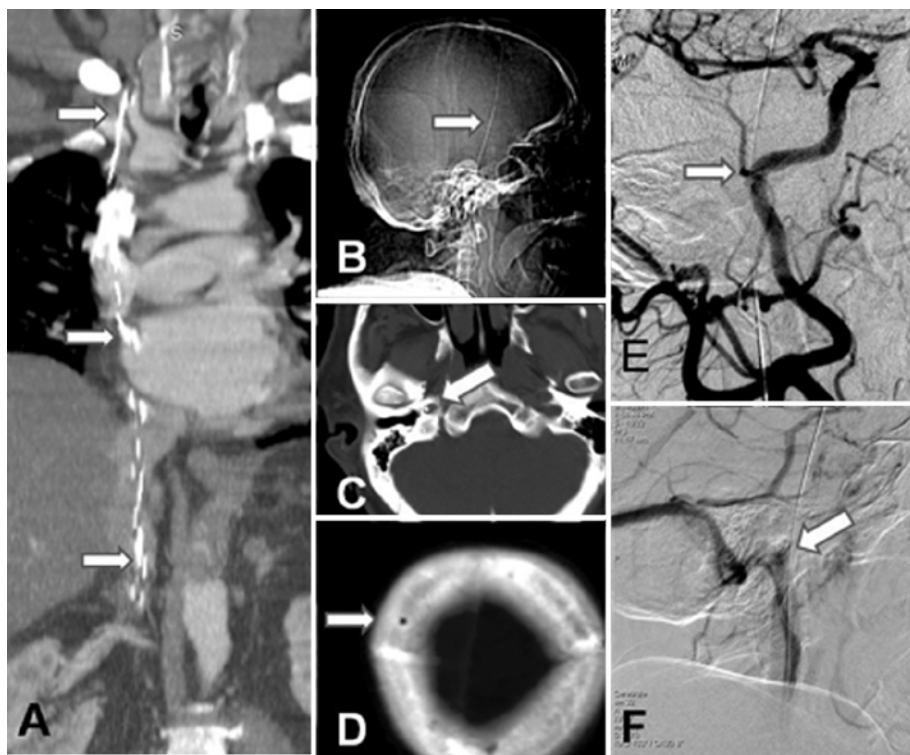After surgery, the patient's neurological condition improved, but he died on the 6th postoperative day of respiratory failure due to pneumonia. A thorough review of the medical literature failed to reveal any similar case report.

### Discussion

We describe a patient who underwent endovascular atrial catheter ablation for refractory atrial fibrillation. Two years after the procedure, he experienced continuous itching in the right frontal scalp and he extracted 20 cm of wire from his head. He subsequently developed a progressive left hemiparesis as a result of an intraparenchymal cerebral hemorrhage. A metallic wire running from the inferior vena cava to the right frontal bone was found. Although the majority of heart-brain connections are already well described,<sup>7</sup> this case demonstrates a new connection that might be described as “wired-connected.”

Our case needs to be seen within the larger context of the complications of endovascular procedures. There is considerable variability in the reported incidence of complications with guidewire-assisted procedures.<sup>3</sup> Retention of guidewires represent approximately 10% of retained foreign bodies in endovascular procedures and are probably underreported or at least not immediately recognized.<sup>8</sup> They are most often incidentally discovered but may occasionally cause pulmonary emboli, endocarditis, dysrhythmias, cardiac tamponade,<sup>2</sup> or even a brain hemorrhage, as in the present case.

To our knowledge, this is the first report of guidewire-induced brain hemorrhage. The guidewire spontaneously found the route from the heart to the brain and beyond to the scalp where it then exited the patient's head. Given that the patient had been well before he attempted to pull out the wire, it would appear that until then the spontaneous and original route of the guidewire had not caused the patient any harm. The patient's attempt to pull the wire out of his head caused arterial trauma and the subsequent



**FIG. 3.** **A:** CT angiogram showing the intracaval trajectory of the guidewire. **B:** Scout CT scan showing the intracranial trajectory of the metallic wire. **C and D:** CT scans showing passage at right foramen lacerum (C) and frontal point of exteriorization (D). **E:** DS angiogram in the arterial phase confirming the normal lumen of the lacerum segment of right internal carotid artery in close contact with the guidewire. **F:** DS angiogram in the venous phase showing the course of the guidewire passing through the jugular vein. Arrows show the trajectory of the guidewire.

brain hemorrhage. Earlier identification of the retained guidewire might have prevented the fatal outcome.

## Acknowledgments

We thank Drs. Henry Marsh and Emmanuel Houdart for assistance with preparing the manuscript.

## References

1. Cappato R, Calkins H, Chen SA, Davies W, Iesaka Y, Kalman J, et al: Updated worldwide survey on the methods, efficacy, and safety of catheter ablation for human atrial fibrillation. *Circ Arrhythm Electrophysiol* **3**:32–38, 2010
2. Chabanier A, Dany F, Brutus P, Vergnoux H: Iatrogenic cardiac tamponade after central venous catheter. *Clin Cardiol* **11**:91–99, 1988
3. Deshmukh A, Patel NJ, Pant S, Shah N, Chothani A, Mehta K, et al: In-hospital complications associated with catheter ablation of atrial fibrillation in the United States between 2000 and 2010: analysis of 93 801 procedures. *Circulation* **128**:2104–2112, 2013
4. Feinberg WM, Cornell ES, Nightingale SD, Pearce LA, Tracy RP, Hart RG, et al: Relationship between prothrombin activation fragment F1.2 and international normalized ratio in patients with atrial fibrillation. *Stroke* **28**:1101–1106, 1997
5. Friberg J, Buch P, Scharling H, Gadsbøll N, Jensen GB: Rising rates of hospital admissions for atrial fibrillation. *Epidemiology* **14**:666–672, 2003
6. Kannel WB, Abbott RD, Savage DD, McNamara PM: Epidemiologic features of chronic atrial fibrillation: the Framingham study. *N Engl J Med* **306**:1018–1022, 1982
7. Samuels MA: The brain-heart connection. *Circulation* **116**:77–84, 2007
8. Song Y, Messerlian AK, Matevosian R: A potentially hazardous complication during central venous catheterization: lost guidewire retained in the patient. *J Clin Anesth* **24**:221–226, 2012
9. Wattigney WA, Mensah GA, Croft JB: Increasing trends in hospitalization for atrial fibrillation in the United States, 1985 through 1999: implications for primary prevention. *Circulation* **108**:711–716, 2003

## Author Contributions

Conception and design: Petrela. Acquisition of data: Rroji, Enesi. Analysis and interpretation of data: Rroji, Enesi. Drafting the article: Xhumari, Lame. Critically revising the article: Petrela. Reviewed submitted version of manuscript: Petrela. Approved the final version of the manuscript on behalf of all authors: Petrela.

## Supplemental Information

### Videos

*Video 1, Media Player.* [http://mfile.akamai.com/21490/wmv/digitalwbc.download.akamai.com/21492/wm.digitalsource-na-regional/jns14-1932\\_video\\_1.asx](http://mfile.akamai.com/21490/wmv/digitalwbc.download.akamai.com/21492/wm.digitalsource-na-regional/jns14-1932_video_1.asx).

*Video 1, Quicktime.* [http://mfile.akamai.com/21488/mov/digitalwbc.download.akamai.com/21492/qt.digitalsource-global/jns14-1932\\_video\\_1.mov](http://mfile.akamai.com/21488/mov/digitalwbc.download.akamai.com/21492/qt.digitalsource-global/jns14-1932_video_1.mov).

## Correspondence

Mentor Petrela, Service of Neurosurgery, University Hospital Centre “Mother Teresa,” Kongresi i Manastirit, Nr. 210, Tirana, Albania. email: mentor.petrela@gmail.com.