

CASE REPORT

Dissecting the unspeakable: a fatal case of aortic dissection

Parinita A Dherange,¹ Sarah Patel,¹ Nirmal Singh,² Prakash Suryanarayana²

¹Department of Internal Medicine, Banner University Medical Center South, Tucson, Arizona, USA
²University of Arizona Health Network, Tucson, Arizona, USA

Correspondence to
 Parinita A Dherange, parinita.dherange@bannerhealth.com

Accepted 26 May 2015

SUMMARY

A 47-year-old man with diabetes and hypertension presented with sudden onset of chest pain and subsequently developed expressive aphasia. Brain imaging revealed multiple areas of ischaemic infarcts. Transoesophageal echocardiogram revealed aortic dissection with a free-floating thrombus on the dissection flap, which was the source of emboli. Given the poor prognosis, surgical intervention was not pursued and artificial support was withdrawn. Aortic dissection is a highly fatal condition with varied presentation including heart failure, myocardial infarction, neurological deficits, abdominal pain or acute renal failure. Aortic dissection is a relatively uncommon but catastrophic condition. A high degree of clinical suspicion is required for early and accurate diagnosis since mortality is high and increases by the hour. The mechanism for stroke in our case was due to an artery-to-artery embolism from a thrombus, which developed on the intimal surface of the dissected artery. This is an infrequent complication with a very unique mechanism.

BACKGROUND

Aortic dissection is a fatal condition in which there is a tear in the wall of the major artery that carries blood out of the heart, ultimately leading to ischaemia of vital organs. Neurological syndromes are commonly seen in patients with Stanford type A dissection but rarely seen in type B dissections.¹ Progression of the false lumen with subsequent thrombosis or intimal detachment are the usual mechanisms of stroke in these patients.² However, we report a rare mechanism of stroke in aortic dissection.

CASE PRESENTATION

A 47-year-old man with diabetes and hypertension presented with sudden onset of chest pain. His medical history was significant for diabetes and hypertension. His initial blood pressure was 226/134 mm Hg with heart rate of 92 bpm and respiratory rate of 26 breaths per min. There were no discrepancies in bilateral pulses. His systemic examination was unremarkable. Although he presented with normal mental status, he soon developed expressive aphasia. His mental status subsequently declined necessitating endotracheal intubation and mechanical ventilation.

INVESTIGATIONS

ECG showed sinus rhythm with no significant ST-T wave changes.

Troponin I, haemoglobin, renal and liver function tests were within normal limits.

CT scan of the head showed no intracranial haemorrhage. MRI/angiography revealed multiple areas of ischaemic infarcts, suspicious for cardioembolism (figure 1).

Transoesophageal echocardiogram, which was performed to assess for thrombus or vegetation, showed dissection of aorta involving transverse portion of the arch and extending into the descending aorta. The free-floating thrombus on the flap was thought to be the source of embolism to the brain (figure 2).

CT scan of the aorta was later performed to delineate the true extent of dissection. It showed Stanford type B aortic dissection with the entry point distal to the origin of left subclavian artery (figure 3).

MRI of the brain on day 2 showed haemorrhagic conversion of previously demonstrated infarcts and new lesions of restricted diffusion.

DIFFERENTIAL DIAGNOSIS

In view of multiple emboli, cardiac sources such as apical or left atrial appendage clot, vegetation, patent foramen ovale and large arterial causes such as athero-embolism were considered.

OUTCOME AND FOLLOW-UP

Owing to prohibitively high risk for full heparinisation, endovascular or surgical intervention was not pursued. Conservative therapy with intravenous esmolol and nicardipine was started. Owing to poor prognosis, and wishes of family, artificial support was withdrawn.

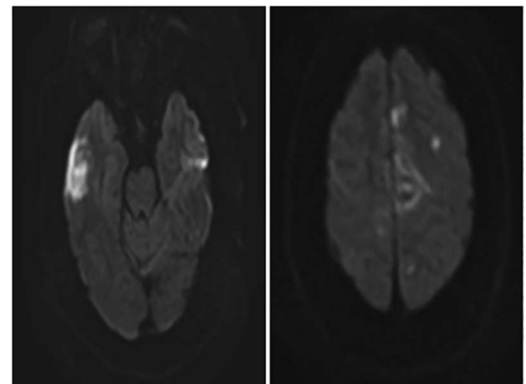
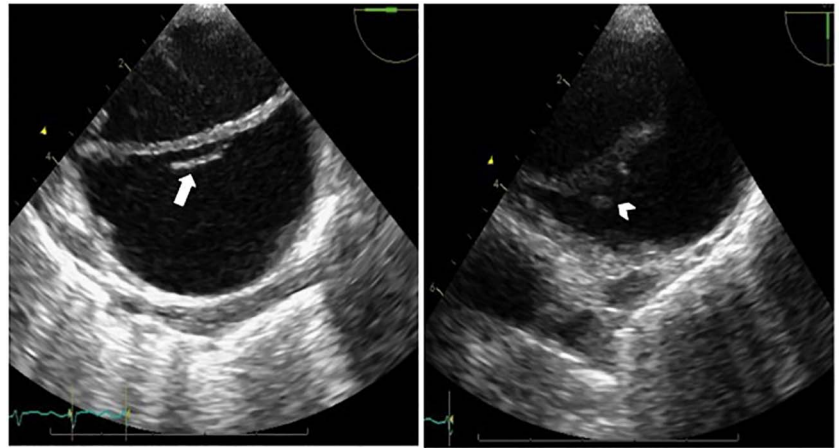


Figure 1 MRI showing acute infarcts.



To cite: Dherange PA, Patel S, Singh N, et al. *BMJ Case Rep* Published online: [please include Day Month Year] doi:10.1136/bcr-2015-210469

Figure 2 Transoesophageal echocardiogram showing dissection of the aorta with a flap (arrow) involving the transverse portion of aorta and a free floating thrombus (arrowhead) on the dissecting flap.



DISCUSSION

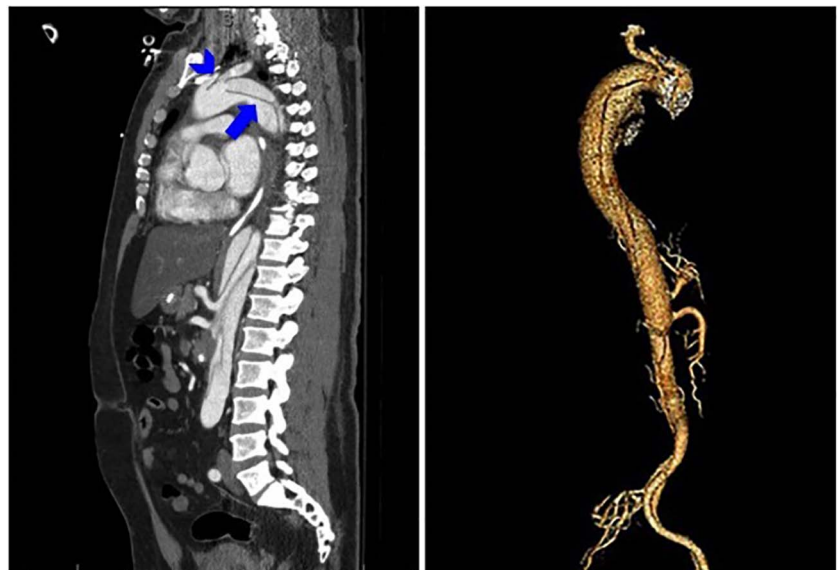
Aortic dissection is a rare and potentially fatal disease, with an estimated incidence of 5–30 cases per million per year.¹ Chronic systemic hypertension is the most common risk factor followed by connective tissue diseases such as Marfan syndrome and Ehlers-Danlos syndrome.³ Classically, aortic dissection presents with sudden and severe tearing or ripping pain in the chest, back, or abdomen, radiating to the interscapular region. Atypical features and absence of pain may be seen rarely. The Stanford classification of aortic dissection distinguishes between type A and type B. In type A, the dissection involves the ascending aorta.⁴ In type B, only the descending aorta is involved. DeBakey classification subdivides the dissection into three types; type I dissection involving the ascending and descending aorta, type II dissection involving only the ascending aorta, and type III dissection sparing the ascending aorta and arch.⁵

Acute ascending aortic dissection (Stanford type A) is a surgical emergency due to high risk for early life-threatening complications such as acute aortic regurgitation, cardiac tamponade and myocardial infarction.⁶ Type A aortic dissections have a

mortality of 1–2% per hour after symptom onset. Without surgery, mortality exceeds 50% at 1 month.⁷ Patients who are haemodynamically stable with uncomplicated aortic dissections confined to the descending thoracic aorta (Stanford type B) are best treated with medical therapy, but intervention may be needed for patients who have a complicated course.⁸ Type B aortic dissections have a 30-day mortality of 10% and with intervention, have shown a higher mortality ranging between 35% and 75%.⁷

Cerebral ischaemic complications occur in 18–30% of aortic dissections and are due to direct extension of the dissection into the carotid arteries or diminished carotid blood flow.^{2–7} However, in our case, we suspect that the mechanism for stroke was artery-to-artery embolism from a thrombus, which developed on the intimal surface of the dissected artery.³ Our case also had a type B dissection involving the descending aorta that was complicated with extension into the aortic arch causing proximal dissection as well, which is very rarely seen. Complicated type B aortic dissection is an indication for surgical treatment; however, it was deferred due to risk of cerebral bleeding in the setting of acute embolic stroke.

Figure 3 CT of the aorta showing Stanford type B dissection (blue arrow) and evidence for back dissection with an intimal flap (blue arrowhead) located between the orifice of the left common and left subclavian arteries.



This case illustrates an infrequent complication of a rare disease by an unusual mechanism.

Learning points

- ▶ Aortic dissection is a relatively uncommon but catastrophic condition.
- ▶ It can manifest in a number of different ways including heart failure, myocardial infarction, focal pulse and neurological deficits, abdominal pain or acute renal failure.
- ▶ Diagnosis is difficult and mortality is high, and increases by the hour.
- ▶ Early intervention and control of hypertension dramatically improve the prognosis.

Contributors PAD was involved in the conception and design, acquisition of data, analysis and interpretation of data, drafting the article, final approval of the version to be published. SP was involved in the conception and design, acquisition of data, analysis and interpretation of data, critical revision of the article, final approval of the version to be published. NS was involved in the acquisition of data, analysis and interpretation of data, drafting the article, final approval of the version to be published.

published. PS was involved in the acquisition of data, analysis and interpretation of data, drafting the article, final approval of the version to be published.

Competing interests None declared.

Patient consent Obtained.

Provenance and peer review Not commissioned; externally peer reviewed.

REFERENCES

- 1 Hagan PG, Nienaber CA, Isselbacher EM, *et al.* The International Registry of Acute Aortic Dissection (IRAD): new insights into an old disease. *JAMA* 2000;283:897–903.
- 2 Jambeih R, Brumfield E, Shaheen W, *et al.* Spontaneously Sealed Aortic Dissection Presenting with Multiple Ischemic Strokes. 2011.
- 3 Fernandez E, Nadig R, Mathew T, *et al.* Aortic dissection causing embolic stroke. *Neurol India* 2009;57:689.
- 4 Kasher JA, El-Bialy A, Balingit P. Aortic dissection: a dreaded disease with many faces. *J Cardiovasc Pharmacol Ther* 2004;9:211–18.
- 5 Daily PO, Trueblood HW, Stinson EB, *et al.* Management of acute aortic dissections. *Ann Thorac Surg* 1970;10:237–47.
- 6 Nienaber CA, Eagle KA. Aortic dissection: new frontiers in diagnosis and management: part I: from etiology to diagnostic strategies. *Circulation* 2003;108:628–35.
- 7 Tsai TT, Nienaber CA, Eagle KA. Acute aortic syndromes. *Circulation* 2005;112:3802–13.
- 8 DeSanctis RW, Doroghazi RM, Austen WG, *et al.* Aortic dissection. *N Engl J Med* 1987;317:1060–7.

Copyright 2015 BMJ Publishing Group. All rights reserved. For permission to reuse any of this content visit

<http://group.bmj.com/group/rights-licensing/permissions>.

BMJ Case Report Fellows may re-use this article for personal use and teaching without any further permission.

Become a Fellow of BMJ Case Reports today and you can:

- ▶ Submit as many cases as you like
- ▶ Enjoy fast sympathetic peer review and rapid publication of accepted articles
- ▶ Access all the published articles
- ▶ Re-use any of the published material for personal use and teaching without further permission

For information on Institutional Fellowships contact consortiasales@bmjgroup.com

Visit casereports.bmj.com for more articles like this and to become a Fellow