

Distal internal carotid artery dissection due to the carotid shunt during carotid endarterectomy

Makoto Katsuno, Rokuya Tanikawa, Masaaki Hashimoto & Akira Matsuno

To cite this article: Makoto Katsuno, Rokuya Tanikawa, Masaaki Hashimoto & Akira Matsuno (2015): Distal internal carotid artery dissection due to the carotid shunt during carotid endarterectomy, British Journal of Neurosurgery, DOI: [10.3109/02688697.2015.1054357](https://doi.org/10.3109/02688697.2015.1054357)

To link to this article: <http://dx.doi.org/10.3109/02688697.2015.1054357>



Published online: 16 Jun 2015.



Submit your article to this journal [↗](#)



Article views: 9



View related articles [↗](#)



View Crossmark data [↗](#)

SHORT REPORT

Distal internal carotid artery dissection due to the carotid shunt during carotid endarterectomy

Makoto Katsuno¹, Rokuya Tanikawa², Masaaki Hashimoto³ & Akira Matsuno¹

¹Department of Neurosurgery, Teikyo University School of Medicine, Tokyo, Japan, ²Department of Neurosurgery, Teishinkai Hospital, Sapporo, Hokkaido, Japan, and ³Department of Neurosurgery, Abashiri Neurosurgical and Rehabilitation Hospital, Abashiri, Hokkaido, Japan

Abstract

We described two cases of shunt-related distal internal carotid artery (ICA) dissection from high cervical ICA stenosis. These cases suggest that for high cervical internal carotid endarterectomy, surgeons should reconsider using a carotid shunt to reduce the risk of ICA dissection.

Keywords: carotid endarterectomy; dissection; internal carotid artery; surgery

Introduction

Although carotid endarterectomy (CEA) has been proven by several large studies to be beneficial for selected patients, the use of a carotid shunt during CEA remains controversial. When CEA is performed through a carotid shunt, the surgeon must pay attention to the management of the shunt because cases of distal internal carotid artery (ICA) dissection have been reported.¹

At our institute, from 1997 to 2013 we routinely performed CEA using shunts in 144 patients. Among them, 23 were high position cases and two had distal ICA dissection in only high position series. In this paper, we analyzed the aetiology of these dissections and described the procedure for a safe CEA.

Case report

Case 1

The patient was a 60-year-old man who experienced right amaurosis fugax and was diagnosed with symptomatic cervical ICA stenosis. The distal end of the plaque was at the level of the second cervical vertebra (Fig. 1A). CEA was performed under general anaesthesia with dual monitoring by transcranial motor evoked potentials (MEPs). After arterectomy and confirmation of the vascular lumen, a carotid shunt was inserted into the common carotid artery

(CCA) and ICA. Then, the surgeon gently inflated the shunt balloons at CCA and ICA and confirmed smooth blood flow via the carotid shunt. CEA and vessel suture were performed according to the standard procedures without any detected changes in MEPs. Although the patient recovered from the operation without neurological deficits, postoperative three-dimensional computed tomography angiography (3D-CTA) revealed an irregular formation indicating arterial dissection proximal to the petrous segment of ICA (Fig. 1B). The patient was administered antiplatelet drugs and was eventually discharged from the hospital without any complication.

Case 2

The patient was a 62-year-old man who presented with motor aphasia and who was diagnosed with cerebral infarction on the left prefrontal territory that was caused by left cervical ICA stenosis. The level of the distal end of the plaque was at the middle of the second cervical vertebra (Fig. 2A). Two months after the onset of symptoms, CEA and vessel suture were performed, similar to Case 1, without any difficulties using a carotid shunt. However, postoperative 3D-CTA showed tapering to near occlusion at a level just proximal to the petrosal segment (Fig. 2B); this lesion changed to complete occlusion on follow-up digital subtraction angiography. Clinically, the patient gradually developed right-sided motor weakness with diffusion-weighted imaging/perfusion-weighted imaging mismatch at the left middle cerebral artery territory. Therefore, low-flow bypass using the left superficial temporal artery was performed leading to improved clinical symptoms and cerebral blood flow. The bypass patency was confirmed by postoperative 3D-CTA (Fig. 2C) and the patient was discharged from the hospital without additional complications.

Discussion

Although useful to keep cerebral blood flow during CEA, a carotid shunt carries the risk of complications such as distal

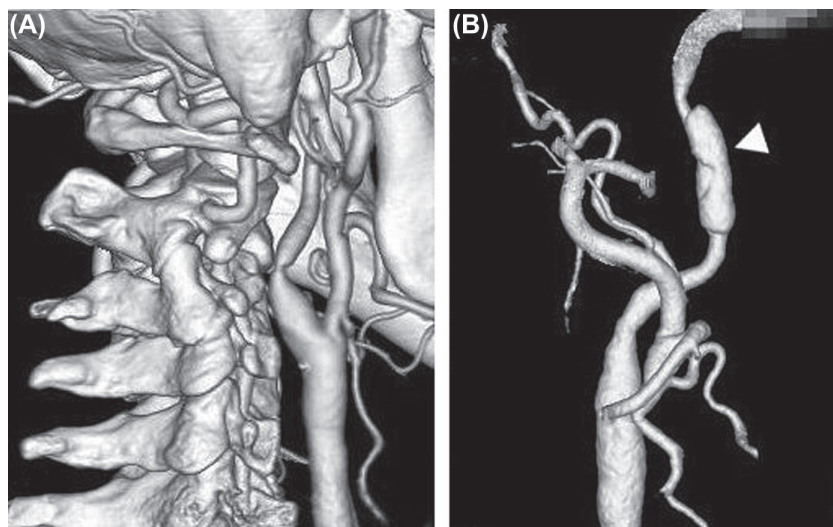


Fig. 1. Case 1. (A) Preoperative 3D-CTA demonstrating the cervical ICA stenosis at the level of the second cervical vertebra. (B) Postoperative 3D-CTA showing the irregular formation (arrowhead) at the high position of cervical ICA.

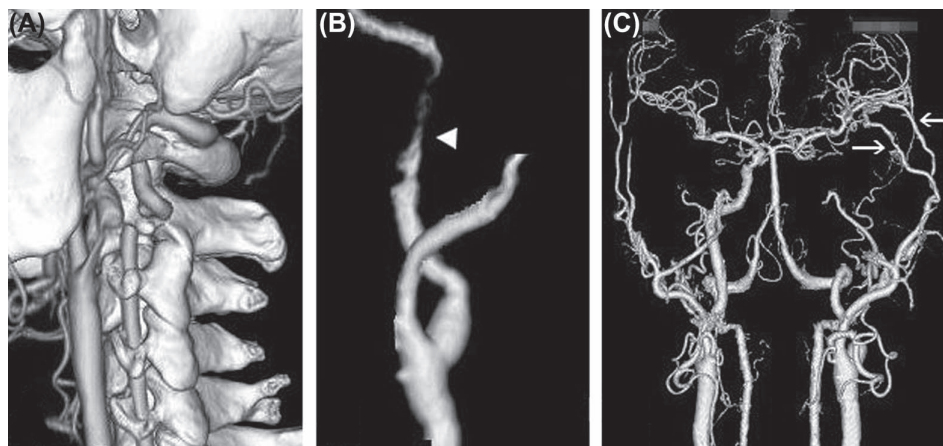


Fig. 2. Case 2. (A) Preoperative 3D-CTA demonstrating the cervical ICA stenosis at the level of the second cervical vertebra. (B) Postoperative 3D-CTA showing the near occlusion (arrowhead) at the high position of cervical ICA. (C) Post-re-operative 3D-CTA showing the good patency of superficial temporal artery-to-middle cerebral artery bypass (arrows).

ICA dissection.¹ Consequently, its use during CEA requires special attention.

Some technical points ensure the safety of a carotid shunt. First, arterectomy must be performed all the way up until a level with normal intima is confirmed. Second, a suitable size of the shunt must be inserted into the vascular lumen. Third, the amount of saline needed to inflate the balloon should be kept to a minimum. Finally, flow to the carotid shunt must be confirmed and irrigation with heparinised saline must be performed frequently. Despite having the skills and experience to safely perform CEA using a shunt while complying with the described points in all our patients, we had two cases of shunt-related arterial dissection distal to CEA. The causes of these dissections were speculated to be secondary to the tip of shunt being included in the balloon, and they may also be related to the histological characteristics of the artery. In general, the tunica media of the cervical segment of ICA gradually changes from an elastic artery to a muscular one. Specifically, the tunica media of an elastic artery contains many elastic fibres, whereas that of a muscular artery con-

tains many smooth muscle cells;² a muscular artery is more vulnerable than an elastic artery because of stress on the vascular lumen.³ Therefore, when the distal end of the plaque is in a high position as in the present cases, the probability of placing the distal tip of the shunt in a muscular artery is high, and the risk for shunt-related complications increases.

Although low-flow bypass after CEA was added in Case 2, the treatment of cervical ICA dissection is controversial. Nevertheless, we emphasise the necessity of acute bypass for intractable and progressive stroke secondary to haemodynamic stress.

In conclusion, the use of a carotid shunt for high ICA stenosis is more risky than that for low ICA stenosis because of the histological characteristic of the arterial wall. Therefore, surgeons have to reconsider its routine use and other alternatives for high ICA stenosis.

Declaration of interest: The authors report no declarations of interest. The authors alone are responsible for the content and writing of the paper.

References

1. Loftus CM, Dyste GN, Reinartz SJ, Hingtgen WL. Distal cervical carotid dissection after carotid endarterectomy: A complication of indwelling shunt? *Neurosurgery* 1986;19:441-5.
2. Janzen J, Lanzer P, Rothenberger-Janzen K, Vuong PN. Variable extension of the transitional zone in the medial structure of carotid artery tripod. *Vasa* 2001;30:101-106.
3. London GM, Guerin AP. Influence of arterial pulse and reflected waves on blood pressure and cardiac function. *Am Heart J* 1999;138:220-4.