

Cerebral sparganosis: case report and review of the European cases

Anna Lo Presti¹ · Daniel T. Aguirre¹ · Pablo De Andrés¹ · Lina Daoud² · José Fortes² · Jesús Muñiz¹

Received: 16 March 2015 / Accepted: 1 June 2015 / Published online: 18 June 2015
© Springer-Verlag Wien 2015

Abstract Sparganosis is a severe parasitic infection caused by the larvae of *Spirometra mansoni*, also called “sparganum.” In human hosts, the *Spirometra mansoni* larva commonly targets the subcutaneous tissue or muscle. Sometimes it can also migrate into the brain, resulting in cerebral sparganosis, mainly characterized by focal neurological symptoms such as seizures and radiological “wandering lesions” on magnetic resonance images (MRIs). Clinical cases of cerebral sparganosis have been reported worldwide, mainly in Asian countries, but also in North America, South America and Australia. Only two cases have been previously reported in Europe. A 29-year-old male from Bolivia, who lived in Spain, presented to our service for seizures and a multicystic brain lesion, initially suspected to be a dysembryoplastic neuroepithelial tumor (DNET). He underwent gross total resection of the mixed solid/cystic lesion. Pathology revealed gliosis, multiple interconnected cystic cavities with fibrous walls, inflammatory cell infiltration and no necrotizing granulomatous reaction. Inside the cavities, a parasitic form was identified as the larva of the cestode *Spirometra mansoni*. At 1-year follow-up, the patient had no deficits and was seizure free. Clinicians should be alerted to the possible

existence of this rare entity in Europe, especially in patients from endemic areas with a possible infection history as well as “wandering lesions” on the MRI.

Keywords Human sparganosis · Cerebral sparganosis · Europe · Stereotactic aspiration · Praziquantel

Introduction

Sparganosis is a severe parasitic infection caused by the larvae of *Spirometra mansoni*, also called “sparganum” [4, 5, 8]. Adult *Spirometra mansoni* are mainly parasitized in the intestines of cats and dogs, producing eggs that pass out with feces and reach fresh water. Coracidia hatched from these eggs are then ingested by copepods (first intermediate host), developing into larvae that are ingested by frogs, snakes, birds or mammals in which proceroids mature into plerocercoid larvae [4]. Humans are infected with sparganum by drinking water contaminated with infected copepods, eating undercooked meat of snakes or frogs infected with sparganum, or by using poultices of frog or snake flesh or skin on open wounds [4, 8, 11]. The survival period of sparganum in the human body ranges from 5 to 20 years, commonly targeting the subcutaneous tissue or muscle. However, it can also migrate into the brain, resulting in the most harmful pattern of the disease: cerebral sparganosis [8, 16]. In the past decades, clinical cases of cerebral sparganosis have been reported worldwide, mainly in Asian countries, especially in China, South Korea, Japan and Thailand [2, 8, 17, 20], but also occasionally from North America [1, 3, 10, 12], South America [9] and Australia [13]. However, to date only two cases of cerebral sparganosis have been reported in Europe [6,

✉ Anna Lo Presti
annaloprestivega@gmail.com

¹ Department of Neurosurgery, Fundación Jiménez Díaz (IIS-FJD), Autonomous University, Av. Reyes Católicos 2, 28040 Madrid, Spain

² Department of Pathology, Fundación Jiménez Díaz (IIS-FJD), Autonomous University, Madrid, Spain

19]. We present the first case of cerebral sparganosis reported in Spain and review the European cases previously published in the literature.

Case report

History and examination

A 29-year-old immunocompetent male from Bolivia, who had been living in Spain the past 3 years, presented to our service for seizures and a multicystic brain lesion. He had experienced the first seizures 4 years ago in his original country, but had never been examined for this. The month before consulting our service, he had two more seizures consisting of involuntary movements in the upper and lower limbs, which improved after antiepileptic drugs (AED) treatment. He had enjoyed good health, and his medical history was not remarkable. He was unaware of having skin lesions and denied ingestion of raw food, but used to drink water from lakes and rivers. Physical examination and blood tests were unremarkable. The magnetic resonance image (MRI) showed a multicystic intraaxial lesion involving the left temporal lobe, hypointense on T1-weighted images and hyperintense on T2-weighted images with ring enhancement after contrast administration (Fig. 1). No ventricular dilatation was evident. Functional MRI did not show significant left expressive and receptive language activation, but erratic contralateral activation was observed. Perfusion-weighted MRI did not show an increase in the relative cerebral blood volume (rCBV). With these findings the first suspected diagnosis was a dysembryoplastic neuroepithelial tumor (DNET), and a craniotomy was proposed as the first line treatment to remove the lesion.

Operation

A left temporal craniotomy was performed, followed by dural opening, showing a non-infiltrating solid gray area with a

cystic cavity inside on the cortical surface. Upon opening the cystic cavity, there was an outflow of clear liquid. A block resection of the solid part was performed.

Postoperative course

The final pathology report from the surgical resection revealed gliosis, multiple interconnected cystic cavities with fibrous walls, inflammatory cell infiltration and no necrotizing granulomatous reaction. Inside the cavities, a parasitic form was identified as the larva of the cestode *Spirometra mansoni* (Figs. 2 and 3). Postoperative MRI showed the expected postoperative changes with total resection of the lesion and no complications. The patient was discharged with a baseline examination and was free of seizures on AED treatment and tapering doses of steroids. On the 30th postoperative day the patient presented with a superficial wound infected by *Propionibacterium acnes*, which was treated with antibiotics and had a good evolution.

At the 1-year follow-up after surgery in the outpatient clinic, the patient had no deficits and was seizure-free. Follow-up MRI showed an area of encephalomalacia involving the temporal lobe with subcortical gliosis without enhancement after contrast administration (Fig. 4).

Discussion

The first published case of human sparganosis in Europe was a 40-year-old female from Genoa, Italy, in whom the sparganum was located subcutaneously in the right forearm [14, 15]. Since then, very few cases of human sparganosis have been reported in Europe, most of them from Italy and usually affecting subcutaneous tissue [14].

Besides the current case, only two prior cases of cerebral sparganosis have been reported in Europe, one in Switzerland and the other in Germany (Table 1). Diagnosis of cerebral sparganosis is usually one of exclusion and usually relies on

Fig. 1 a–b Preoperative axial FLAIR and T2WI MRI showing a cystic cavity with perilesional edema. c Preoperative axial post-contrast MRI with a ring enhancement pattern

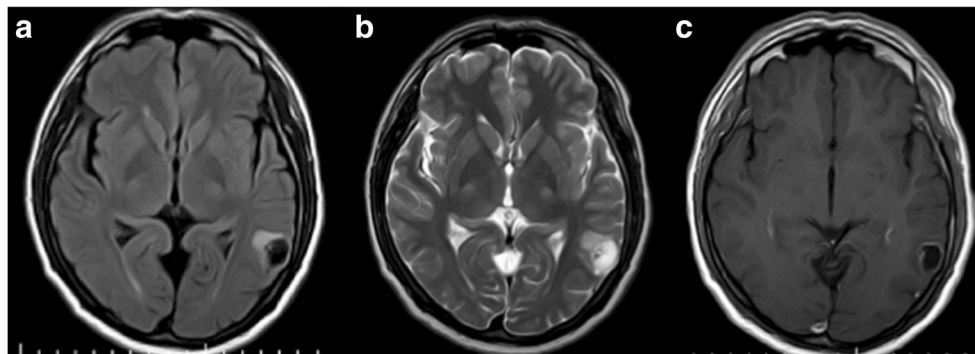
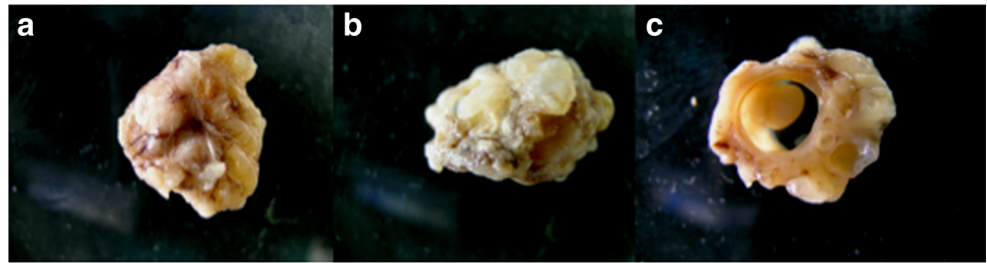


Fig. 2 The surgical excision revealed a 2-cm, white, encapsulated multicystic specimen (a, b) with a mural nodule (c) and intracystic clear fluid



histopathological verification. The differential diagnosis includes brain tumors and other infectious diseases such as neurocysticercosis and tuberculosis [16, 18]. Although it is difficult to confirm the disease at the preoperative stage, there are some characteristics that may alert physicians to this rare entity. A history of drinking untreated water, eating raw or uncooked fish, frogs or snakes, or using frog flesh as a poultice for an open wound in endemic regions can be identified in the history [8]. However, some patients have no definite risk factors for infection [8]. The two patients with cerebral sparganosis reported in Europe were from Asia (Bangladesh) and Africa (Malawi), but no information about their epidemiological history was reported. In the current case, the patient was from South America (Bolivia), and a history of drinking water from lakes and rivers in his country was presented.

Besides a dependable history, evidence of a previous or active infestation of other organs may also be a useful tool in the diagnosis. Clinical manifestations of cerebral sparganosis are closely associated with the site of the lesion [8]. The most commonly observed symptom is seizures, followed by hemiparesis, headache, body sensory disturbance and alteration in consciousness [4]. One characteristic helpful in the diagnosis of this disease is a possible alteration in the clinical manifestations with the migration of the larva through the brain [4]. Routine laboratory tests

sometimes show eosinophilia. Although the cerebrospinal fluid (CSF) in cerebral sparganosis usually has a raised white cell count with lymphocyte predominance and raised protein levels, findings can be variable, and protein and white cell counts have been reported as normal [10]. The immunological diagnostic methods are of limited use because of cross-reactivity with other cestode infestations. However, strong immunopositivity to *Spirometra mansoni* in both serum and CSF samples may also be a useful tool [8].

Neuroimaging, especially MRI, also plays an important role in the diagnosis and differential diagnosis of cerebral sparganosis. The primary characteristic of this entity on MRI is the tunnel sign seen on post-contrast sequences because of the migration of the live worm with an undulating motion. The second characteristic is the conglomerated ring or bead-shaped enhancement, which represents an inflammatory granuloma. Finally, the alternate change of varying stages in the same image is common because of the long course of the disease. In addition, unilateral ventricular dilation, focal cerebral cortical atrophy, calcification and white matter edema are also characteristic [18]. As in the current case, in our review the two patients presented with multiple or single ring-enhancing lesions, but only one showed the tunnel sign [6].

Fig. 3 Histological study showed a multicystic lesion (a–b) with a parietal granulomatous reaction (c) containing the larval form of *Spirometra mansoni* (a). In the parenchyma of the worm we observed loose stroma, calcareous bodies and smooth muscle (d–e). The body wall of the worm consisted of a tegument with microvilli, layers of smooth muscle and tegumental cells (f)

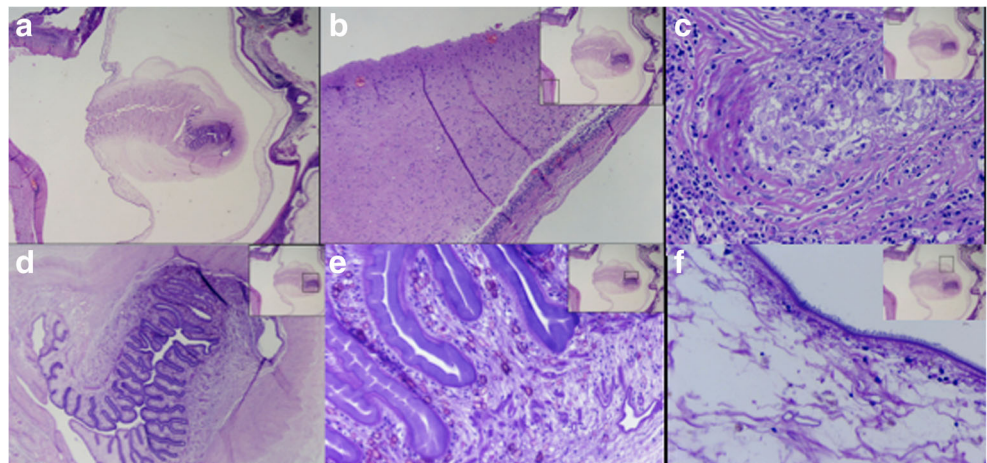
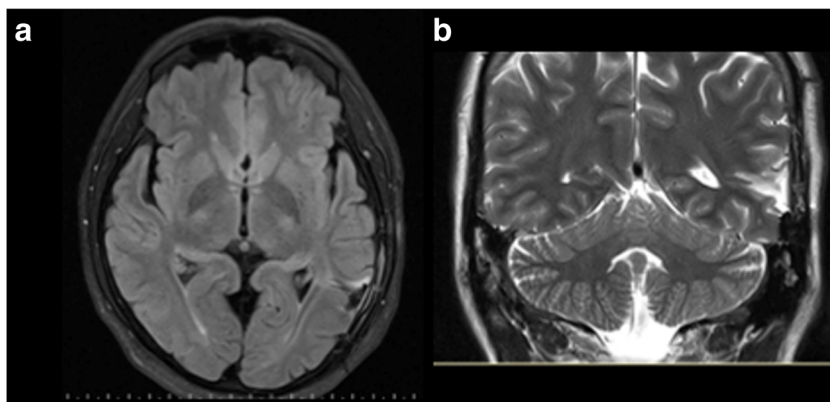


Fig. 4 a–b Postoperative axial MRI showing an area of encephalomalacia involving the temporal lobe with subcortical gliosis without enhancement after contrast administration



The treatment of choice for cerebral sparganosis is to remove the sparganum from the infested site in the brain. Lei Deng et al. proposed in 2011 that stereotactic surgery provides the most effective approach for this purpose, because this surgery creates the smallest wound and prevents broken larvae [4]. They recommended that the most enhanced feature on the CT scan or MRI should be selected as the targeting point. Aspiration should be performed in multiple directions radiating from the origin, and carefully examination of the integrity of the removed larva should be achieved, paying particular attention to the scolex. In case the larva cannot be taken out after repeated aspirations, a craniotomy should be performed [4]. On the other hand, medication with antiparasitic drugs is generally believed to be ineffective for treating cerebral sparganosis [7]. However, some authors have suggested high-dose praziquantel may be considered in inoperable cases of cerebral sparganosis following a good outcome [6, 8]. Like the case reported in Germany, in the current case the preoperative diagnosis was not cerebral sparganosis. Instead, the

authors considered a brain abscess and DNET, respectively, which led to a craniotomy as the first line approach to remove the lesion.

Conclusion

Although cerebral sparganosis is rarely reported in Europe, it should be suspected in patients from endemic areas with a possible infection history as well as “wandering lesions” on the MRI. To prevent the sequelae of the infection, histopathological verification should be attempted early by removing the sparganum from the infested site of the brain, either by stereotactic aspiration or craniotomy. In addition, praziquantel has been proposed as an effective treatment in inoperable cases. Clinical and imaging follow-up should be performed after treatment to ensure that no larva residue remains in the brain.

Table 1 Clinical features, radiological changes and treatment of patients with cerebral sparganosis reported in Europe

Case no.	Ref no.	Country of origin	Country of diagnosis	Age (years)	Clinical presentation	Epidemiological history	MRI	Initial suspected diagnosis	Treatment
1	6	Bangladesh	Switzerland	39	Seizures	Not available	Multiple ring-enhancing lesions with perifocal edema. Tunnel sign	Neurocysticercosis	Only praziquantel
2	19	Malawi	Germany	25	Seizures	Not available	Contrast-enhancing ring-shaped lesion in the right temporooccipital lobe	Cerebral abscess	Craniotomy
3	Current case	Bolivia	Spain	29	Seizures	Yes	Multicystic ring-enhancing lesion	Tumor (DNET)	Craniotomy

DNET: Dysembryoplastic neuroepithelial tumor

Acknowledgments All authors certify that they have NO affiliations with or involvement in any organization or entity with any financial interest (such as honoraria; educational grants; participation in speakers' bureaus; membership, employment, consultancies, stock ownership, or other equity interest; and expert testimony or patent-licensing arrangements), or non-financial interest (such as personal or professional relationships, affiliations, knowledge or beliefs) in the subject matter or materials discussed in this manuscript.

Conflicts of interest None.

References

- Anders K, Foley K, Stern E, Brown WJ (1984) Intracranial sparganosis: an uncommon infection. Case report. *J Neurosurg* 60:1282–1286
- Chamadol W, Tangdumrongkul S, Thanaphaisal C, Sithithaworn P, Chamadol N (1992) Intracerebral hematoma caused by sparganum: a case report. *J Med Assoc Thai* 75:602–605
- Cummings TJ, Madden JF, Gray L, Friedman AH (2000) Parasitic lesion of the insula suggesting cerebral sparganosis: case report. *Neuroradiology* 42:206–208
- Deng L, Xiong P, Qian S (2011) Diagnosis and stereotactic aspiration treatment of cerebral sparganosis: summary of 11 cases. *J Neurosurg* 114:1421–1425
- Fan KJ, Pezeshkpour GH (1986) Cerebral sparganosis. *Neurology* 36:1249–1251
- Gonzenbach RR, Kong Y, Beck B, Buck A, Weller M, Semmler A (2013) High-dose praziquantel therapy for cerebral sparganosis. *J Neurol* 260:1423–1425
- Holodniy M, Almenoff J, Loutit J (1991) Cerebral sparganosis: case report and review. *Rev Infect Dis* 13:155–159
- Hong D, Xie H, Zhu M, Wan H, Xu R, Wu Y (2013) Cerebral sparganosis in mainland Chinese patients. *J Clin Neurosci* 20:1514–1519
- Jones MC, Agosti MR, D'Agustini M, Uriarte V, Drut R (2013) Cerebral sparganosis in a child: case report. *Arch Argent Pediatr* 111:1–4
- Kwon JH, Kim JS (2004) Sparganosis presenting as a conus medullaris lesion—case report and literature review of the spinal sparganosis. *Arch Neurol* 61:1126–1128
- Li MW, Song HQ, Li C, Lin HY, Xie WT, Lin RQ, Zhu XQ (2011) Sparganosis in mainland China. *Int J Infect Dis* 15:54–56
- Mitchell A, Scheithauer BW, Kelly PJ, Forbes GS, Rosenblatt JE (1990) Cerebral sparganosis. Case report. *J Neurosurg* 73:147–150
- Munckhof WJ, Grayson ML, Susil BJ, Pullar MJ, Turnidge J (1994) Cerebral sparganosis in an East Timorese refugee. *Med J Aust* 161:263–264
- Pampiglione S, Fioravanti ML, Rivasi F (2003) Human sparganosis in Italy: case report and review of the European cases. *APMIS* 111:349–354
- Pujatti D (1953) Un caso di sparganosi umana. *Riv Parassitol* 14:213–217
- Rengarajan S, Nanjgowda N, Bhat D, Mahadevan A, Sampath S, Krishna S (2008) Cerebral sparganosis: a diagnostic challenge. *Br J Neurosurg* 22:784–786
- Shirakawa K, Yamasaki H, Ito A, Miyajima H (2010) Cerebral sparganosis: the wandering lesion. *Neurology* 74:180
- Song T, Wang WS, Zhou BR, Mai WW, Li ZZ, Guo HC, Zhou F (2007) CT and MR characteristics of cerebral sparganosis. *AJNR Am J Neuroradiol* 28:1700–1705
- Walker P, Cooper NK, Brandis A (2007) Cerebral sparganosis presenting as grand mal epilepsy. *J R Army Med Corps* 153:189–190
- Wong CW, Ho YS (1994) Intraventricular haemorrhage and hydrocephalus caused by intraventricular parasitic granuloma suggesting cerebral sparganosis. *Acta Neurochir* 129:205–208

Patient Consent

The patient consented to the submission of the case report

Comments

Lo Presti and co-workers describe a case of cerebral sparganosis, a severe parasitic infection mainly seen in Asia and only described twice—now three times—in Europe. Even though the present case is not really a European one—the 29-year-old male was from Bolivia, now living in Spain—the careful documentation of the case along with the aspect of enlarging our repertoire of differential diagnoses warrants its publication.

Marcus Reinges
Giessen, Germany