

# Reversible Cerebral Vasoconstriction Syndrome and Posterior Reversible Encephalopathy Syndrome in a Boy with Loeys-Dietz Syndrome

Yohei Akazawa,<sup>1</sup> Yuji Inaba,<sup>1\*</sup> Akira Hachiya,<sup>1</sup> Noriko Motoki,<sup>1</sup> Satoshi Matsuzaki,<sup>1</sup> Kenji Minatoya,<sup>2</sup> Takayuki Morisaki,<sup>3</sup> Hiroko Morisaki,<sup>3</sup> Kenjiro Kosaki,<sup>4</sup> Tomoki Kosho,<sup>5\*\*</sup> and Kenichi Koike<sup>1</sup>

<sup>1</sup>Department of Pediatrics, Shinshu University School of Medicine, Matsumoto, Japan

<sup>2</sup>Department of Vascular Surgery, National Cerebral and Cardiovascular Center, Suita, Japan

<sup>3</sup>Department of Bioscience and Genetics, National Cerebral and Cardiovascular Center Research Institute, Suita, Japan

<sup>4</sup>Department of Pediatrics, Keio University School of Medicine, Tokyo, Japan

<sup>5</sup>Department of Medical Genetics, Shinshu University School of Medicine, Matsumoto, Japan

Manuscript Received: 16 April 2015; Manuscript Accepted: 25 May 2015

Loeys-Dietz syndrome (LDS) is an autosomal dominant connective tissue disorder, caused by heterozygous mutations in *TGFBR1* or *TGFBR2* and characterized by vascular complications (cerebral, thoracic, and abdominal arterial aneurysms and/or dissections) and skeletal manifestations. We here report the first patient with LDS presenting with reversible cerebral vasoconstriction syndrome (RCVS), a clinico-radiological condition characterized by recurrent thunderclap headaches, with or without neurological symptoms, and reversible vasoconstriction of cerebral arteries. The patient was a 9-year-old boy with a heterozygous *TGFBR2* mutation, manifesting camptodactyly, talipes equinovarus, and lamboid craniosynostosis. He complained of severe recurrent headaches 2 months after total aortic replacement for aortic root dilatation and a massive Stanford type B aortic dissection. A thoracic CT scan revealed a left subclavian artery dissection. Brain MRI and MRA detected bilateral internal carotid artery constriction along with a cortical subarachnoid hemorrhage without intracranial aneurysms. Subsequently, he developed visual disturbance and a generalized seizure associated with multiple lesions of cortical and subcortical increased signals including the left posterior lobe, consistent with posterior reversible encephalopathy syndrome (PRES), a condition characterized by headaches, visual disorders, seizures, altered mentation, consciousness disturbances, focal neurological signs, and vasogenic edema predominantly in the white matter of the posterior lobe. Vasoconstriction of the internal carotid artery was undetectable 2 months later, and he was diagnosed as having RCVS. Endothelial dysfunction, associated with impaired TGF- $\beta$  signaling, might have been attributable to the development of RCVS and PRES.

© 2015 Wiley Periodicals, Inc.

**Key words:** Loeys-Dietz syndrome (LDS); reversible cerebral vasoconstriction syndrome (RCVS); posterior reversible encephalopathy syndrome (PRES); endothelial dysfunction

## How to Cite this Article:

Akazawa Y, Inaba Y, Hachiya A, Motoki N, Matsuzaki S, Minatoya K, Morisaki T, Morisaki H, Kosaki K, Kosho T, Koike K. 2015. Reversible cerebral vasoconstriction syndrome and posterior reversible encephalopathy syndrome in a boy with loeys-dietz syndrome.

Am J Med Genet Part A 167A:2435–2439.

## INTRODUCTION

Loeys-Dietz syndrome (LDS) is an autosomal dominant connective tissue disorder originally caused by heterozygous mutations in the genes encoding type I or II transforming growth factor- $\beta$

Grant sponsor: Grant-in-Aid for Scientific Research (C) from the Ministry of Education, Culture, Sports, Science and Technology of Japan; Grant number: #25460405; Grant sponsor: Japan Foundation for Pediatric Research; Grant sponsor: Medical Research Encouragement Prize of The Japan Medical Association; Grant sponsor: Research on Intractable Diseases, Ministry of Health, Labour and Welfare, Japan .

\*Correspondence to: Yuji Inaba: MD, PhD, Department of Pediatrics, Shinshu University School of Medicine, 3-1-1 Asahi, Matsumoto 390-8621, Japan.

E-mail: inabay@shinshu-u.ac.jp

\*\*Correspondence to: Tomoki Kosho, MD, Department of Medical Genetics, Shinshu University School of Medicine, 3-1-1 Asahi, Matsumoto 390-8621, Japan.

E-mail: ktomoki@shinshu-u.ac.jp

Article first published online in Wiley Online Library (wileyonlinelibrary.com): 22 June 2015

DOI 10.1002/ajmg.a.37202

(TGF- $\beta$ ) receptor (*TGFBR1*, *TGFBR2*) and clinically characterized by aortic aneurysms, generalized arterial tortuosity, hypertelorism, and bifid/broad uvula or cleft palate [Loeys et al., 2005, 2006]. Subsequently, mutations in the mothers against decapentaplegic homolog 3 (*SMAD3*) gene and the transforming growth factor  $\beta$  2 ligand gene (*TGFB2*) were reported in individuals with typical manifestations of LDS [van de Laar et al., 2011; Regalado et al., 2011; Boileau et al., 2012; Lindsay et al., 2012]. Typical clinical features involve four systems: *vascular*, dilatation, or dissection of the aorta, other arterial aneurysms and tortuosity; *skeletal*, pectus excavatum, or pectus carinatum, scoliosis, joint laxity, or contracture, arachnodactyly, talipes equinovarus, cervical spine malformation, and/or instability; *craniofacial*, widely spaced eyes, bifid uvula/cleft palate, craniosynostosis; *cutaneous*, translucent skin, easy bruising, dystrophic scars. The major source of morbidity and early mortality in LDS is dilatation of the aorta at the level of the sinuses of Valsalva, a predisposition for aortic dissection and rupture. Aortic dissection is likely to occur at smaller aortic diameters than observed in Marfan syndrome (MFS), and pharmacological intervention to reduce hemodynamic stress including beta-adrenergic blockers and early and aggressive surgery are recommended [Loeys and Dietz, 2013; MacCarrick et al., 2014]. Tissues derived from affected individuals showed increased expression of both collagen and connective tissue growth factor, as well as nuclear enrichment of phosphorylated Smad2, indicative of increased TGF- $\beta$  signaling [Loeys et al., 2005]. Headaches were reported in as much as 50% of individuals with *SMAD3* mutations and phenotypes that could be categorized as LDS [van de Laar et al., 2012], though no relationship to cerebrovascular abnormalities has been observed [MacCarrick et al., 2014].

Reversible cerebral vasoconstriction syndrome (RCVS) is a clinico-radiological condition, characterized by recurrent sudden-onset severe “thunderclap” headaches mimicking those of a ruptured intracranial aneurysm, with or without concomitant neurologic signs and symptoms, in the context of prolonged but reversible vasoconstriction of cerebral arteries [Chen et al., 2010; Mehdi and Hajj-Ali, 2014]. Diagnostic criteria proposed by Calabrese et al. [2007] included (1) acute severe headache, often thunderclap, with or without neurologic signs and symptoms; (2) demonstration of multifocal segmental cerebral artery vasoconstriction via direct (catheter) or indirect angiography; (3) absence of aneurysmal subarachnoid hemorrhage; (4) normal, or near normal, CSF analysis; (5) demonstration of reversibility of angiographic findings within 12 weeks of disease onset. RCVS in 30–60% of cases were reported to occur in the context of underlying conditions or exposures, including pregnancy-related ones, drugs, headache disorders, medical problems, surgical procedures, blood product transfusion, and miscellaneous [Mehdi and Hajj-Ali, 2014]. Non-aneurysmal cortical subarachnoid hemorrhage was reported to occur in one-third of cases [Ducros, 2010; Singhal et al., 2011]. Clinical features of RCVS are shared by posterior reversible encephalopathy syndrome (PRES), characterized clinically by headache, visual disorders, seizures, altered mentation, consciousness disturbances, and focal neurological signs and neuroradiologically by symmetrical areas of vasogenic edema of the white matter predominantly localized in the territories of posterior circulation [Marra et al., 2014; Rykken and McKinney, 2014].

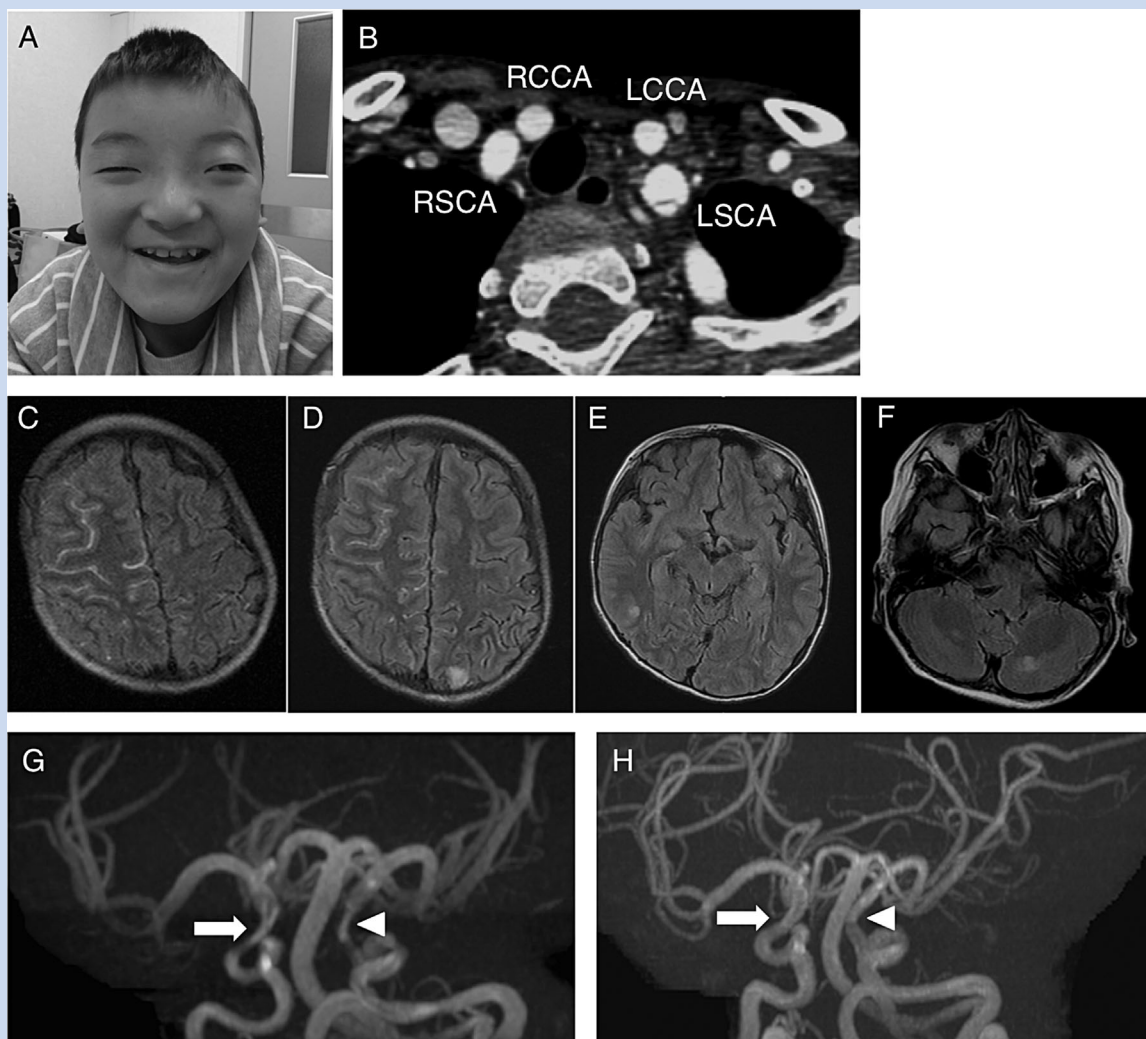
PRES is a complex condition with many clinical associations, many causative factors, and a variety of imaging manifestations; and its pathophysiology remains a topic of debate [Rykken and McKinney, 2014]; and was reported to occur in 10–38% of RCVS cases [Stoessel et al., 1985; Ducros et al., 2007; Ducros, 2010; Singhal et al., 2011].

In this report, we describe the first patient with LDS, who showed acute and severe headaches and was diagnosed as having RCVS and PRES.

## CLINICAL REPORTS

The patient, a 9-year-old boy, was the second child of healthy non-consanguineous Japanese parents. None of his parents or sister manifested LDS-related physical features. Pregnancy was complicated by fetal arrhythmia. He was born at 38 weeks and 2 days of gestation by spontaneous vaginal delivery. Arrhythmia disappeared after birth. His birth weight was 2766 g (–0.6 SD), length was 51 cm (+1.5 SD), and occipital-frontal circumference was 33.5 cm (+0.3 SD). He had micrognathia, low-set ears, camptodactyly of both hands, bilateral talipes equinovarus, and a periventricular cyst on a brain ultrasonography; and was suspected to have distal arthrogryposis syndrome. At age 7 months, a brain magnetic resonance imaging (MRI) showed mild ventricular enlargement and no cyst. He had hypertelorism, bifid uvula, synostosis of lamboid sutures, and developmental delay, which suggested the diagnosis of Shprintzen-Goldberg syndrome at age 10 months. A cardiac ultrasonography showed dilatation and tortuosity of the ascending aorta, aortic arch, and descending aorta. An ophthalmological examination showed familial exudative vitreoretinopathy accompanied by amblyopia. At age 4 years, a genetic investigation revealed a heterozygous missense mutation (R528P) in *TGFBR2*, and he was diagnosed with LDS. He started to have an angiotensin type-II receptor blocker losartan, followed by several episodes of pure vasodepressor type syncope displaying consciousness loss, facial paleness, and low body temperature that recovered within several hours. At age 6 years, his intelligence was normal with a full-scale intelligence quotient (IQ) as 92 (a verbal IQ, 100; a performance IQ, 85) on WISC-III. At age 8 years, dilatation of the sinus of Valsalva progressed (40 mm, Z-score 5.6), though he had had preventive treatment with propranolol as well as losartan. At age 9 years, his facial features included hypertelorism, a thin upper lip vermilion (Fig. 1A), and characteristic ears (bilateral angulated antihelices, right underdeveloped, and left prominent antitragus, and bilateral overfolded helices); and he attended a school for the blind. He developed a massive aortic dissection, Stanford type B, and underwent total aortic replacement.

Two months after the operation, he was admitted to our hospital because of a sudden-onset severe headache, nausea, and vomiting persisting for 9 hr. His weight was 25.1 kg (–1.2 SD), height was 137.3 cm (–0.1 SD), and blood pressure was 98/55 mmHg. He was alert and exhibited no abnormal focal neurological symptoms apart from a mild meningeal sign. A brain MRI and magnetic resonance angiography (MRA) revealed a right parietal cortical subarachnoid hemorrhage (Fig. 1C) and mild narrowing of the bilateral internal carotid arteries, but no aneurysms. A thoracic computed tomography angiography showed a left subclavian artery dissection (Fig. 1B). The only remarkable laboratory finding was an increased



**Fig. 1.** [A] A facial photograph at age 9 years, showing hypertelorism, and a thin upper lip vermilion. [B] An enhanced thoracic CT, showing a dissection of the left subclavian artery. LSCA, left subclavian artery; RSCA, right subclavian artery; LCCA, left common carotid artery; RCCA, right common carotid artery. A brain MRI (FLAIR) on the day of admission [C], showing high intensity lesions along sulci of the right parietal lobe indicating a cortical subarachnoid hemorrhage; on the 6th day of admission, showing high intensity lesions in the left occipital lobe [D], the right temporal lobe [E], and bilateral cerebellum [F]. A brain MRA on the 5th day of admission [G], showing significant narrowing of the bilateral internal carotid arteries with a diameter of the left as 1.2 mm [arrowhead] and that of the right as 1.3 mm [arrow], but no intracranial aneurysms; at 2 months after admission [H], showing marked improvement of vasoconstriction of the bilateral internal carotid arteries with a diameter of the left as 2.6 mm [arrowhead] and that of the right as 3.2 mm [arrow].

FDP D-dimer level to 7.5  $\mu\text{g/ml}$  (range, 0.0–1.0). His headaches worsened despite the administration of acetaminophen. On the 5th day of admission, a brain MRA demonstrated significant narrowing of the bilateral internal carotid arteries (Fig. 1G). On the next day, his blood pressure was elevated to 154/101 mmHg and he complained of visual disturbance followed by a generalized tonic clonic seizure. A fluid attenuated inversion recovery (FLAIR) mode of MRI demonstrated multiple lesions of cortical and subcortical increased signals (the left posterior lobe, the right temporal lobe, and bilateral cerebellum) (Fig. 1D–F). His seizure ceased with the administration of midazolam, with no neurological or visual sequela. His blood pressure was controlled within a normal range

through administration of nicardipine. On the 13th day of admission, his headache disappeared. Two months later, brain MRI, and MRA demonstrated recovery of PRES and normalization of the bilateral internal carotid arteries (Fig. 1H), and he was diagnosed as having RCVS.

## DISCUSSION

The present patient had acute severe headaches accompanied by a mild meningeal sign, and visual disturbance and a seizure after an elevation of blood pressure. Brain MRI/MRA showed significant narrowing of the bilateral internal carotid arteries, a right parietal

cortical subarachnoid hemorrhage not related to an aneurysmal rupture, and multiple lesions of cortical and subcortical increased signals (the left posterior lobe, the right temporal lobe, and bilateral cerebellum). Furthermore, a complete clinical and radiological recovery was observed within 2 months after the onset. These features and courses were compatible with the diagnosis of RCVS according to the criteria by Calabrese et al. [2007]; and also with that of PRES that could be accompanied by RCVS [Stoessel et al., 1985; Ducros et al., 2007; Ducros, 2010; Singhal et al., 2011].

RCVS was supposed to occur, in the present patient, associated with his specific medical conditions including LDS, post-total aortic replacement for a massive aortic dissection, a recent dissection of the left subclavian artery, and subarachnoid hemorrhage; or it might have been a coincidental event. A recent review by Mehdi and Hajj-Ali [2014] described underlying medical conditions to RCVS including hypercalcemia, porphyria, pheochromocytoma, bronchial carcinoid tumor, unruptured saccular cerebral aneurysm, head trauma, spinal subdural hematoma, carotid glomus tumor, post-bone marrow transplant, thrombotic thrombocytopenic purpura, systemic lupus erythematosus, and anti-phospholipid antibody syndrome. Vasoreactive drugs, postpartum, and cervical/vertebral artery dissection were also reported to be precipitating factors of RCVS [Ducros et al., 2012; Mawet et al., 2013]. RCVS occurs predominantly in middle-aged women and is rarely seen in children [Chen et al., 2010]. A preceding subclavian artery dissection, associated with arterial wall fragility, could have been a trigger for the occurrence of RCVS in the present patient, but it is not considered to be a predominant cause for RCVS because the patient showed no cerebral/cervical/vertebral artery dissection and the association of RCVS and cervical artery dissection was not reported to be so strong (only 7% of patients with cervical artery dissection showed RCVS) [Mawet et al., 2013]. Furthermore, subarachnoid hemorrhage in the present patient was considered to be a complication accompanied by RCVS, rather than a trigger for RCVS; because the subarachnoid hemorrhage was cortical-type not associated with intracranial artery rupture.

Although the mechanism of RCVS remains unclear, several hypotheses were proposed in previous reports: some vasoactive substances, released from a dissection; aortopathy-like weakening of the arterial wall, due to hormonal effects in pregnancy [Solatanolkotabi et al., 2011; Mawet et al., 2013; Mitchell et al., 2014]. Since vascular endothelium has been considered to play a central role in the regulation of vascular tone, endothelial dysfunction may affect the maintenance of cerebral arterial tone to trigger vasoconstriction and further exacerbate the dysfunction [Chen et al., 2011]. Complications related to RCVS were reported to include cortical subarachnoid hemorrhage (22%), PRES (9%), intracerebral hemorrhage (6%), and seizures (3%) within the first week after the onset [Ducros et al., 2007]. These complications were supposed to result from disruptions in small vessels and blood-brain barrier functions that might be attributed to endothelial dysfunction [Chen et al., 2010, 2011; Ducros et al., 2012]. There have been growing evidences of impaired endothelial function in the development of aortic lesions in MFS [Wilson et al., 1999; Chung et al., 2007; Syong et al., 2009; Yang et al., 2010; Takata et al., 2014]. Mouse models for LDS were reported to show overactive TGF- $\beta$  signaling in aortic vessels [Gallo et al., 2014], similar to those with

MFS [Habashi et al., 2006]. Thus, RCVS, together with PRES, in the present patient might have occurred in relation to endothelial dysfunction associated with overactive TGF- $\beta$  signaling caused by a *TGFBR2* mutation. Pure vasopressor type syncope observed after the initiation of losartan in the present patient might have also been related to endothelial dysfunction in the cerebral arteries.

In conclusion, we reported the first known patient with LDS who exhibited RCVS, together with PRES. These consequences might have been related to endothelial dysfunction, associated with impaired TGF- $\beta$  signaling. LDS patients might carry a potential risk of RCVS with/without PRES and the possibilities of RCVS/PRES are recommended to be considered in the differential diagnosis of severe sudden-onset headaches and subarachnoid hemorrhages in LDS patients.

## ACKNOWLEDGMENTS

We are grateful to the patient and his family for their cooperation in this study. This study was supported by Grant-in-Aid for Scientific Research (C) from the Ministry of Education, Culture, Sports, Science and Technology of Japan (#25460405) (T. Kosho), the Japan Foundation for Pediatric Research (T. Kosho), Medical Research Encouragement Prize of The Japan Medical Association (T. Kosho), and Research on Intractable Diseases, Ministry of Health, Labour and Welfare, Japan (H. Morisaki, T. Morisaki, T. Kosho).

## REFERENCES

- Boileau C, Guo DC, Hanna N, Regalado ES, Daint D, Gong L, Varret M, Prakash SK, Li AH, d'Indy H, Braverman AC, Grandchamp B, Kwartler CS, Gouya L, Santos-Cortez RL, Abifadel M, Leal SM, Muti C, Shendure J, Gross MS, Rieder MJ, Vahanian A, Nickerson DA, Michel JB, National Heart, Lung, and Blood Institute (NHLBI) Go Exome Sequencing Project, Jondeau G, Milewicz DM. 2012. TGFBR2 mutations cause familial thoracic aortic aneurysms and dissections associated with mild systemic features of Marfan syndrome. *Nat Genet* 44:916–921.
- Calabrese LH, Dodick DW, Schwedt TJ, Singhal AB. 2007. Narrative review: Reversible cerebral vasoconstriction syndromes. *Ann Intern Med* 146:34–44.
- Chen SP, Fuh JL, Wang SJ. 2010. Reversible cerebral vasoconstriction syndrome: An under-recognized clinical emergency. *Ther Adv Neurol Disord* 3:161–171.
- Chen SP, Fuh JL, Wang SJ. 2011. Reversible cerebral vasoconstriction syndrome: Current and future perspectives. *Expert Rev Neurother* 11:1265–1276.
- Chung AW, Au Yeung K, Cortes SF, Sandor GG, Judge DP, Dietz HC, van Breemen C. 2007. Endothelial dysfunction and compromised eNOS/Akt signaling in the thoracic aorta during the progression of Marfan syndrome. *Br J Pharmacol* 150:1075–1083.
- Ducros A, Porcher R, Sarov M, Valade D, Boussier MG. 2007. The clinical and radiological spectrum of reversible cerebral vasoconstriction syndrome. A prospective series of 67 patients. *Brain* 130:3091–3101.
- Ducros A. 2010. Reversible cerebral vasoconstriction syndrome. *Presse Med* 39:312–322.
- Ducros A. 2012. Reversible cerebral vasoconstriction syndrome. *Lancet Neurol* 11:906–917.

- Gallo EM, Loch DC, Habashi JP, Calderon JF, Chen Y, Bedja D, van Erp C, Gerber EE, Parker SJ, Sauls K, Judge DP, Cooke SK, Lindsay ME, Rouf R, Myers L, ap Rhys CM, Kent KC, Norris RA, Huso DL, Dietz HC. 2014. Angiotensin II-dependent TGF- $\beta$  signaling contributes to Loeys-Dietz syndrome vascular pathogenesis. *J Clin Invest* 124:448–460.
- Habashi JP, Judge DP, Holm TM, Cohn RD, Loeys BL, Cooper TK, Myers L, Klein EC, Liu G, Calvi C, Podowski M, Neptune ER, Halushka MK, Bedja D, Gabrielson K, Rifkin DB, Carta L, Ramirez F, Huso DL, Dietz HC. 2006. Losartan, an AT1 antagonist, prevents aortic aneurysm in a mouse model of Marfan syndrome. *Science* 312:117–21.
- Lindsay ME, Schepers D, Bolar NA, Doyle JJ, Gallo E, Fert-Bober J, Kempers MJ, Fishman EK, Chen Y, Myers L, Bjeda D, Oswald G, Elias AF, Levy HP, Anderlid BM, Yang MH, Bongers EM, Timmermans J, Braverman AC, Canham N, Mortier GR, Brunner HG, Byers PH, Van Eyk J, Van Laer L, Dietz HC, Loeys BL. 2012. Loss-of-function mutations in TGFB2 cause a syndromic presentation of thoracic aortic aneurysm. *Nat Genet* 44:922–927.
- Loeys BL, Chen J, Neptune ER, Judge DP, Podowski M, Holm T, Meyers J, Leitch CC, Katsanis N, Sharifi N, Xu FL, Myers LA, Spevak PJ, Cameron DE, De Backer J, Hellems J, Chen Y, Davis EC, Webb CL, Kress W, Coucke P, Rifkin DB, De Paepe AM, Dietz HC. 2005. Syndrome of altered cardiovascular, craniofacial, neurocognitive and skeletal development caused by mutations in TGFB1 or TGF BR2. *Nat Genet* 37:275–281.
- Loeys BL, Schwarze U, Holm T, Callewaert BL, Thomas GH, Pannu H, De Backer JF, Oswald GL, Symoens S, Manouvrier S, Roberts AE, Faravelli F, Greco MA, Pyeritz RE, Milewicz DM, Coucke PJ, Cameron DE, Braverman AC, Byers PH, De Paepe AM, Dietz HC. 2006. Aneurysm syndromes caused by mutations in the TGF-beta receptor. *N Engl J Med* 355:788–798.
- Loeys BL, Dietz HC. 2013. Loeys-Dietz syndrome. In: S Pagon F RA, S Adam F MP, S Bird F TD, S et S al., C editors. *GeneReviews*<sup>®</sup> [Internet]. Seattle (WA): University of Washington, Seattle; 1993-2015. Available from: <http://www.ncbi.nlm.nih.gov/books/NBK1116/>. Accessed Jan 20, 2015.
- MacCarrick G, Black JH, Bowdin S, El-Hamamsy I, Frischmeyer-Guerrero PA, Guerrero AL, Sponseller PD, Loeys B, Dietz HC. 2014. Loeys-Dietz syndrome: A primer for diagnosis and management. *Genet Med* 16:576–587.
- Marra A, Vargas M, Striano P, Del Guercio L, Buonanno P, Servillo G. 2014. Posterior reversible encephalopathy syndrome: The endothelial hypotheses. *Medical Hypotheses* 82:619–622.
- Mawet J, Boukobza M, Franc J, Sarov M, Arnold M, Bousser MG, Ducros A. 2013. Reversible cerebral vasoconstriction syndrome and cervical artery dissection in 20 patients. *Neurology* 81:821–824.
- Mehdi A, Hajj-Ali RA. 2014. Reversible cerebral vasoconstriction syndrome: A comprehensive update. *Curr Pain Headache Rep* 18:443.
- Mitchell LA, Santarelli JG, Singh IP, Do HM. 2014. Reversible cerebral vasoconstriction syndrome and bilateral vertebral artery dissection presenting in a patient after cesarean section. *J Neurointerv Surg* 6: e5.
- Regalado ES, Guo DC, Villamizar C, Avidan N, Gilchrist D, McGillivray B, Clarke L, Bernier F, Santos-Cortez RL, Leal SM, Bertoli-Avella AM, Shendure J, Rieder MJ, Nickerson DA, Milewicz DM. NHLBI GO Exome Sequencing Project 2012. Exome sequencing identifies SMAD3 mutations as a cause of familial thoracic aortic aneurysm and dissection with intracranial and other arterial aneurysms. *Circ Res* 109:680–686.
- Rykken JB, McKinney. 2014. Posterior reversible encephalopathy syndrome. *Semin Ultrasound CT MRI* 35:118–135.
- Singhal AB, Hajj-Ali RA, Topcuoglu MA, Fok J, Bena J, Yang D, Calabrese LH. 2011. Reversible cerebral vasoconstriction syndromes: Analysis of 139 cases. *Arch Neurol* 68:1005–1012.
- Soltanolkotabi M, Ansari SA, Shaibani A, Singer TB, Hurley MC. 2011. Spontaneous post-partum cervical carotid artery dissection in a patient with reversible cerebral vasoconstriction syndrome. *Interv Neuroradiol* 17:486–489.
- Stoessl AJ, Young GB, Feasby TE. 1985. Intracerebral haemorrhage and angiographic beading following ingestion of catecholaminergics. *Stroke J Cereb Circ* 16:734–736.
- Syyong HT, Chung AW, Yang HH, van Breemen C. 2009. Dysfunction of endothelial and smooth muscle cells in small arteries of a mouse model of Marfan syndrome. *Br J Pharmacol* 158:1597–1608.
- Takata M, Amiya E, Watanabe M, Omori K, Imai Y, Fujita D, Nishimura H, Kato M, Morota T, Nawata K, Ozeki A, Watanabe A, Kawarasaki S, Hosoya Y, Nakao T, Maemura K, Nagai R, Hirata Y, Komuro I. 2014. Impairment of flow-mediated dilation correlates with aortic dilation in patients with Marfan syndrome. *Heart Vessels* 29:478–485.
- Takata M, Amiya E, Watanabe M, Omori K, Imai Y, Fujita D, Nishimura H, Kato M, Morota T, Nawata K, Ozeki A, Watanabe A, Kawarasaki S, Hosoya Y, Nakao T, Maemura K, Nagai R, Hirata Y, Komuro I. 2014. Impairment of flow-mediated dilation correlates with aortic dilation in patients with Marfan syndrome. *Heart Vessels* 29:478–485.
- van de Laar IM, Oldenburg RA, Pals G, Roos-Hesselink JW, de Graaf BM, Verhagen JM, Hoedemaekers YM, Willemsen R, Severijnen LA, Venselaar H, Vriend G, Pattynama PM, Collée M, Majoer-Krakauer D, Poldermans D, Frohn-Mulder IM, Micha D, Timmermans J, Hilhorst-Hofstee Y, Bierma-Zeinstra SM, Willems PJ, Kros JM, Oei EH, Oostra BA, Wessels MW, Bertoli-Avella AM. 2011. Mutations in SMAD3 cause a syndromic form of aortic aneurysms and dissections with early-onset osteoarthritis. *Nat Genet* 43:121–126.
- van de Laar IM, van der Linde D, Oei EH, Bos PK, Bessems JH, Bierma-Zeinstra SM, van Meer BL, Pals G, Oldenburg RA, Bekkers JA, Moelker A, de Graaf BM, Matyas G, Frohn-Mulder IM, Timmermans J, Hilhorst-Hofstee Y, Cobben JM, Bruggenwirth HT, van Laer L, Loeys B, De Backer J, Coucke PJ, Dietz HC, Willems PJ, Oostra BA, De Paepe A, Roos-Hesselink JW, Bertoli-Avella AM, Wessels MW. 2012. Phenotypic spectrum of the SMAD3-related aneurysms-osteoarthritis syndrome. *J Med Genet* 49:47–57.
- Wilson DG, Bellamy MF, Ramsey MW, Goodfellow J, Brownlee M, Davies S, Wilson JF, Lewis MJ, Stuart AG. 1999. Endothelial function in Marfan syndrome: Selective impairment of flow-mediated vasodilation. *Circulation* 99:909–915.
- Yang HH, van Breemen C, Chung AW. 2010. Vasomotor dysfunction in the thoracic aorta of Marfan syndrome is associated with accumulation of oxidative stress. *Vascul Pharmacol* 52:37–45.