

Is one motor cortex enough for two hands?

SIMONA FIORI¹ | MARTIN STAUDT^{2,3} | KERSTIN PANNEK⁴ | DAVIDE BORGHETTI¹ | LAURA BIAGI¹ |
DANILO SCELFO¹ | STEPHEN E ROSE⁴ | MICHELA TOSETTI¹ | GIOVANNI CIONI^{1,5} | ANDREA GUZZETTA^{1,5}

1 IRCCS Stella Maris Foundation, Pisa, Italy. **2** Clinic for Neuropediatrics and Neurorehabilitation, Epilepsy Center for Children and Adolescents, Schön Klinik Vogtareuth; **3** Department of Pediatric Neurology and Developmental Medicine, University Children's Hospital, Tübingen, Germany. **4** The Australian e-Health Research Centre CSIRO, Royal Brisbane and Women's Hospital, Brisbane, Qld, Australia. **5** Department of Clinical and Experimental Medicine, University of Pisa, Pisa, Italy.

Correspondence to Andrea Guzzetta at Stella Maris Scientific Institute, Viale del Tirreno 331, 56128 Pisa, Italy. E-mail: a.guzzetta@fsm.unipi.it

This article is commented on by Basu on pages 897–898 of this issue.

PUBLICATION DATA

Accepted for publication 4th May 2015.

Published online 22nd June 2015.

ABBREVIATION

ADM Abductor digiti minimi

We report on a patient with mirror movements sustained by a mono-hemispheric fast control of bilateral hand muscles and normal hand function. Transcranial magnetic stimulation of the right motor cortex evoked contractions of muscles in both hands while no responses were observed from the left hemisphere. Somatosensory-evoked potentials, functional magnetic resonance, and diffusion tractography showed evidence of sensorimotor dissociation and asymmetry of corticospinal projections, suggestive of reorganization after early unilateral left brain lesion. This is the first evidence that, in certain rare conditions, good hand function is possible with ipsilateral corticospinal reorganization, supporting the role of unexplored mechanisms of motor recovery.

In normal conditions, each primary motor cortex (M1) is required to control voluntarily the contralateral hand. Indeed, the axons of most M1 motoneurons controlling hand muscles, cross the midline to reach the alpha motoneurons in the contralateral anterior horn of the spinal cord. Different patterns of anomalous decussations can be observed, generally associated with mirror movements (i.e. unintended mirror reversals of a contralateral voluntary movement, mostly involving distal upper limb muscles¹). In such cases, each brain hemisphere can be connected either bilaterally with spinal motoneurons (essential mirror movements or X-linked Kallmann syndrome¹) or unilaterally with their ipsilateral motoneurons (Klippel-Feil¹ or horizontal gaze palsy and progressive scoliosis²). Either way, both hemispheres are required to control the two hands.

A specific condition has been described in the case of unilateral damage to the corticospinal tract in early phases of development, typically around birth or before, when the physiological withdrawal of ipsilateral corticomotoneuronal connections has not yet occurred.³ Increased corticospinal projections from the contralesional hemisphere competitively displace surviving projections from the damaged cortex, leading to a pattern of reorganization in which both hands are controlled by the contralesional motor cortex. This pattern of reorganization, however, has so far always been reported as incomplete, i.e. in association with marked impairment of the ipsilateral hand.^{4,5}

Here, we present the exceptional case of a mono-hemispheric fast control of bilateral hand muscles and normal hand function bilaterally—except for the presence of mirror movements.

CASE REPORT

Patient

A male presented at 14 years with grade 3 mirror movements⁶ affecting either hand (see Video S1, online supporting information). Family history was negative for any mirror-movement-related disorder. Perinatal and postnatal histories were uneventful. Neurological examination was normal except for left-handedness. An extensive battery of motor tests was performed and video-recorded, including the Melbourne Assessment of Unilateral Upper Limb Function,⁷ Movement Assessment Battery for Children,⁸ and Assisting Hand Assessment,⁹ with scores within the normal range and no asymmetries (Melbourne Assessment of Unilateral Upper Limb Function score 100% on both right and left hands, Movement Assessment Battery for Children score 10^o centile, Assisting Hand Assessment score 95%). On clinical examination, the inspection of the cervical region was normal, and mobility of head and neck was also normal. Conventional brain magnetic resonance imaging (MRI) showed a mild irregular enlargement of the left lateral ventricle, most pronounced in the frontal lobe, and a decreased volume of the left caudate nucleus (Fig. S1, online supporting information). No signal abnormalities were observed at the hemispheric level or in the subcortical structures. No abnormalities were seen in the cervical spinal cord (explored down to the level of C3 on sagittal T1- and T2-weighted images). The *DCC* and *RAD51* genes were studied and no abnormalities were detected.¹⁰

Examinations

Transcranial magnetic stimulation was performed as described in Borghetti et al.¹¹ Both hemispheres were

searched systematically for ipsilateral or contralateral motor-evoked potentials, during a monitored low-level contraction of both abductor digiti minimi (ADM) muscles. No other muscles were investigated. Short-latency somatosensory-evoked potentials were obtained as described in Guzzetta et al.¹²

MRI and functional MRI (fMRI) were performed on a 1.5T MR scanner (GE, Signa Horizon 1.5, Milwaukee, WI, USA). Blood oxygenation level-dependent (BOLD) MRI were acquired during active hand movement and passive hand movement as described in Guzzetta et al.¹² BOLD MRI were also acquired during a language task as described in Guzzetta et al.¹³

Diffusion data were acquired and pre-processed following the guidelines outlined in Rose et al.¹⁴ Descending corticospinal tracts and ascending somatosensory tracts were extracted from the whole-brain tractogram by applying the brainstem and pre- and postcentral gyri as waypoints as described in Rose et al.¹⁴

RESULTS

Transcranial magnetic stimulation

A muscular response in both ADMs was obtained by stimulating the scalp at the presumed level of the right M1, with latencies of 20.0ms (right hand) and 20.0ms (left hand) at 55% of the maximum stimulator output. No muscular response was obtained on either ADMs by using stimulating intensities up to 120% of right motor threshold anywhere on the left hemisphere (Fig. S2,

What this paper adds

- Good motor control is possible with ipsilateral corticospinal reorganization.

online supporting information). Despite this high stimulation intensity used on the left hemisphere, we cannot exclude the possibility that a crossed response might have been obtained with even higher stimulation intensity.

Somatosensory-evoked potentials

For both hands, cortical responses with short latencies and normal amplitudes were obtained in the hemisphere contralateral to the stimulated arm (right hemisphere: N20=19.2ms, central conduction time=6.2ms, P25=22.4ms; left hemisphere: N20=19.6ms, central conduction time=6.0ms, P25=22.2ms). No short-latency responses were obtained ipsilaterally.

Functional MRI

Active movement of the right hand elicited bilateral activation around the central sulcus (larger on the right hemisphere), whereas right passive hand movement showed a unilateral left-hemispheric activation around the same region. Active movement of the left hand elicited bilateral activation around the central sulcus (larger on the right hemisphere) whereas passive movement showed a unilateral right-hemispheric activation around the same region. Language fMRI showed bilateral activation in several areas of the language network^{13,15} (Fig. 1).

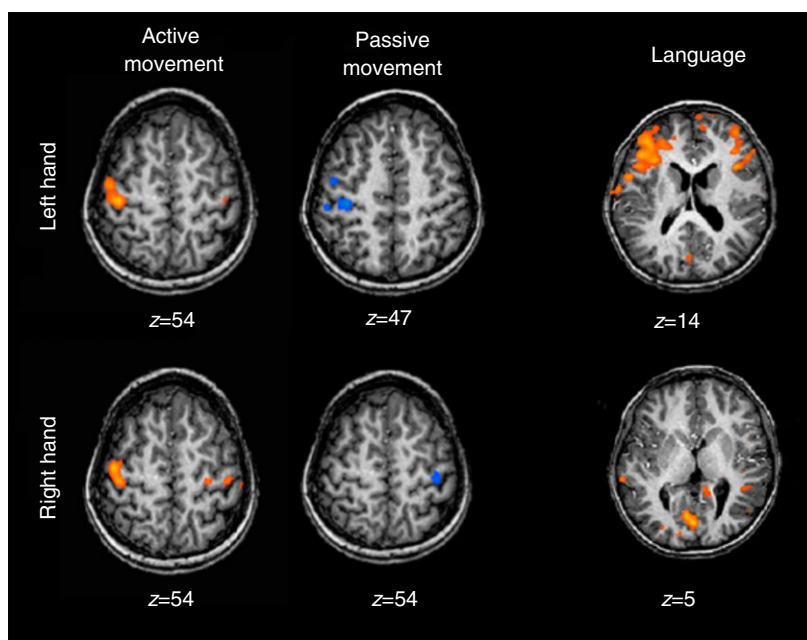


Figure 1: fMRI, motor, and language tasks. Active left hand movements (left, top) activate regions around the central sulcus bilaterally (right prevalence); active right hand movements (left, bottom) activate regions around the central sulcus bilaterally (right prevalence). Passive left hand movements (middle, top) activate right regions around the central sulcus; passive right hand movements (middle, bottom) activate left regions around the central sulcus. The language task shows bilateral activation of Broca (right, top) and Wernicke (right, bottom) areas.

Fibre tractography

An asymmetry in the corticospinal projections from pre- and postcentral gyri to the posterior limb of internal capsule (streamline number 65% higher on the right hemisphere) was found, as opposed to a more symmetric course in the ascending projections from the thalamus to the pre- and postcentral gyri (streamline number 9% higher on the left hemisphere) (Fig. S3, online supporting information).

DISCUSSION

To our knowledge, this is the first case of mono-hemispheric primary motor control of both hands without hemiparesis.

The patient presented with mirror movements and left-handedness. The combination of transcranial magnetic stimulation, fMRI, and MR tractography indicated that fast-conducting corticospinal projections to the right hand originated only in the (ipsilateral) right hemisphere, while its primary somatosensory (S1) representation was in the (contralateral) left hemisphere—a ‘hemispheric dissociation’ between an ipsilateral M1 representation (in the right hemisphere) and a contralateral S1 representation (in the left hemisphere) for the right hand.

The combination of these features (the M1–S1 dissociation, the mirror movements, the left-handedness), together with atypical language representation, would be perfectly compatible with sensorimotor,^{3–5} and language reorganization^{13,15} following an early left-sided white matter lesion. Indeed, even if no unequivocal imaging evidence such as periventricular gliosis or hemosiderin residues could be seen on structural MRI, we can safely assume that the patient suffered an intrauterine unilateral periventricular brain lesion resulting in a mild irregular enlargement of the left lateral ventricle together with a decreased volume of the left caudate nucleus.

With this assumption, it becomes most remarkable that no signs for hemiparesis were evident on clinical examination and motor testing. The patient was not, however, tested on more demanding assessments of bimanual function, and it could well be that, owing to the presence of mirror movements, the scores on such assessments would have been suboptimal.¹⁶ Movement Assessment Battery for Children scores were in the borderline range, with more difficulties reported in bimanual coordination skills. Normal hand function in a patient with an early unilateral brain lesion and ipsilateral corticospinal projections has never, to our knowledge, been reported.

The simplest explanation for this good hand function, despite an ipsilateral corticospinal motor control for the right hand, would be an extraordinarily high reorganizational potential of the contralesional hemisphere in this patient. This explanation is, however, not very likely. Since the advent of MRI, hundreds of patients with congenital hemiparesis and structurally normal contralesional hemispheres have been reported; thus we can virtually exclude the possibility that an intact contralesional hemisphere alone could have been sufficient for a normal function

of the ipsilateral hand in the presence of an early unilateral brain lesion.

The more likely explanation for the constellation in the patient is an unusual combination of a highly ‘strategic’ lesion in the left hemisphere, leading to a disruption of the normal crossed corticospinal projections to the right hand, while other relevant structures crucial for the good hand function in the lesioned hemisphere remained intact. So far, we can only speculate on what these ‘other relevant structures’ in the lesioned hemisphere might be. As demonstrated by the normal somatosensory-evoked potential findings and the contralateral fMRI activation during passive movement of the right hand in our patient, one candidate structure would be preserved somatosensory projections. Such preserved somatosensory projections have indeed been documented in several patients with early unilateral white matter lesions.¹⁷ Since all these patients suffered from marked hemiparesis, this first possibility is unlikely to be the sole explanation. A second possibility is preserved contralateral corticospinal projections to more proximal muscles of the right upper extremity. In our transcranial magnetic stimulation investigation, we only looked at the ADM, an intrinsic hand muscle; thus, we have no information on any other muscles. This second possibility is supported by the results of tractography in our patient, demonstrating that the corticospinal tract in the lesioned left hemisphere was smaller, but not absent. A third explanation, and in our view the most likely, would be an unusually good preservation of non-primary, or ‘extra-pyramidal’, motor projections from the lesioned hemisphere to the paretic hand.

This third hypothesis is nicely corroborated by the MRI findings of the pons in the patient: despite a clear asymmetry in the corticospinal projections, no overall pontine asymmetry was observed, demonstrating a rather selective damage to some corticospinal projections (Fig. S1) as opposed to the typical imaging appearance of the pons in congenital hemiparesis, where most patients show a marked asymmetry.¹⁸ If this third hypothesis were correct, this would mean that the hand motor impairment in patients with congenital hemiparesis and ipsilateral corticospinal projections is also a consequence of a concomitant lesion of these extra-pyramidal projections, which leads to a motor impairment *despite* the presence of ipsilateral corticospinal projections.

Therefore, albeit an exception, this report gives rise to fascinating hypotheses on factors affecting hand function recovery and on less explored resources for brain plasticity outside the corticospinal system.

ACKNOWLEDGEMENTS

We thank the child who took part in this study and his family. This project was supported by grants from the Mariani Foundation of Milan (grant R 11-86). The authors have stated that they had no interests that might be perceived as posing a conflict or bias.

SUPPORTING INFORMATION

The following additional material may be found online:

Video S1: The child performing finger tapping test, finger to thumb test and rapid and closing of the hands.

Figure S1: (a) Axial and sagittal T1 at the level of the ventricles, showing an irregular enlargement of the left lateral ventricle, most pronounced in its frontal part; (b) Axial coloured track density image at the level of the pons.

Figure S2: Motor-evoked potentials from left (on the left) and right (on the right) hemispheres.

Figure S3: Diffusion tractography. Descending (red) and ascending (green) tracts were defined as those streamlines reaching the pre- and postcentral gyri through the posterior limb of the internal capsule (PLIC) or the thalamus respectively.

REFERENCES

1. Cincotta M, Ziemann U. Neurophysiology of unimanual motor control and mirror movements. *Clin Neurophysiol* 2008; **119**: 744–62.
2. Vulliemmoz S, Raineteau O, Jabaudon D. Reaching beyond the midline: why are human brains cross wired? *Lancet Neurol* 2005; **4**: 87–99.
3. Eyre JA, Miller S, Clowry GJ, Conway EA, Watts C. Functional corticospinal projections are established prenatally in the human foetus permitting involvement in the development of spinal motor centres. *Brain* 2000; **123**: 51–64.
4. Staudt M, Grodd W, Gerloff C, et al. Two types of ipsilateral reorganization in congenital hemiparesis: a TMS and fMRI study. *Brain* 2002; **125**: 2222–37.
5. Staudt M, Gerloff C, Grodd W, et al. Reorganization in congenital hemiparesis acquired at different gestational ages. *Ann Neurol* 2004; **56**: 854–63.
6. Woods BT, Teuber HL. Mirror movements after childhood hemiparesis. *Neurology* 1978; **28**: 1152–7.
7. Johnson LM, Randall MJ, Reddihough DS, et al. Development of a clinical assessment of quality of movement for unilateral upper-limb function. *Dev Med Child Neurol* 1994; **36**: 965–73.
8. Watter P. Movement Assessment Battery for Children (Movement ABC). *Aust J Physiother* 2006; **52**: 68.
9. Krumlind-Sundholm L, Eliasson AC. Development of the assisting hand assessment: a Rasch-built measure intended for children with unilateral upper limb impairment. *Scand J Occup Ther* 2003; **10**: 16–26.
10. Méneret A, Depienne C, Riant F, et al. Congenital mirror movements: mutational analysis of RAD51 and DCC in 26 cases. *Neurology* 2014; **82**: 1999–2002.
11. Borghetti D, Sartucci F, Petacchi E, et al. Transcranial magnetic stimulation mapping: a model based on spline interpolation. *Brain Res Bull* 2008; **77**: 143–8.
12. Guzzetta A, Staudt M, Petacchi E, et al. Brain representation of active and passive hand movements in children. *Pediatr Res* 2007; **61**: 485–90.
13. Guzzetta A, Pecini C, Biagi L, et al. Language organisation in left perinatal stroke. *Neuropediatrics* 2008; **39**: 157–63.
14. Rose S, Guzzetta A, Pannek K, Boyd R. MRI structural connectivity, disruption of primary sensorimotor pathways, and hand function in cerebral palsy. *Brain Connect* 2011; **1**: 309–16.
15. Staudt M, Lidzba K, Grodd W, et al. Right-hemispheric organization of language following early left-sided brain lesions: functional MRI topography. *NeuroImage* 2002; **16**: 954–67.
16. Adler C, Berweck S, Lidzba K, Becher T, Staudt M. Mirror movements in unilateral spastic cerebral palsy: specific negative impact on bimanual activities of daily living. *Eur J Paediatr Neurol* 2015 Mar 24. pii: S1090-3798(15)00067-7.
17. Staudt M, Braun C, Gerloff C, et al. Developing somatosensory projections bypass periventricular brain lesions. *Neurology* 2006; **67**: 522–5.
18. Staudt M, Niemann G, Grodd W, Krägeloh-Mann I. The pyramidal tract in congenital hemiparesis: relationship between morphology and function in periventricular lesions. *Neuropediatrics* 2000; **31**: 257–64.