

Regional cerebral blood flow by SPECT imaging in Sturge-Weber disease: an aid for diagnosis

C CHIRON,* C CRAYNAUD,† N TZOURIO,† C DIEBLER,‡ O DULAC,*
M ZILBOVICIUS,† A SYROTA†

From the Clinique de Pédiatrie et de Puériculture, Hôpital Saint Vincent de Paul, Paris, Service Hospitalier Frédéric Joliot, Orsay,† Centre Médico-Chirurgical Foch, Suresnes, France‡*

SUMMARY Regional cerebral blood flow (rCBF) was studied using SPECT (single photon emission computed tomography) with ¹³³Xenon in 13 patients with confirmed Sturge-Weber disease, aged 9 months to 18 years. CT scan, performed at the same time, showed evident cerebral angioma in 10 but not in three. A marked hypoperfused area was found in all patients, ranging from -32% to -72% and of the same location as the CT signs. The hypoperfusion seems to result from post ictal phenomenon as well as from chronic ischaemia. SPECT imaging is therefore a sensitive method for visualising intracranial angioma in Sturge-Weber disease and it provides an aid for diagnosis when a CT scan is not reliable.

Sturge-Weber (SW) angiomatosis is a non-inherited neurocutaneous syndrome characterised by a congenital trigeminal port-wine stain and a piamater angioma.¹ This intracranial angioma, venous and purely meningeal,^{2,3} is embryologically derived from the neural crest. Along with the angioma, cerebral lesions, which are ischaemic in nature, are seen in the cortex underlying the angioma.⁴

The diagnosis of SW disease is based on the association of three characteristics - cutaneous, neurological and radiological. Among the neurological features are epilepsy, hemiplegia and mental retardation. CT is currently the most reliable technique used to confirm the existence of intracranial angioma by visualising calcifications, focal cortical atrophy and opacification after contrast enhancement.⁵ Diagnosis is easy in severe cases of this disease since all clinical and radiological characteristics are present, but it is difficult in milder cases where one or more of these features is absent, such as an absence of cutaneous angioma,⁶ a delayed onset of neurological signs⁷ or an atypical appearance of the angioma on the CT, on which calcifications, focal atrophy or angioma contrast may be absent, particularly in young children.⁸ Progressive aggravation of the neurological condition, for which seizures seem

to be responsible, occurs in SW disease.⁴ Therefore, the diagnosis of this disease, that is, the presence of an intracranial angioma, needs to be determined.

Hypometabolism but also hypermetabolism have recently been reported using positron emission tomography (PET).⁹ We studied regional cerebral blood flow (rCBF) in children with confirmed SW disease to determine whether a characteristic rCBF pattern exists and to test the diagnostic value of this technique with that of CT.

Patients

We studied thirteen patients, eight boys and five girls, aged between 9 months and 18 years (mean 6 years). The examinations were performed with the informed consent of the children's parents.

All 13 were diagnosed as having SW disease. Diagnostic criteria are summarised in table 1. Facial angioma was found in all patients except one (number 5). In this case, the neurological and radiological characteristics were those of Sturge-Weber disease; arteriography was normal, excluding other types of vascular malformation. Two patients did not have seizures before SPECT imaging (numbers 8, 9); one of these showed neither neurological disorders nor mental retardation (number 8) but there was no doubt about cutaneous and cerebral angioma. All patients showed asymmetrical electroencephalographic features, including depressed background activity on the side of the angioma (fig 1b), interictal focal epileptiform activity (fig 4b), or focal epileptic discharges (fig 1c). In ten patients, the CT revealed a typical pattern of intracranial angioma; for the three others, the CT disclosed only focal atrophy (number 9), only contrast enhancement (number 7), or no abnormality (number 12).

Correspondence to: Dr Chiron, Clinique de Pédiatrie et de Puériculture, Inserm U29, Hôpital Saint Vincent de Paul, 74 Avenue Denfert Rochereau, 75674 Paris, Cedex 14, France.

Received 3 January 1989 and in revised form 10 May 1989.
Accepted 14 June 1989

Table 1 Patient data

Number of patients	Sex	Age at SPECT	Cutaneous angioma	Seizures (First-Last)	EEG data	Neurological examination	Mental development	CT signs (Age)	ACD
1	F	10 y	Bilateral	6 m-10 y	Right hemispheric depression Bilateral discharges	Left hemiplegia	Severely delayed	C + A, CE, (10 y)	PB
2	F	14 y	Bilateral	21 m-13 y 6 m	Right hemispheric depression	Left hemiparesis	Severely delayed	C, A, CE, (14 y)	CBZ, CLB
3	F	7 y	Bilateral	8 m-6 y 6 m	Right hemispheric depression	Tetraplegia	Severely delayed	C, A, CE, (7 y)	CBZ, CZP
4	M	6 y	Right	6 m-4 y 10 m	Right hemispheric slow waves	Normal	Mildly delayed	C, A, CE, (6 y)	CBZ, CLB
5	M	18 y	No angioma	11 m-17 y	Left posterior slow waves	Right hemiparesis	Mildly delayed	C, A, (18 y)	PB, CBZ
6	F	7 y 6 m	Right	31 m-7 y 6 m	Right hemispheric slow waves	Normal	Mildly delayed	A, CE, (5 y 4 m)	CBZ, CZP, PG
7	M	1 y 5 m	Bilateral	13 m-2 y	Left posterior spikes Right posterior slow waves	Normal	Mildly delayed	CE, (2 y)	PB, PHT
8	M	1 y	Right	No seizure	Right anterior slow waves	Normal	Normal	A, CE, (1 y)	PB
9	M	8 y	Right	No seizure	Right slow waves	Normal	Mildly delayed	A (8 y)	PB
10	M	10 m	Left	6 m-9 m	Left posterior slow waves	Right hemiparesis	Mildly delayed	A, CE, (10 m)	PB, CBZ
11	M	11 m	Bilateral	4 m-8 m	Left hemispheric depression	Right hemiplegia	Mildly delayed	C, CE, (11 m)	CBZ, CLB
12	F	9 m	Left	9 m-9 m	Left hemispheric depression	Right hemiparesis	Normal	None (9 m)	CBZ, CLB
13	M	24	Left	2 m-24 m	Left hemispheric depression Left temporal discharges	Right hemiplegia	Mildly delayed	A, C, CE, (24 m)	PB, CBZ

1, male; F, female; m, month; y, year; A, atrophy; CE, contrast enhancement; C, calcifications; ACD, anticonvulsant drug; PB, phenobarbital; CBZ, carbamazepine; PG, progabide; CZP, clonazepam; CLB, clobazam; PHT, phenytoin.

Patient number 7 had a special history. Anticonvulsant treatment had been given since birth for suspected SW disease because of facial angioma and to prevent seizures. Two CTs given when the patient was aged six months and one year were considered normal. Treatment was therefore stopped after the second CT. One month later, partial motor status occurred, confirming the diagnosis of SW disease. One year later, although epilepsy was severe, the patient showed no permanent focal motor deficit and a CT revealed only moderate abnormalities (table 1).

Methods

The rCBF was measured by SPECT with a Tomomatic 564 using 133 Xenon, and injected intravenously in doses ranging from 1.5 to 2.5 mCi/Kg. Data collection lasted 4.5 minutes. Results were obtained on five 20 mm-thick slices, parallel to the orbito-meatal (OM) line, at levels OM + 20, OM + 40, OM + 60, OM + 80 mm and OM + 100 mm. The radiation dose to the target organ, the lung, was 250 to 350 mrad. To prevent the head from moving during acquisition, children under 6 years old received 4 mg/Kg of rectal pentobarbital and 0.5 mg/Kg of intramuscular droperidol. All patients were receiving anticonvulsant drugs (table 1) and none of the patients experienced seizures on the day of the study.

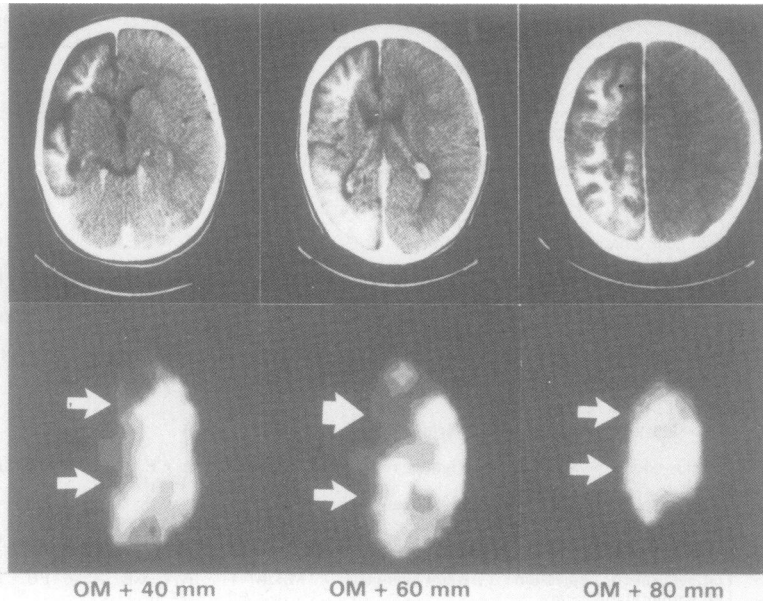
The rCBF was measured on 20 cortical regions of interest (ROI) per slice. The ROI were circular and ranged from 1.5 to 2.5 cm² in size. For each patient, the mean rCBF or "global rCBF", was calculated as the mean half-slice rCBF for slices OM + 40, + 60, and + 80, on the undamaged or the less damaged side. ROI rCBF values were expressed as a percentage of the individual mean rCBF and also as a percentage of the contralateral value in the symmetrical ROI.

ROI rCBF was classified as "decreased" when the difference with the contralateral value was greater than 20%.

A CT, with contrast injection, was performed on each patient, using the same head position as that required for the SPECT study. Nine mm-thick slices were obtained at the same levels OM + 20, + 40, + 60, + 80, and + 100, as in the SPECT study. Both studies were performed at the same time in all except two patients for whom there was a time interval of 7 and 26 months between the CT and the SPECT (numbers 6 and 7 respectively); no neurological changes were observed during this time interval. The ROI employed on SPECT images were traced on the CT images after the size of the ROI was homothetically reproduced on the CT image. Three types of abnormalities were studied on the CT scan: calcifications, atrophy and contrast enhancement after injection.

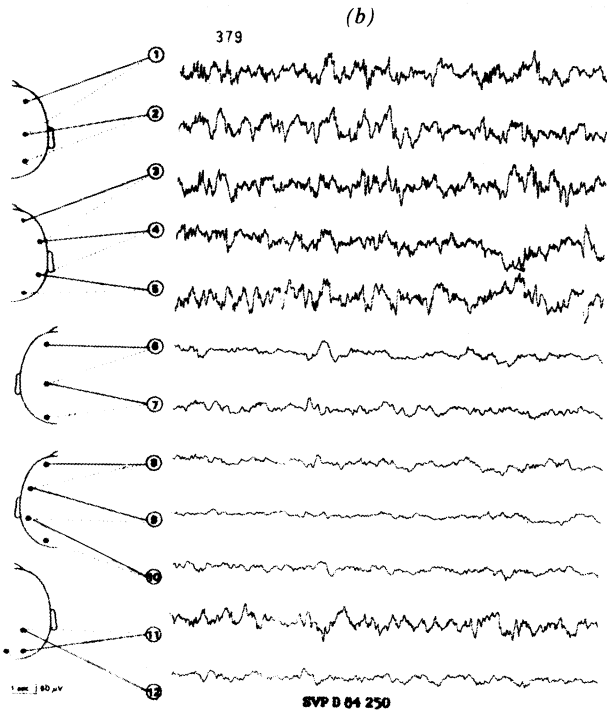
Results

In six patients (numbers 1-4, 11, 13), the CT abnormalities were large since contrast enhancement and calcifications covered an entire hemisphere. In all six patients, an rCBF decrease was observed in a large cortical and subcortical area of the same hemisphere. In the cortex, the hypoperfused area was approximately of the same size as the CT abnormal area (fig 1a). In the subcortical regions, the size of the hypoperfused area was easily measured, but could not be compared with that of the CT abnormal area which was poorly defined. The intensity of the rCBF decrease was considerable, with maximal value ranging from 32% to 72% depending on the patients.

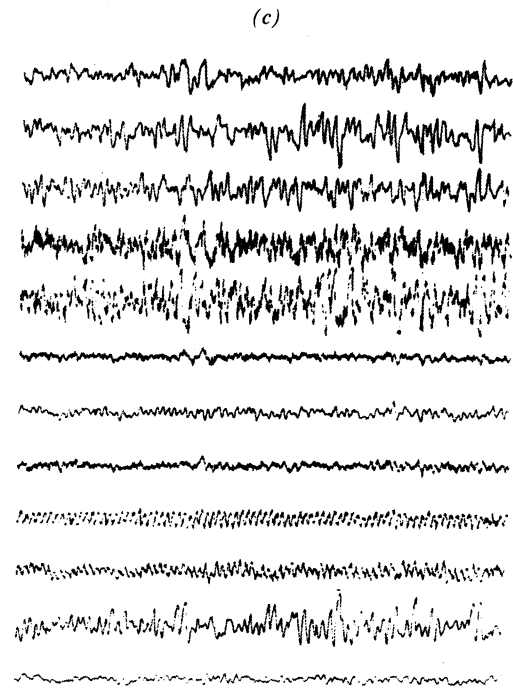


(a)

Fig 1 Patient number 13. (a) large abnormal CT area involving the whole left hemisphere (top) with a hypoperfused area (bottom) of approximately the same size. (b) Depressed interictal background activity on the whole left hemisphere. (c) Left temporal epileptic discharge at the same age.



(b)



(c)

Table 2 Comparative data on SPECT and CT scan

Number of patients	Location of CT abnormalities	Location of SPECT hypoperfusion	Number of pathological cortical roi		Minimal rCBF observed (symmetrical rCBF) ml/100 g/mn	Mean rCBF ml/100 g/mn	Maximal rCBF decrease*
			On CT	On SPECT			
1	R diffuse	R diffuse	30	30	21 (58)	52	-59%
2	Bilateral atrophy	L central	41	41	31 (43)	46	-32%
	R diffuse	R diffuse					
3	L posterior	L posterior	30	30	25 (37)	47	-45%
	R diffuse	R diffuse					
4	Bilateral atrophy	L central	30	28	29 (85)	73	-60%
	R diffuse	R diffuse					
5	L posterior	L posterior	8	10	31 (70)	62	-50%
6	R posterior	R posterior	10	11	35 (57)	53	-33%
7	L posterior	L posterior	6	11	39 (71)	73	-45%
8	R anterior	R anterior	5	3	52 (63)	76	-32%
9	R posterior	R posterior	2	5	42 (54)	67	-37%
10	L posterior	L posterior	6	10	36 (64)	63	-43%
11	L diffuse	L diffuse	30	30	44 (85)	72	-39%
12	R posterior	R posterior	0	20	36 (80)	67	-46%
13	L diffuse	L diffuse	30	30	27 (95)	80	-72%

*Expressed in percentage of mean rCBF.
R, right; L, left; ROI, region of interest.

In six patients (numbers 5–10), the CT abnormalities covered a small area. In all six, an rCBF decrease was found in an area corresponding to the CT scan abnormal area. In the cortical region, the size of

the hypoperfused area was similar to that of the CT abnormal image in three patients (fig 2) and slightly larger in the other three (numbers 7, 9, 10) (figs 3, 4). In these six patients, the rCBF decrease was also marked,

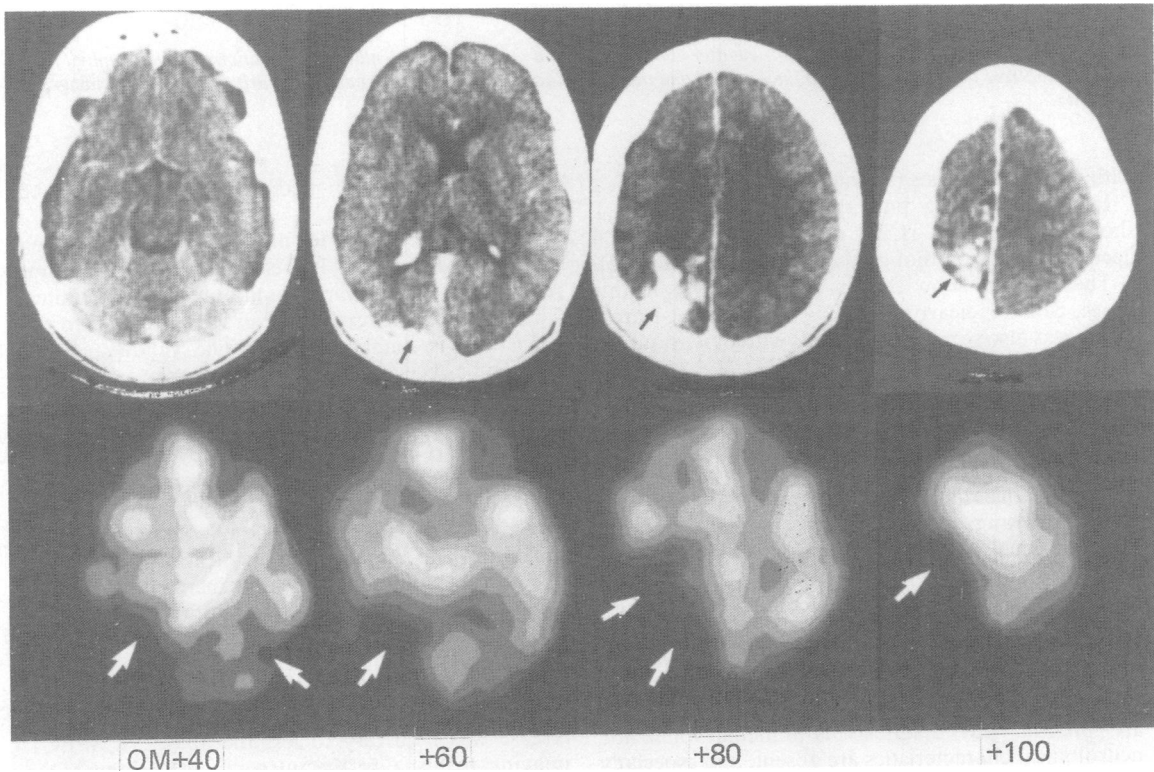


Fig 2 Patient number 5. Small abnormal CT area (top) with a corresponding hypoperfused area on SPECT (bottom).

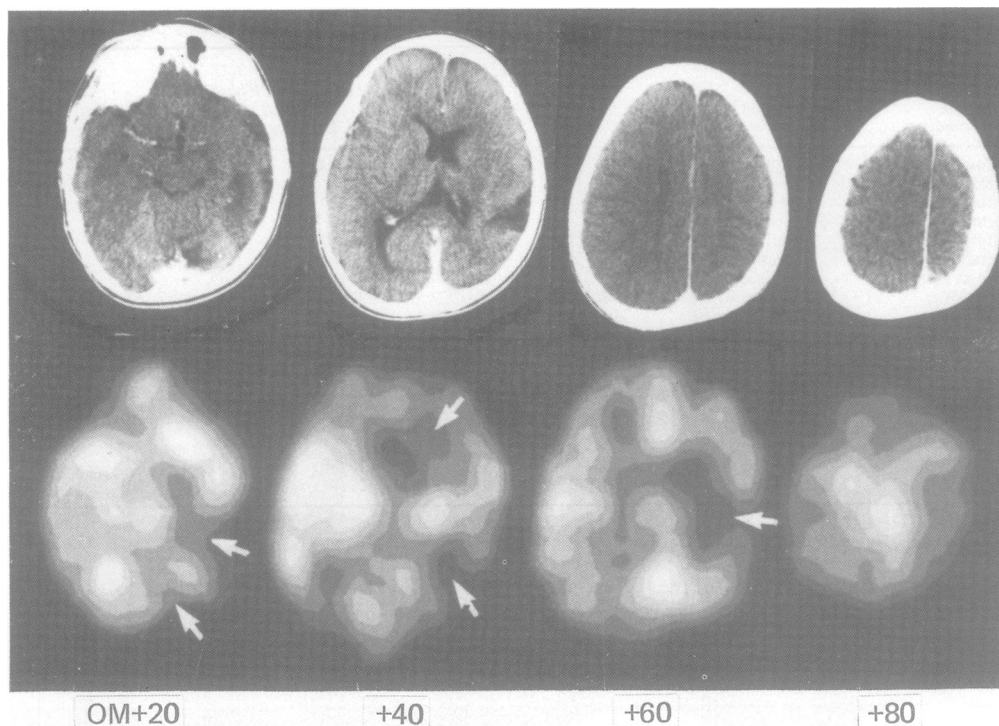


Fig 3 Patient number 9. CT scan performed after contrast injection (top) shows no enhancement but only focal atrophy (the posterior contrast area corresponds to the superior longitudinal sinus). The hypoperfused area is clearly seen on rCBF images (bottom).

with individual values ranging from 32% to 45%.

In the remaining patient (number 12), SPECT showed a localised rCBF decrease, with maximal decrease of 50%, although the CT was normal (fig 5).

These results show that in all the patients in this series, SPECT clearly defined a hypoperfused area, which was also seen in the patients with or without the typical appearance of angioma on CT.

Discussion

The diagnosis of Sturge-Weber disease is based on the association of clinical and radiological characteristics. Cutaneous angioma is usually present at birth. Epilepsy usually appears in the first years of life and hemiplegia follows the first prolonged seizures although some patients may remain seizure free. Cerebral angioma is constant but radiological characteristics may be delayed, or reduced to non-specific features, or may even be occasionally absent. Sturge-Weber disease is easily diagnosed when all the features are present, but diagnosis is difficult when the neurological characteristics are absent, and especially when a CT provided no additional information. An

additional diagnostic method would therefore be useful.

The method used to measure rCBF has been previously described.¹⁰ It is easy to perform, does not require any blood samples, and only takes 5 minutes. The SPECT system used is especially adapted to the brain and is highly sensitive. The validity of this method has been studied for the cortex by comparing rCBF values in the same patients with those obtained by SPECT and PET using continuous inhalation of $C^{15}O_2$. The rCBF values obtained by both methods were significantly correlated.¹¹ Adapting the SPECT technique for children required two modifications: intravenous (IV) injection of the $^{133}\text{Xenon}$ instead of inhalation and the use of premedication.¹² Using the IV injection method, rCBF values increased by a mean of 10%, probably due to the shape of the Xenon input curve.¹³ The premedication used (pentobarbital and droperidol) did not cause any significant change in rCBF in our research.

A study of patients with confirmed Sturge-Weber disease was necessary to test the ability of SPECT imaging to visualise the intracranial angioma. Our results show that all patients had a marked hypo-

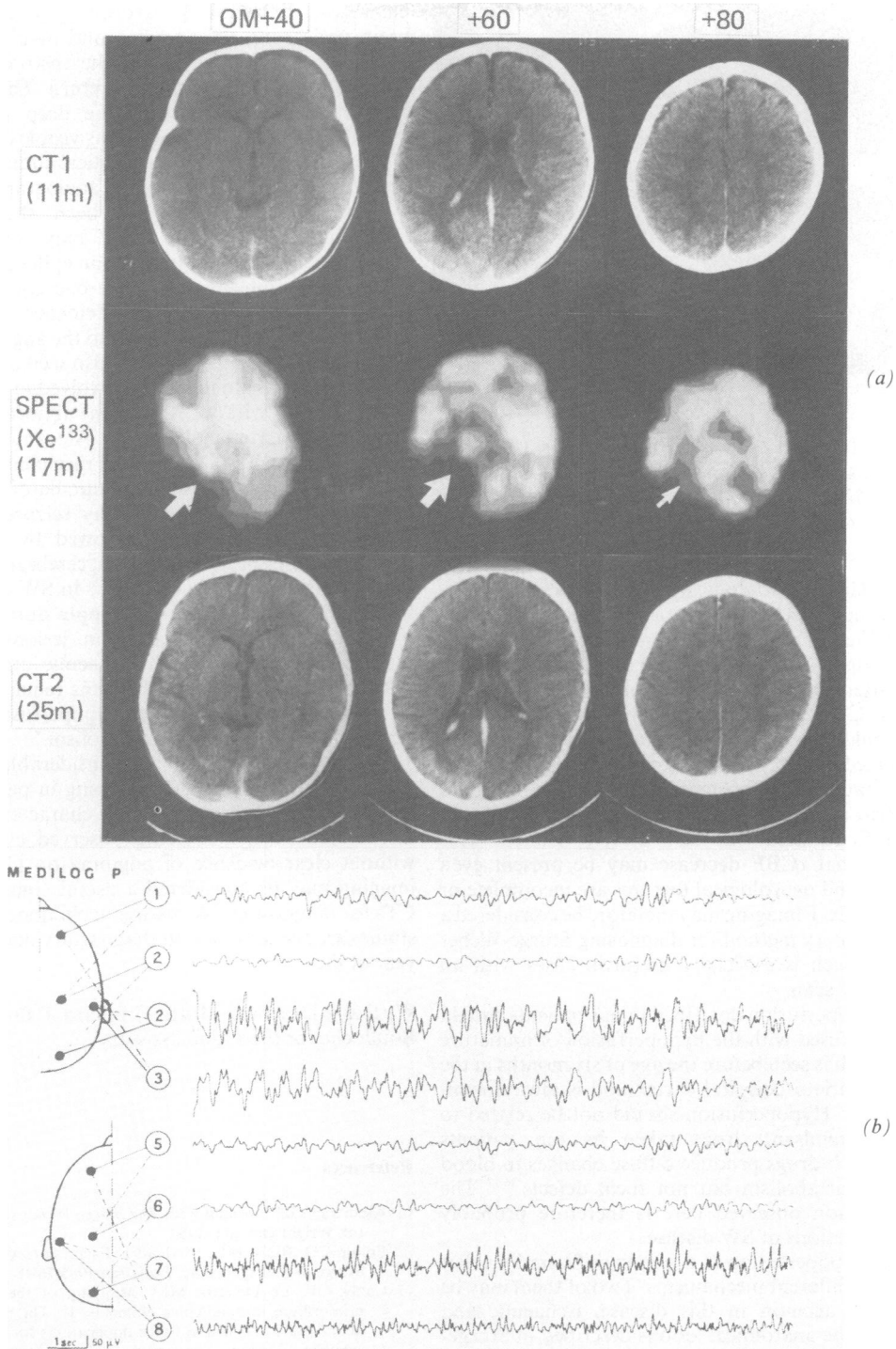


Fig 4 Patient number 7. (a) CT scan after contrast injection at one year is considered normal (top). SPECT imaging at one year five months shows a well defined posterior hypoperfused area (middle). At two years, CT scan after injection only shows a discrete enhancement in the posterior cortex and a hypertrophy of the left choroid plexus (bottom). (b) Left temporal focus of spikes and right temporal focus of slow waves on the interictal EEG recorded at one year six months.

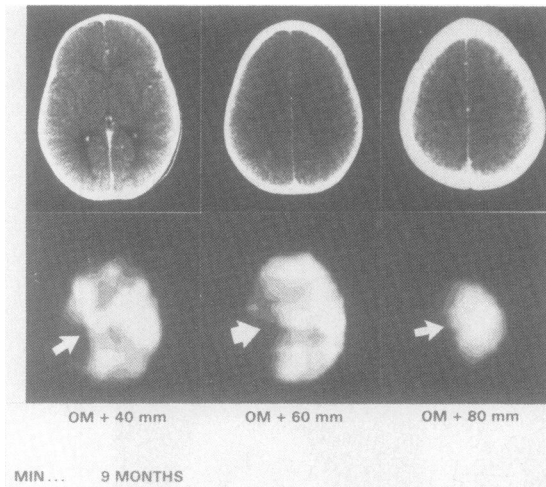


Fig 5 Patient number 12. CT scan after injection is normal (top) but SPECT shows at the same age a left diffuse hypoperfusion (bottom).

perfusion in the pathological cerebral regions, suggesting that such hypoperfusion is a reliable sign of Sturge-Weber disease. In our series, the CT scan pattern was incomplete in some patients and diagnosis was established after the neurological features appeared: in one of them CT scan was normal, in another it showed such mild abnormalities that they had been overlooked on first examination. In three patients, the clinical pattern was incomplete. Two of the three had never had any seizures. However, in these patients, a hypoperfused area was also clearly defined. This indicates that rCBF decrease may be present even when CT and neurological features are incomplete or absent. SPECT imaging may therefore be considered a complementary method for diagnosing Sturge-Weber disease, which is especially useful in cases with an atypical CT scan.

The hypoperfusion described in our patients should not be confused with the hypoperfusion of immature areas, which is seen before the age of six months in the temporo-parieto-occipital cortex and is always symmetrical.^{14,15} Hypoperfusion should not be related to the anticonvulsant drugs taken by our patients because such drugs produce diffuse changes in blood flow and metabolism but not focal defects.^{16,17} The hypoperfusion observed here is therefore probably due to the lesions of SW disease.

Focal hypoperfusion is a non-specific finding that can reflect different mechanisms. Two of them may be taken into account in this disease, ischaemic and epileptic. The anatomical lesions described in Sturge-Weber are mainly angioma and ischaemic lesions.^{4,18,19} The angioma affects the superficial areas because it is

meningeal. Ischaemia progressively develops in the brain underlying the angioma and involves cortical and subcortical regions, due to the obstruction by the angioma of the normal venous return. This produces an abnormal drainage into the deep plexus and hypertrophy of the choroid plexus visible on CT scan. Stasis and slowing in venous cortical circulation have been demonstrated by dynamic angiography,^{20,21} and hypoxia, preoperatively, has been shown.²² The ischaemic mechanisms alone may explain the hypoperfusion seen in our two non epileptic patients.

Hypoperfusion may also be a consequence of the seizures in the post-ictal period. Evidence of consistent presence of epileptic foci related to the angioma is well known in SW disease²³ and was also seen in our series. This mechanism alone may be involved in our patient with seizures without CT scan abnormalities, as described in partial epilepsy.^{24,25} Alexander suggests that both ischaemic and epileptic mechanisms may be involved together.⁴ The complex circulatory condition in SW disease may explain why seizures are particularly severe and often followed by permanent hemiplegia. In normal conditions, cerebral blood flow locally increases during seizures.²⁶ In SW disease, the insufficient increase in blood supply during seizures may exacerbate ischaemic brain lesions. But the respective responsibility of ischaemic and epileptic phenomena in lesional mechanisms remains unclear, as well as the relation between hypoperfusion and the reported abnormalities on metabolism.⁹

Our results show that the considerable hypoperfusion observed by SPECT imaging in patients with Sturge-Weber disease is a reliable characteristic of the disease. Since it is consistently observed, even in cases without clear evidence of angioma on CT, SPECT imaging may be considered a useful complement to CTs for diagnosing SW disease in childhood. Further studies are needed to test its diagnostic value in the first year of life.

We thank Doctors J Motte, C Billard, P Pineau and C Bouloche for their kind assistance.

References

- Alexander GL, Norman RM. *The Sturge-Weber syndrome*. Bristol: Wright and Son, 1960.
- Enjolras O, Riche MC, Merland J. Facial port-wine stains and Sturge-Weber syndrome. *Pediatrics* 1985;76:48-51.
- Couly GF, Le Douarin MM. Mapping of the early neural primordium in quail-chick chimeras. II. The prosencephalic neural plate and neural folds: implications for the genesis of cephalic human congenital abnormalities. *Dev Biol* 1987;120:198-214.
- Alexander GL. Sturge-Weber syndrome. In: Vinken PJ, Bruyn

- GW, eds. *Handb Clin Neurol*. Amsterdam: North Holland Publishing, 1972;14:223-40.
- 5 Welch K, Naheedy MH, Abrams IF, Strand RD. Computed Tomography of Sturge-Weber Syndrome in Infants. *J Comput Assist Tomogr* 1980;4:33-6.
- 6 Gorman RJ, Snead OC. Sturge-Weber syndrome without port-wine nevus. *Pediatrics* 1977;60:785.
- 7 Gilly R, Lapras C, Tommasi M, Revol M, Challamel MJ, Clavel D, Manuelle JC. Maladie de Sturge-Weber-Krabbe. *Pediatric* 1977;1:45-64.
- 8 Diebler C, Dulac O. *Pediatric Neurology and Neuroradiology*. Berlin: Springer Verlag, 1987:99-101.
- 9 Chugani HT, Mazziotta JC, Phelps ME. Sturge-Weber syndrome: a study of cerebral glucose utilization with positron emission tomography. *J Pediatr* 1989;114:244-53.
- 10 Lassen NA. Cerebral blood flow tomography with Xenon-133. *Semin Nucl Med* 1985;15:347-56.
- 11 Raynaud C, Mazoyer B, Soucy JP, et al. Regional cerebral blood flow (rCBF) measured by SPECT with 133-Xenon: validation using a PET/SPECT comparison. *Eur J Nucl Med* 1988;14:308.
- 12 Dulac O, Raynaud C, Chiron C, Plouin P, Syrota A, Arthuis M. Etude du débit sanguin cérébral dans le syndrome de West idiopathique: corrélation avec les données électroencéphalographiques. *Rev EEG Neurophysiol clin* 1987;17:169-82.
- 13 Mazoyer BM, Raynaud C, Tzourio N, et al. Error analysis of regional cerebral blood flow (rCBF) measured in children by SPECT with 133-Xe. *J Nucl Med* 1988;29:918.
- 14 Tzourio N, Chiron C, Raynaud C, Dulac O, Mazoyer B, Bourguignon M, Syrota A. Cerebral maturation during the first 20 months of life studied with the regional cerebral blood flow measurements using SPECT. *J Nucl Med* 1988;29:743.
- 15 Chugani HT, Phelps ME, Mazziotta JC. Positron emission tomography study of human brain functional development. *Ann Neurol* 1987;22:487-97.
- 16 Theodore WH, Dichirio G, Margolin R, Porter RJ, Brooks RA. Barbiturates depress human cerebral glucose metabolism. *Neurology* 1986;36:60-4.
- 17 Theodore WH, Bairamina D, Newmark ME, et al. Effect of phenytoin on human cerebral glucose metabolism. *J Cereb Blood Flow Metab* 1986;6:615-320.
- 18 Greenfields JG. *Neuropathology*. Edinburgh: Edward Arnold Publisher, 1976:417-20.
- 19 Norman MG, Schoene WC. Ultrastructure of Sturge-Weber disease. *Acta Neuropathol* 1977;37:199-205.
- 20 Benton JR, Wilson GH, Newton TH. Cerebral venous drainage pattern of the Sturge-Weber syndrome. *Neuroradiology* 1971;101:111-8.
- 21 Probst FP. Vascular morphology and angiographic flow patterns in Sturge-Weber angiomas: facts, thoughts and suggestions. *Neuroradiology* 1980;20:73-8.
- 22 Alexander GL, Cooper R, Crow HJ. EEG, Ecg and oxygen availability (AO2) in the cortex of a case of Sturge-Weber syndrome. *Electroencephalogr Clin Neurophysiol* 1972;14:284.
- 23 Brenner RP, Sharbrough FW. Electroencephalographic evaluation in Sturge-Weber syndrome. *Neurology* 1976;26:629-32.
- 24 Bonte FJ, Devous MD, Stokely EM, Homan RW. Single-photon tomographic determination of regional cerebral blood flow in epilepsy. *AJNR* 1983;4:544-6.
- 25 Engel J, Brown WJ, Kuhl E, Phelps ME, Mazziotta JC, Crandall PH. Pathological findings underlying focal temporal lobe hypometabolism in partial epilepsy. *Ann Neurol* 1982;12: 518-28.
- 26 Franck G, Sadzot B, Salmon E, et al. Regional cerebral blood flow and metabolic rates in human focal epilepsy and status epilepticus. In: Delgado-Escueta AV, Ward A, Woodbury DM, Porter RJ, eds. *Advances in Neurology*. New York: Raven Press, 1986.