

CASE REPORT

Mycobacterial spindle cell pseudotumour of the brain in a patient with sarcoidosis

Iyad Ismail,¹ Martyn Carey,² Simon Trotter,³ Heinke Kunst⁴¹Department of Respiratory Medicine, Heart of England NHS Foundation Trust, Sutton Coldfield, West Midlands, UK²Department of Pathology, University Hospitals Birmingham NHS Foundation Trust, Birmingham, West Midlands, UK³Department of Pathology, Heart of England NHS Foundation Trust, Birmingham, West Midlands, UK⁴Department of Respiratory Medicine, Queen Mary University Hospital, London, London, UK**Correspondence to**Dr Iyad Ismail,
iyad75@hotmail.co.uk

Accepted 9 June 2015

SUMMARY

Mycobacterial spindle cell pseudotumours (MSP) are benign lesions characterised by local proliferation of spindle-shaped histiocytes caused by mycobacterial infections. Cerebral MSP due to *Mycobacterium avium intracellulare* (MAI) infection is rare, and is often misdiagnosed clinically and radiologically as a brain tumour. We present a case with underlying sarcoidosis and known pulmonary MAI infection presenting with partial seizures and headaches. Imaging of the brain revealed a solitary extra axial tumour within the right temporal area. Biopsy of the tumour showed evidence of MPS due to MAI infection. Prolonged treatment with antituberculous therapy showed complete resolution of the cerebral lesion.

BACKGROUND

Mycobacterial spindle cell pseudotumours (MSP) are rare benign lesions characterised by local proliferation of spindle-shaped histiocytes containing acid fast bacilli.¹ MSP can be caused by tuberculous as well as non-tuberculous mycobacteria (NTM). Spindle cell pseudotumours due to *Mycobacterium avium intracellulare* (MAI) infection usually present with pulmonary disease in immunosuppressed patients,² particularly those with AIDS. Other organs affected include the lymph nodes,^{1 3–5} skin,⁶ spleen⁷ and bone marrow.⁸ We present a case of cerebral MSP secondary to MAI infection in an HIV negative patient presenting radiologically as a solitary right extra-axial temporal tumour. Spindle cell pseudotumours are often confused with malignant lesions and, usually, only biopsy of these lesions confirms the diagnosis.

CASE PRESENTATION

A 69-year-old Caucasian man, a retired maintenance engineer, was referred to our respiratory clinic in 2009 for treatment as his sputum was repeatedly culture positive for MAI. He had a persistent cough and was reporting of dyspnoea and significant fatigue. He was originally diagnosed to have sarcoidosis in 1983, based on radiology appearance of bilateral hilar lymphadenopathy and a transbronchial biopsy that showed granulomatous changes. He was diagnosed to have asthma as a child and used combination inhalers of fluticasone and salmeterol. In 2005, he was found to have bronchiectasis, and 2 years later presented with two episodes of haemoptysis, which were managed conservatively with antibiotics after bronchoscopy failed to show a bleeding source. He required treatment for his sarcoidosis in 2007, and was maintained on a dose

of 5–15 mg of prednisolone for 2 years until his presentation to our clinic. CT of the chest was consistent with features of chronic sarcoidosis and widespread bronchiectasis. His lymphocyte count was persistently low ($0.43\text{--}0.46 \times 10^9/\text{L}$, normal $1.50\text{--}4.00 \times 10^9/\text{L}$). HIV test was negative and the ACE levels were normal.

In 2008, the patient presented to the neurosurgeons with a 9-month history of headaches and partial seizures. A CT and MRI of the brain scan showed a contrast enhancing solitary extra axial tumour within the right temporal area (figure 1). He underwent a craniotomy and complete macroscopic excision of the dural-based tumour. Intraoperatively, the tumour was noted to be firm, rubbery and adherent to the dura. Histologically, the tumour showed cellular nodules composed of interlacing bundles of plump spindle cells with oval or elongated nuclei, an open chromatin pattern and bipolar fibrillar cytoplasmic processes, arranged in a vague storiform pattern. Relatively uniform infiltrates of small lymphocytes and occasional neutrophils were interspersed. A few mitoses were present (figure 2). Immunostaining of the specimen showed that the spindle cells were strongly CD68 (KP-1) and vimentin positive, weakly leucocyte common antigen and smooth muscle actin positive. Stains for epithelial membrane antigen (EMA), desmin, CD1, S-100 protein, cytokeratins, glial fibrillar acidic protein (GFAP) and CD34 were all negative.

INVESTIGATIONS

The patient's initial diagnosis was of a low grade tumour (meningioma), radiologically, but since he persistently cultured MAI in his sputum, a retrospective analysis of his brain mass by electron

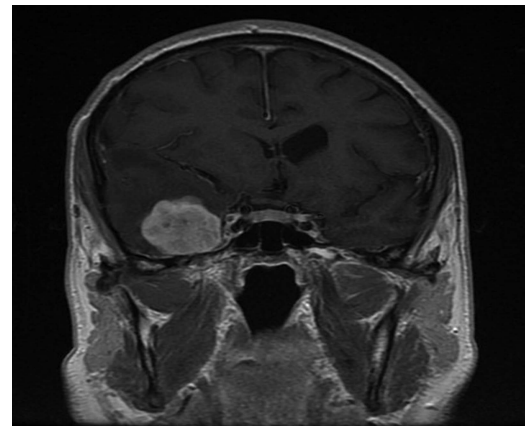


Figure 1 MRI at presentation.



To cite: Ismail I, Carey M, Trotter S, et al. *BMJ Case Rep* Published online: [please include Day Month Year] doi:10.1136/bcr-2014-206171

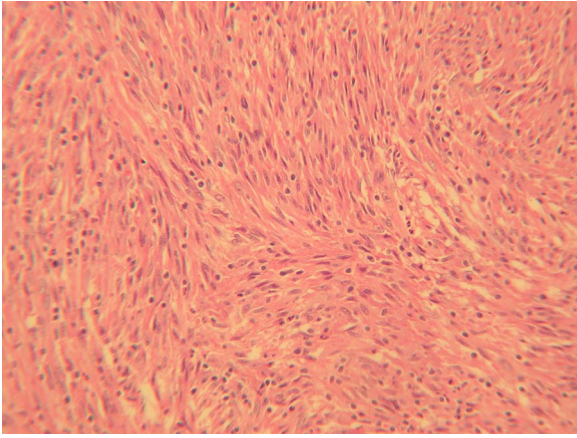


Figure 2 H&E stain shows a spindle cell lesion with a storiform pattern and scattered lymphocytes.

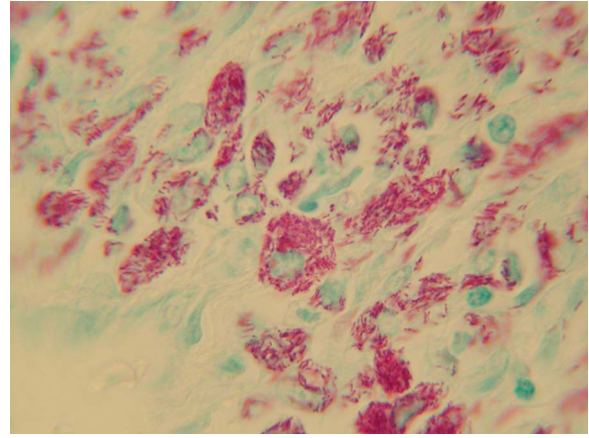


Figure 4 Numerous intracellular Ziehl-Neelsen positive bacilli.

microscopy was undertaken (figure 3), which revealed the presence of numerous intracellular bacteria. This prompted staining for organisms on light microscopy, and Ziehl-Neelsen positive intracellular bacilli were identified (figure 4). PCR of the brain biopsy was positive for *MAI*.

DIFFERENTIAL DIAGNOSIS

Other differential diagnoses for spindle cell tumours include malignant fibrous histiocytomas, sarcomas and schwannomas. More rare forms are pleomorphic spindle cell tumours including spindle carcinomas, lymphomas and melanomas, as well as pleomorphic sarcoma. Immunostaining helps to differentiate between the tumours.

TREATMENT

The patient had prolonged treatment with ethambutol, rifampicin and moxifloxacin, as his sputum showed clarithromycin

resistance.⁹ He was gradually weaned off prednisolone and, once stopped, his sputum became culture negative.

OUTCOME AND FOLLOW-UP

The patient successfully completed 2 years of treatment with the last positive culture for *MAI* 16 months before the end of treatment. Since the radiological and histological findings were initially interpreted as consistent with a low-grade meningioma, the tumour was excised. However, repeat imaging by MRI scan revealed a residual contrast enhancing nodule. Only after 2 years of antituberculous treatment was there complete resolution of the previous pseudotumour, with minimal dural enhancement.

DISCUSSION

NTM are low grade pathogens that usually affect immunodeficient patients or those with underlying lung disease. In keeping with previous reports, this patient's intracranial *MAI* infection was associated with sarcoidosis, secondary bronchiectasis and long-term use of steroids. Morrison *et al*¹⁰ described a similar case of cerebral MSP in an HIV negative patient with sarcoidosis on steroids but with an idiopathic low CD4 count. Our patient had a persistently low lymphocyte count and this may have been a risk factor for him to develop cerebral *MAI* infection through a haematogenous spread since NTM disease is known to be associated with CD4 T cell lymphopaenia.¹⁰ Interestingly, Ho *et al*¹¹ found that a subset of CD4 T-cells (CD1d-restricted natural killer cells) was significantly reduced in patients with sarcoidosis. The authors postulated that this deficiency was implicated in the pathogenesis of the disease in sarcoidosis rather than a contributing factor for acquiring relatively low-virulent organisms such as NTM. There is growing evidence that mycobacterial antigens may be implicated in the pathogenesis of sarcoidosis,¹² however, it is not clear if patients with sarcoidosis develop NTM infections due to underlying disease, associated lymphocytopenia or immunosuppressant therapy.¹³

MSP of the skin has been described with the use of prednisolone and azathioprine in a systemic lupus erythematosus patient,¹⁴ and immunosuppressive therapy in a scleroderma case, but due to *Mycobacterium chelonae*.¹⁵ An intracranial *MAI* infection presenting as a meningioma on imaging has also been previously documented.¹⁶ Other differential diagnoses for spindle cell tumours include histiocytomas, sarcomas and schwannomas. Immunostaining helps to differentiate between the tumours. Immunostaining in spindle cell meningiomas has at least focal

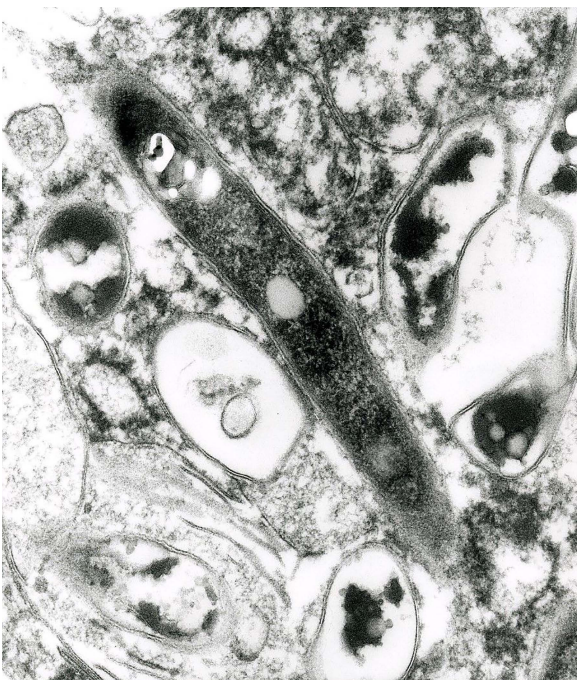

Figure 3 Electron microscopy shows intracellular bacteria.

membranous positivity for EMA, positivity for vimentin, negativity for cytokeratin and weak or negative staining for S100 protein.^{3 17} With schwannomas, S100 is strongly expressed by most cells and these can also express Vimentin and myelin basic protein.^{3 17 18} Malignant fibrous histiocytomas stain positive for vimentin, lysozyme, α -1-antitrypsin, α -1-chymotrypsin and reticulin, but negative for GFAP and S-100 protein.¹⁹

Learning points

- ▶ Spindle cell pseudotumours caused by *Mycobacterium avium intracellulare* (MAI) infection are extremely rare in immunocompetent patients.
- ▶ However, patients on steroids and chemotherapy, and those post-transplantation, are at risk of developing intracranial MAI infections.
- ▶ Spindle cell pseudotumours should be considered as a differential diagnosis in patients presenting with lesions in the central nervous system.

Contributors I wrote the case report script. HK reviewed the final format and provided feedback. MC and ST provided help preparing pathology slides and identifying the organism in question. They also gave feedback on final format.

Competing interests None declared.

Patient consent Obtained.

Provenance and peer review Not commissioned; externally peer reviewed.

REFERENCES

- 1 Logani S, Lucas DR, Cheng JD, *et al.* Spindle cell tumors associated with mycobacteria in lymph nodes of HIV-positive patients: Kaposi sarcoma with mycobacteria and mycobacterial pseudotumor. *Am J Surg Pathol* 1999;23:656–61.
- 2 Sekosan M, Cleto M, Senseng C, *et al.* Spindle cell pseudotumors in the lungs due to *Mycobacterium tuberculosis* in a transplant patient. *Am J Surg Pathol* 1994;18:1065–8.
- 3 Apel R, Samaratunga H. Lymph node pseudotumor. *Am J Surg Pathol* 1993;17:91–2.
- 4 Chen KT. Mycobacterial spindle cell pseudotumor of lymph nodes. *Am J Surg Pathol* 1992;16:276–81.
- 5 Joshi VV, Oleske JM, Saad S, *et al.* Pathology of opportunistic infections in children with acquired immune deficiency syndrome. *Pediatr Pathol* 1986;6:145–50.
- 6 Wood C, Nickoloff BJ, Todes-Taylor NR. Pseudotumor resulting from atypical mycobacterial infection: a “histoid” variety of *Mycobacterium avium-intracellulare* complex infection. *Am J Clin Pathol* 1985;83:524–7.
- 7 Suster S, Moran CA, Blanco M. Mycobacterial spindle-cell pseudotumor of the spleen. *Am J Clin Pathol* 1994;101:539–42.
- 8 Umlas J, Federman M, Crawford C, *et al.* Spindle cell pseudotumor due to *Mycobacterium avium-intracellulare* in patients with acquired immunodeficiency syndrome (AIDS). Positive staining of mycobacteria for cytoskeleton filaments. *Am J Surg Pathol* 1991;15:1181–7.
- 9 Griffith DE, Aksamit T, Brown-Elliott BA. An official ATS/IDSA statement: diagnosis, treatment, and prevention of nontuberculous mycobacterial diseases. *Am J Respir Crit Care Med* 2007;175:367–416.
- 10 Morrison A, Gyure KA, Stone J, *et al.* Mycobacterial spindle cell pseudotumor of the brain: a case report and review of the literature. *Am J Surg Pathol* 1999;23:1294–9.
- 11 Ho LP, Urban BC, Thickett DR, *et al.* Deficiency of a subset of T-cells with immunoregulatory properties in sarcoidosis. *Lancet* 2005;365:1062.
- 12 Oswald-Richter KA, Beachboard DC, Seeley EH, *et al.* Dual analysis for mycobacteria and propionibacteria in sarcoidosis BAL. *J Clin Immunol* 2012;32:1129–40.
- 13 Brownell I, Ramirez-Valle F, Sanchez M, *et al.* Evidence for mycobacteria in sarcoidosis. *Am J Respir Cell Mol Biol* 2011;45:899–905.
- 14 Shiomi T, Yamamoto T, Manabe T. Mycobacterial spindle cell pseudotumor of the skin. *J Cutan Pathol* 2007;34:346–51.
- 15 Yeh I, Evan G, Jokinen CH. Cutaneous mycobacterial spindle cell pseudotumor: a potential mimic of soft tissue neoplasms. *Am J Dermatopathol* 2011;33:e66–9.
- 16 Di Patre PL, Radziszewski W, Martin NA, *et al.* A meningioma-mimicking tumor caused by *Mycobacterium avium* complex in an immunocompromised patient. *Am J Surg Pathol* 2000;24:136–9.
- 17 Commins DL, Atkinson RD, Burnett ME. Review of meningioma histopathology. *Neurosurg Focus* 2007;23:E3.
- 18 Louis E, Cret C, Poirier J, *et al.* Intra-cerebral schwannoma simulating glioma. *J Neurooncol* 2003;64:279–82.
- 19 Tsutsumi M, Kawano T, Kawaguchi T, *et al.* Intracranial meningeal malignant fibrous histiocytoma mimicking parasagittal meningioma—case report. *Neurol Med Chir (Tokyo)* 2001;41:90–3.

Copyright 2015 BMJ Publishing Group. All rights reserved. For permission to reuse any of this content visit

<http://group.bmj.com/group/rights-licensing/permissions>.

BMJ Case Report Fellows may re-use this article for personal use and teaching without any further permission.

Become a Fellow of BMJ Case Reports today and you can:

- ▶ Submit as many cases as you like
- ▶ Enjoy fast sympathetic peer review and rapid publication of accepted articles
- ▶ Access all the published articles
- ▶ Re-use any of the published material for personal use and teaching without further permission

For information on Institutional Fellowships contact consortiasales@bmjgroup.com

Visit casereports.bmj.com for more articles like this and to become a Fellow