

## Clinical Reports

# Formed hallucination in the hemianopic field

M.T. Benson and I.G. Rennie

Department of Ophthalmology, Royal Hallamshire Hospital, Sheffield, UK.

**Summary:** We present a case in which formed hallucinations were the sole presenting feature of an occipital infarct. The hallucinations occurred in the resulting hemianopic field. The localizing value of such phenomena is discussed.

### Introduction

The term hallucination refers to the perception of sensations in the absence of any external stimulus. Visual sensations may be produced by the stimulation of any part of the visual pathway, although such sensations may be no more than flashes of light.

Formed visual hallucination in a hemianopic visual field is a well-described phenomenon, but as a presenting symptom it is rare. The significance of visual hallucination in the hemianopic field as a localizing sign is controversial.

### Case report

A 64 year old man presented to the ophthalmic department with a one-week history of formed hallucination in his right visual field. For 10 days prior to this he had experienced photopsias in the right field of vision. The patient was not aware of any visual field loss and there were no other neurological symptoms.

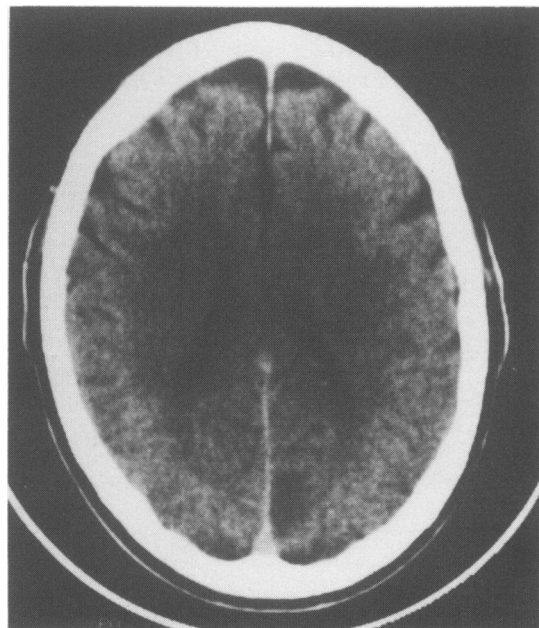
The hallucination occurred daily at various times, and lasted a few seconds at a time. It took the form of cats or small dogs. The patient recognized none of the animals as those he had seen or owned. They were of normal size and were realistic, sharp images. The hallucinations were always static and comprised a single animal looking up at the patient. The images disappeared with saccades but were unaffected by smooth pursuit movements.

The patient had had type 2B hyperlipidaemia, angina and hypertension diagnosed 15 years previously and his current treatment was diltiazam, atenolol, isosorbide mononitrate, glyceryl trinitrate and aspirin.

There was no previous ophthalmic history. His visual

acuity was 6/5 in the right, and 6/24 improving to 6/9 with a pinhole in the left. Ocular examination was unremarkable, and pupil reactions were normal. Kinetic perimetry demonstrated a dense right homonymous hemianopia. Neurological examination was normal and cardiological examination revealed no new findings.

A diagnosis of occipital infarction was made, and computerized tomography demonstrated a remarkably localized infarction of the medial aspect of the left occipital lobe (Figure 1).



**Figure 1** Infarction of the left visual cortex demonstrated by computerized tomography.

## Discussion

A detailed case report published by Seguin in 1886 is one of the first descriptions of visual hallucination in the hemianopic field.<sup>1</sup> Our case demonstrates that such hallucination may be the sole presenting feature of an occipital infarct.

The value of this symptom in localizing the lesion has been the subject of debate. Early series of such cases (reviewed in reference 2) did not distinguish between visual hallucination as an epileptic aura or as an isolated visual phenomenon. More recent series have ascribed the symptom to occipital<sup>2-4</sup> or temporal<sup>5,6</sup> lesions, or concluded that it has no localizing value.<sup>7,8</sup>

Experimental stimulation of the visual cortex gives rise to phosphenes, but increasingly strong stimulation may result in a transition from phosphenes to complex visual hallucination.<sup>9</sup> Lance<sup>4</sup> presented 13 patients with complex visual hallucination in the hemianopic field. Three of these experienced the hallucination as part of an epileptic seizure. Of the remaining 10, 8 had damage limited to the occipital lobe. Lance determined that visual hallucination may have value as a localizing sign, especially when it appears unilaterally, as in an hemianopic field. Two of Lance's patients presented with formed hallucination in one hemifield as their only complaint and were then found to have an hemianopia affecting this side. One had an occipital infarction and the other an occipito-parietal infarction. These are the only other reports in the literature of such a presentation.

Kolmel<sup>2</sup> reports a series of 120 patients with homonymous hemianopia, 88 of which were due to

vascular brain disease. The 120 patients were specifically questioned with regard to hallucination. Sixteen had complex visual hallucination in the hemianopic field, but in none of these patients was the hallucination the presenting visual symptom. Their hallucination started between a few hours and one week after the initial visual loss. The hallucination described was of static objects in approximately half of the subjects, and moving complex scenes in the other half. The hallucination disappeared as the hemianopia resolved, or occurred less often and ultimately disappeared over a period of a few months. Twelve of the 16 patients also experienced other visual phenomena such as phosphenes. Complex visual hallucination disappeared when the patients carried out saccadic eye movement towards or away from the hallucinated images in all of Kolmel's patients. Pursuit movements did not have this effect. All 16 of these patients had occipital lesions demonstrated by computerized tomography.

Kolmel concluded that the two significant morphological findings in generating complex visual hallucination are: (i) an occipital lesion which causes the hemianopia and interrupts the physiological flow of visual information to the parietal and temporal lobe, and (ii) a more rostral subcortical lesion which mobilizes endogenous visual images. Our case does not lend support to the latter notion since the infarct shows extreme localization to the striate cortex (Figure 1). However, it does support the contention that formed hallucination in the hemianopic field suggests an occipital lesion. This is obviously a rare presenting symptom, but one of which the clinician should be aware.

## References

1. Seguin, E.G. A contribution of the pathology of hemianopsias of central origin (cortex-hemianopsia). *J Nerv Ment Dis* 1886, **13**: 1-38.
2. Kolmel, H.W. Complex visual hallucinations in the hemianopic field. *J Neurol Neurosurg Psychiatry* 1985, **48**: 29-38.
3. Allen, I.M. A clinical study of tumours involving the occipital lobe. *Brain* 1930, **53**: 194-243.
4. Lance, J.W. Simple formed hallucinations confirmed to the area of a specific visual field defect. *Brain* 1976, **99**: 719-734.
5. Cushing, H. The field defects caused by temporal lobe lesions. *Brain* 1921, **44**: 341-396.
6. Horrax, G. Visual hallucinations as a cerebral localizing phenomenon, with especial reference to their occurrence in tumours of the temporal lobe. *Arch Neurol Psychiat* 1923, **19**: 532-547.
7. Horrax, G. & Putnam, T.J. Distortion of the visual fields in cases of brain tumour. The field defects and hallucinations produced by tumours of the occipital lobe. *Brain* 1932, **55**: 499-523.
8. Weinberger, E.A. & Grant, F.C. Visual hallucinations and their neuro-optical correlates. *Arch Ophthalmol* 1940, **23**: 166-199.
9. Penfield, W. & Perot, P. The brains record of auditory and visual experience. *Brain* 1963, **86**: 596-696.