

Septic Arthritis of the Temporomandibular Joint—Unusual Presentations

Sapna Lobiya, DDS,* and Jasjit Dillon, DDS, MBBS†

This report describes 2 patients whose septic arthritis of the temporomandibular joint (SATMJ) presented atypically, resulting in treatment delay and complications. A 49-year-old man developed left-side facial allodynia, which was first treated unsuccessfully as trigeminal neuralgia. On day 21, the patient sustained facial trauma from a fall and presented to the emergency department (ED). Maxillofacial contrast-enhanced computed tomographic (CT) scan was suggestive of parotiditis, SATMJ, or hemarthrosis. His condition did not improve with empiric antibiotic treatment. On day 30, contrast-enhanced magnetic resonance imaging (MRI) confirmed SATMJ. Incision and drainage yielded 6 mL of pus and produced clinical improvement. Cultures grew methicillin-resistant *Staphylococcus aureus*, which was treated with amoxicillin plus clavulanate and sulfamethoxazole plus trimethoprim for 30 days. On day 59, the patient still had slight preauricular pain and CT-proved TMJ osteoarthritic changes. A 56-year-old woman developed right-side facial pain after a crown procedure on tooth 31. Oral prednisone (and clindamycin) produced partial relief. Her primary physician suspected temporal arteritis, but its biopsy result on day 11 was normal. Gradually, the patient developed trismus and malocclusion refractory to various medicines. On day 49, she presented to the ED. A contrast-enhanced maxillofacial CT scan suggested SATMJ. Incision and drainage yielded 30 mL of pus and produced clinical improvement. During days 50 to 57, the patient received intravenous ampicillin plus sulbactam and metronidazole. However, preauricular tenderness and drainage from the surgical incision persisted. On day 55, CT scan showed a residual abscess. Secondary debridement yielded 5 mL of pus. Culture grew coagulase-negative *S aureus*. On day 141, the patient still had slight preauricular pain and TMJ osteoarthritic changes on MRI. In these cases, the SATMJ diagnosis was delayed owing to the mildness of local and systemic manifestations, the possibility of confounding conditions, and the rarity of SATMJ. Contrast-enhanced CT and MRI facilitated the diagnosis. Abscess drainage alleviated the symptoms. Postinfectious osteoarthritis developed possibly from treatment delay. SATMJ should be considered in all patients with enigmatic preauricular pain, trismus, or malocclusion.

© 2015 American Association of Oral and Maxillofacial Surgeons

J Oral Maxillofac Surg ■ 1-8, 2015

Septic arthritis of the temporomandibular joint (SATMJ) is a rare condition, with an incidence of 2 to 10 cases per 100,000 population. It is characterized by preauricular pain, edema, malocclusion, and trismus. Complications include postinfectious osteoarthritis, osteomyelitis, bone erosions, ankylosis, sepsis, and brain abscess.¹⁻⁴ Early diagnosis and prompt treatment are crucial for preventing complications, but these can be hindered by confounding presentations. This report describes 2 challenging cases in which SATMJ was mistaken for trigeminal

neuralgia, parotiditis, hemarthrosis, and temporal arteritis. The relevant literature is reviewed.

Report of Cases

CASE 1

The patient was a 49-year-old man with a normal body mass index (23 kg/m²). He had had 2 prior methicillin-resistant *Staphylococcus aureus* (MRSA) abscesses: one on his left buttock 19 weeks previously and the other involving his left kidney 6 weeks

Received from the Department of Oral and Maxillofacial Surgery, University of Washington, Seattle, WA.

*Resident.

†Clinical Associate Professor and Program Director.

Address correspondence and reprint requests to Dr Dillon: Department of Oral and Maxillofacial Surgery, Harborview Medical Center, University of Washington, 325 Ninth Avenue, Box 359893, Seattle, WA 98104; e-mail: dillonj5@uw.edu

Received June 3 2015

Accepted June 22 2015

© 2015 American Association of Oral and Maxillofacial Surgeons

0278-2391/15/00901-5

<http://dx.doi.org/10.1016/j.joms.2015.06.166>

previously. He was being treated with warfarin for renal vein thrombosis secondary to his kidney infection. He was a smoker and a social drinker but did not have immunosuppression or diabetes and did not use intravenous (IV) drugs. He was otherwise healthy.

On day 0, the patient presented to the emergency department (ED) with a 4-day history of progressive left-side facial pain and allodynia. He had mild left-side facial edema without erythema, trismus, or malocclusion. His dentition was worn from bruxism. He was afebrile with normal vital signs. His sedimentation rate was 7 mm (normal, 0 to 20 mm) and his leukocyte count was 7,650/mm³ (normal, 4,000 to 11,000/mm³). The working diagnosis was trigeminal neuralgia and he was discharged with a muscle relaxant and narcotic analgesic.

On day 21, the patient returned to the ED with a left-side headache and facial abrasions after falling off a bicycle. Maxillofacial contrast-enhanced computed tomographic (CT) scan showed left parotid edema, a rim-enhancing left TMJ effusion, thick synovium, and bony erosions of the temporal fossa and mandibular condyle. Salivary flow from the left Stensen duct was decreased. Leukocyte count was normal (7,920/mm³). Differential diagnosis included parotiditis, post-traumatic hemarthrosis from background anticoagulation, nondisplaced high condylar fracture, and SATMJ. He was hospitalized and treated with IV ampicillin plus sulbactam 12 g and vancomycin 2.5 g daily.

Gradually, the patient developed trismus with reduction of maximum interincisal opening (MIO; 20 mm), malocclusion, and leukocytosis (11,210/mm³). Maxillofacial contrast-enhanced magnetic resonance imaging (MRI) confirmed left TMJ effusion with condylar erosion, adjacent inflammatory changes, and cervical lymphadenopathy. There was no T1 hyperintense lesion typical of hematoma (Fig 1). The patient underwent incision and drainage of the left TMJ through an intraoral approach with lateral access to the condyle. Blunt dissection yielded 6 mL of pus from within and around the TMJ capsule. There was no necrotic soft tissue or bone. Biopsy examination of deep tissue and periosteum specimens showed inflammatory changes (ie, remodeled bone, fibrosis, and mononuclear cells). Purulence sent for culture grew coagulase-positive and coagulase-negative MRSA. The patient was discharged from the hospital on day 35 with prescriptions for: oral amoxicillin plus clavulanate 875 to 125 mg (for penicillin-sensitive and -resistant gram-positive bacteria), sulfamethoxazole plus trimethoprim 800 to 160 mg (for MRSA), and chlorhexidine 0.12% oral rinse twice daily for 30 days.

On day 59, the patient's symptoms had largely resolved except for mild residual preauricular pain.

Contrast-enhanced CT scan visualized left TMJ osteoarthritis (bony erosions of the temporal fossa and condyle) with resolution of the abscess and lymphadenopathy (Fig 2).

CASE 2

The patient was a 56-year-old obese woman (body mass index, 34 kg/m²). She smoked but was not diabetic, an IV drug user, or immunodeficient. On day 0, she underwent a dental crown procedure on tooth 31; the procedure was notable for requiring multiple inferior nerve block attempts. Then, she developed an otherwise inexplicable right-side facial hyperalgesia. Her primary physician treated her with oral prednisone and clindamycin, which produced partial relief. Temporal arteritis was suspected, but its biopsy result on day 11 was normal. The patient was subsequently seen and treated by various providers with dexamethasone, methocarbamol, tizanidine, diazepam, piroxicam, and tramadol for her atypical facial pain.

The patient's symptoms persisted and she also developed trismus and malocclusion. On day 49, she presented to the ED with an indurated tender mass over her right zygoma, an MIO of 8 mm, and malocclusion. The temporal artery biopsy site was well healed. The patient's temperature was 38°C, her leukocyte count was 13,980/mm³, and her sedimentation rate was 88 mm. Contrast-enhanced maxillofacial CT scan showed a submasseteric abscess at the mandibular ramus communicating with the TMJ (Fig 3). The patient was hospitalized and scheduled for an operative incision and drainage procedure under general anesthesia. The abscess was drained through a preauricular incision yielding 30 mL of pus. Two Penrose drains were inserted. The patient was treated with IV ampicillin plus sulbactam 12 g and IV metronidazole 1.5 g daily. Culture grew coagulase-negative *S aureus*. Postoperatively, the patient developed right-side infranuclear facial palsy.

The patient's trismus and facial edema showed improvement, but mild preauricular pain, induration, and drainage from the surgical incision persisted. On day 58, repeat contrast-enhanced CT scan showed a residual abscess lateral to the right condyle (Fig 4). On day 60, debridement of the right preauricular and TMJ spaces through a submandibular incision and the existing preauricular incisions yielded an additional 5 mL of pus. A Molt retractor was repeatedly opened and closed intraorally to assist with alleviating trismus (Brisement procedure). Postoperatively, the patient was treated with oral amoxicillin plus clavulanate 1,750 mg daily for 30 days.

On day 141, the patient had mild preauricular pain with normal mandibular range of motion and

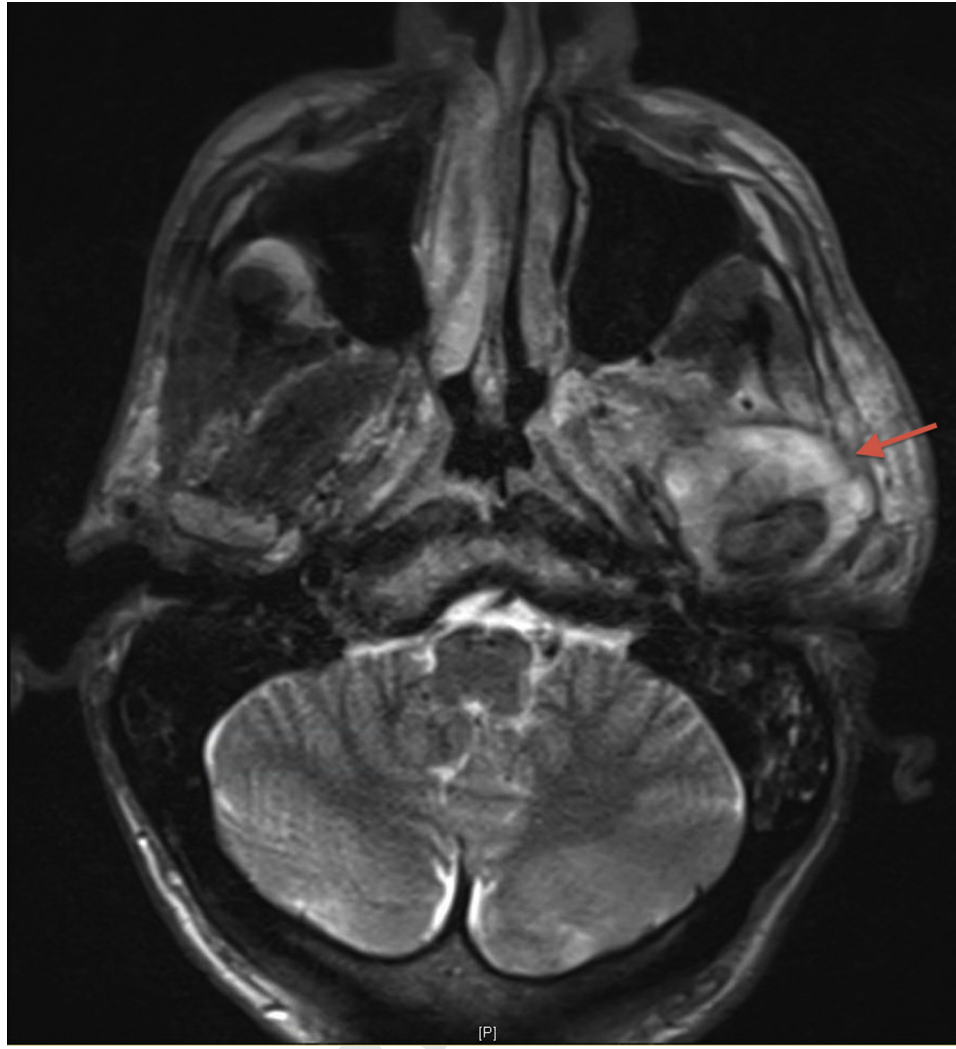

FIGURE 1. Case 1. Preoperative maxillofacial contrast T2-weighted magnetic resonance image on day 30 shows fluid collection (arrow) adjacent to the left temporomandibular joint with marked enhancement in the periphery of the collection, adjacent soft tissues, and muscles of the masticator space suggestive of infectious etiology.

Lohiya and Dillon. Septic Arthritis of Temporomandibular Joint. *J Oral Maxillofac Surg* 2015.

occlusion, trismus, or malocclusion. Her facial nerve weakness showed substantial improvement with physiotherapy (House-Brackman score, 2 of 6). MRI scan showed major osteoarthritic changes (bony erosion and inferior subluxation of the condyle and medial dislocation of the TMJ disc; Fig 5).

Discussion

These 2 cases illustrate the difficulties clinicians can encounter in diagnosing SATMJ and corroborate the dictum that real-life patients seldom present a classic textbook picture.⁴⁻¹⁰ In case 1, multiple conditions were considered in the differential diagnosis of unilateral facial pain. Trigeminal neuralgia was diagnosed because of otherwise inexplicable allodynia. Parotiditis was suspected because of parotid

swelling, decreased salivary flow from the Stensen duct, preauricular tenderness, and cervical lymphadenopathy. Condylar fracture was possible because the patient had facial trauma and an undisplaced fracture could be misinterpreted radiologically as bony erosion. Hemarthrosis was possible because of joint effusion and facial trauma in the setting of anticoagulation. CT findings (TMJ effusion, thick synovium, and bony erosions) suggested SATMJ but lacked fat stranding or phlegmon. Moreover, the local SATMJ manifestations (trismus, tenderness, and edema) were mild and nonspecific, and systemic inflammatory signs (fever, leukocytosis, elevated erythrocyte sedimentation rate, or tachycardia) were absent. Operative intervention was deferred owing to the plausibility of nonoperative conditions and greater hemorrhagic risk in a patient

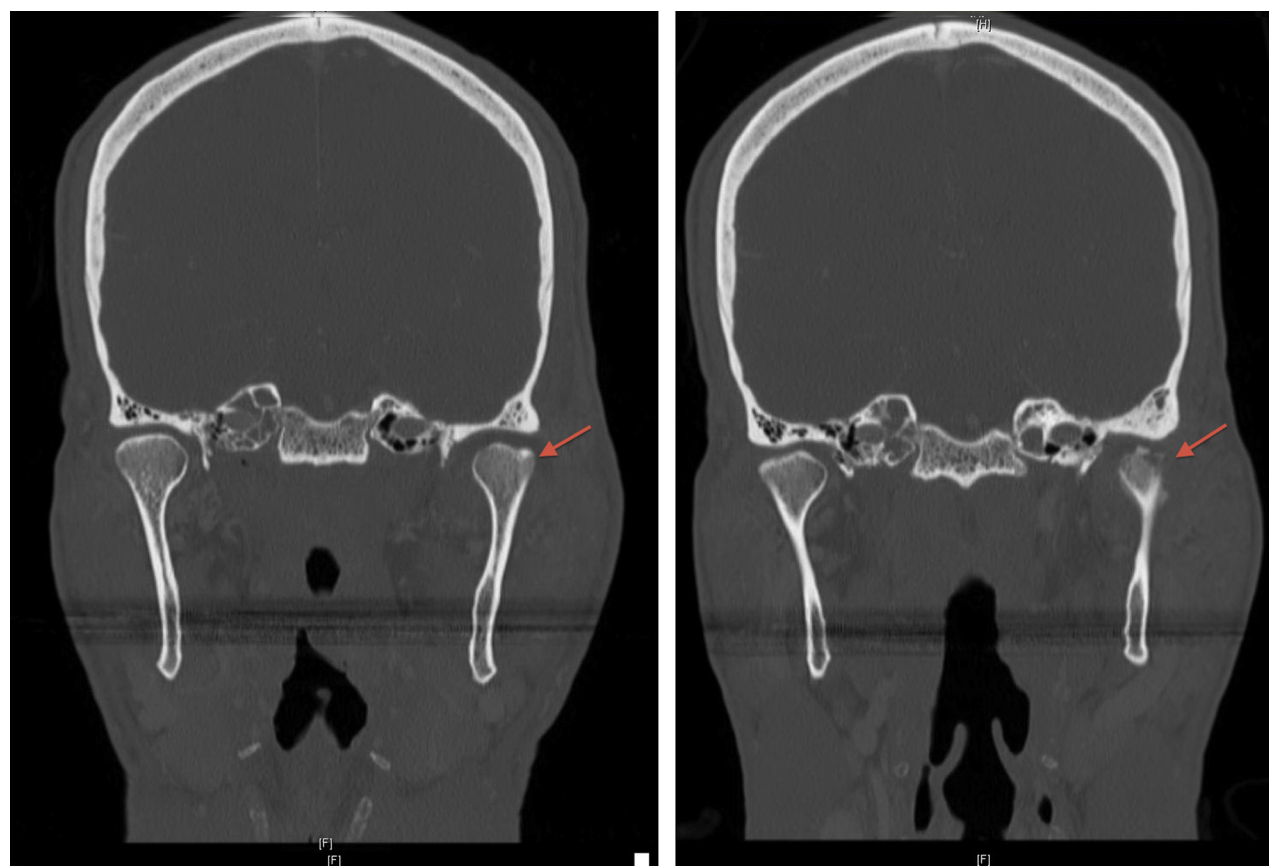


FIGURE 2. Case 1. *Left*, Preoperative (day 30) and *right*, postoperative (day 59) maxillofacial contrast-enhanced coronal computed tomograms show osteoarthritic changes of the left temporomandibular joint (arrows) at presentation and follow-up. The latter image also indicates resolution of the abscess and associated cervical lymphadenopathy.

Lobiya and Dillon. Septic Arthritis of Temporomandibular Joint. *J Oral Maxillofac Surg* 2015.

with anticoagulation. In case 2, SATMJ was mistaken for temporal arteritis because of the patient's older age, initial absence of trismus, anatomic consistency of pain, and preliminary relief with prednisone. In hindsight, the facial hyperalgesia in these cases was likely from inflammation-related stretch and chemical irritation of nerves and not a neurologic insult.

Cai et al⁴ reported one of the largest studies of SATMJ cases (40 cases occurring in China from 1995 through 2007); therefore, their work merits special attention. They and others have encountered the diagnostic delay problem, and this could contribute to the rarity of SATMJ.² There are likely 3 explanations for this phenomenon. First, the local inflammatory signs (heat, swelling, redness, and pain) of SATMJ are nonspecific and might be subtle owing to the anatomic location of the TMJ deep to the parotid gland and the masseter. Second, systemic manifestations might be few owing to the small size of the TMJ. Third, widespread antibiotic usage for unrelated conditions can cure some early but undiagnosed SATMJ cases.

Owing to the difficulty in diagnosing SATMJ, imaging plays a key role in elucidating these cases. These

2 cases required contrast-enhanced CT and MRI scans, modalities used almost universally.³⁻¹¹ Cai et al⁴ noted joint space widening and decreased condylar movement using plain radiography for their first 33 patients, but after 2003 they performed MRI scans for the remaining 7 patients. MRI and CT scans visualize bone and soft tissue with excellent resolution and are noninvasive. CT scanning requires only 2 to 3 minutes but involves radiation exposure (1,088.3 μ Sv; natural background radiation, 3,000 μ Sv/yr).¹² MRI involves no radiation but requires 30 to 45 minutes and is contraindicated in patients with metallic implants. Contrast dye allows better visualization of small defects in the joint capsule and articular surfaces because it permeates tiny spaces; however, there is risk of allergy and nephrotoxicity.

As usual, a thorough clinical history can always contribute valuable information to the diagnostic challenge. SATMJ most often arises through hematogenous transmission and was the probable mechanism in case 1 (from skin and renal abscess). TMJ is inherently vulnerable to this route because the high vascularity of its synovial membrane allows greater exposure to

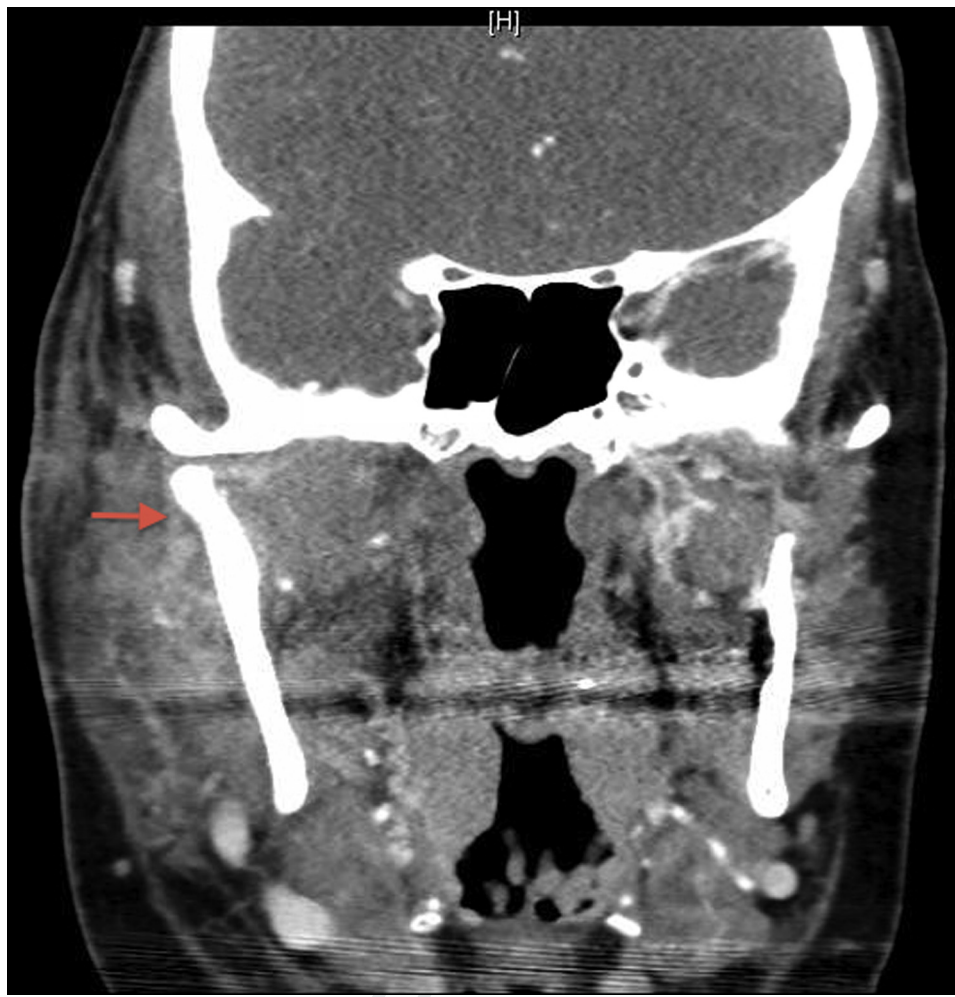

FIGURE 3. Case 2. Preoperative maxillofacial contrast-enhanced coronal computed tomogram on day 49 displays a periosteal submasseteric abscess (arrow) at the mandibular ramus communicating with the temporomandibular joint.

Lohiya and Dillon. Septic Arthritis of Temporomandibular Joint. J Oral Maxillofac Surg 2015.

bacteria. Because blood also offers antibacterial protection, micro-organism seeding requires predisposition by joint damage (trauma, metastatic cancer, joint disease, of bisphosphonate treatment⁸) or immunodeficiency (eg, systemic corticosteroids and acquired immunodeficiency syndrome). Leighty et al² reported 2 pediatric SATMJ cases after blunt trauma; they attributed the association to greater bacterial access after damage to the local anatomy and hematoma formation providing a favorable medium for bacterial growth. Contiguous spread also is common after dental procedures^{6,11} (as in case 2), parotiditis, mastoiditis, or otitis.⁷ Risk of iatrogenic implantation during arthrocentesis reinforces the need for impeccable sterile techniques. In many cases, the source of infection remains unknown. For example, Cai et al⁴ found original primary infection in only 15 of their 40 cases (11 cases of hematogenous spread [respiratory, 7; kidney, 1; unknown fever, 3] and 4 cases of contiguous spread).

Once the diagnosis has been made, the therapeutic approach is standard (ie, establish drainage if purulence is present and support with antibiotic therapy). There are several techniques described for establishing drainage. The authors performed drainage with skin incisions through the submandibular and preauricular approaches. Cai et al⁴ performed arthrocentesis in 35, drainage by submandibular incision in 2, and arthroscopic debridement in 9 (including 5 with failed arthrocentesis). Sembronio et al¹¹ preferred arthroscopy because it benefits direct visualization, diagnostic confirmation, and ability to lyse adhesions and stretch the joint capsular.

TMJ has a total joint capacity of 2 mL; therefore, the SATMJ pus volume is usually small. Pus volume was 5 mL in case 1 and 30 mL in case 2 (the larger amounts were due to collections in associated spaces). Gayle et al³ described a case in which pus volume was only 1 mL in a 6-year-old boy.

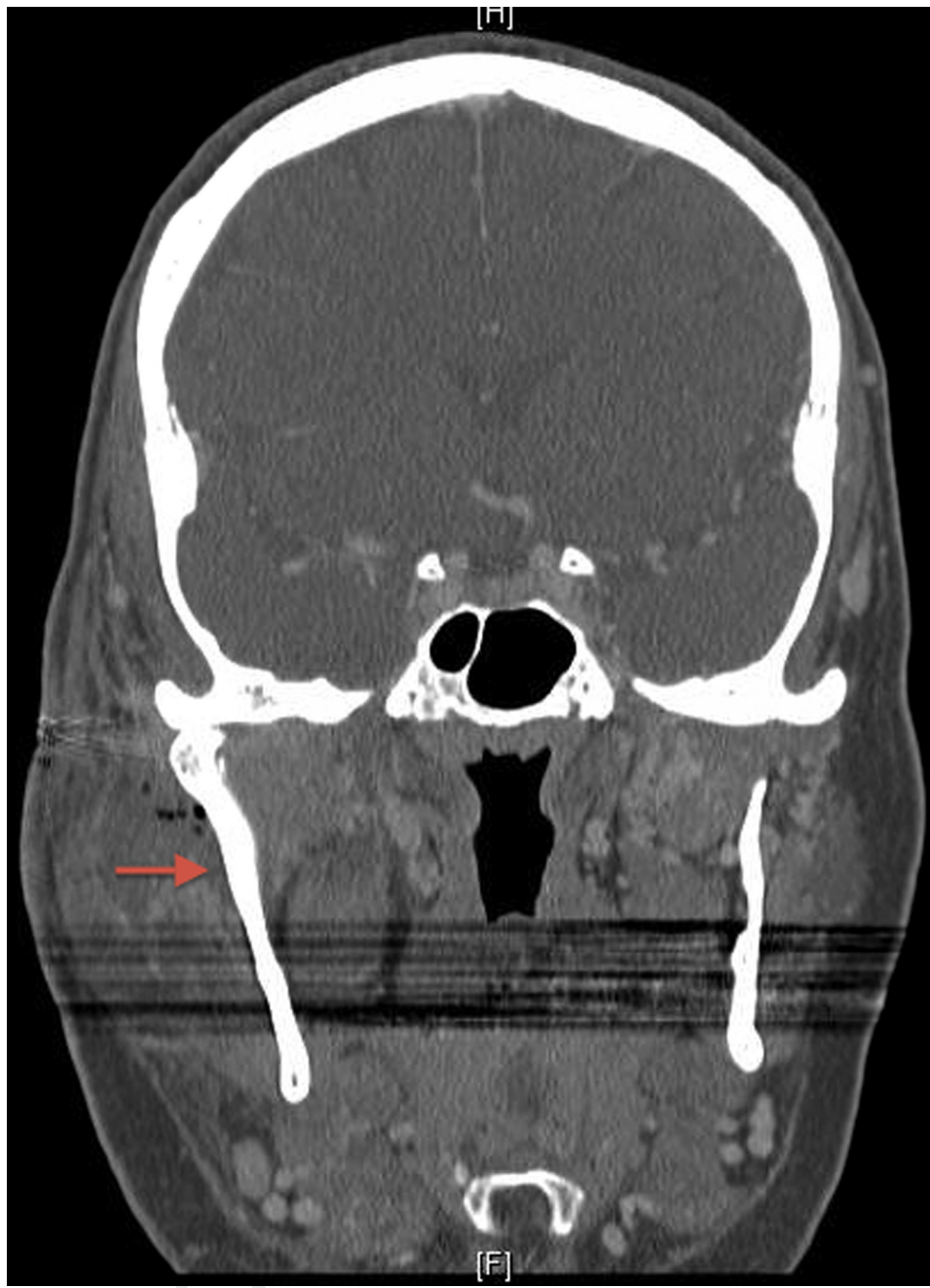

FIGURE 4. Case 2. Maxillofacial contrast-enhanced coronal computed tomogram on day 58 after the first surgery, but before the second surgery, shows a residual abscess (arrow) lateral to the right condyle.

Lobiya and Dillon. Septic Arthritis of Temporomandibular Joint. *J Oral Maxillofac Surg* 2015.

Staphylococcus aureus is the most common infecting organism in SATMJ, as in the present cases. There have been occasional reports involving *Staphylococcus saprophyticus*, *Neisseria gonorrhoea*, *Streptococcus viridans*, and *Haemophilus influenza*.²⁻⁴ Owing to the high community prevalence of MRSA, vancomycin or sulfonamides are needed for SATMJ treatment. Goldschmidt et al¹³ recommended antibi-

otic therapy for a 30-day total course, modulated by the patient's clinical response.

Prompt diagnosis and treatment of SATMJ can result in full recovery.⁵ In the present cases, chronic TMJ problems can be expected owing to the development of postinfectious osteoarthritic changes, a common complication of treatment delay.^{8,10} The presence of osteoarthritis only in the affected joint in the present

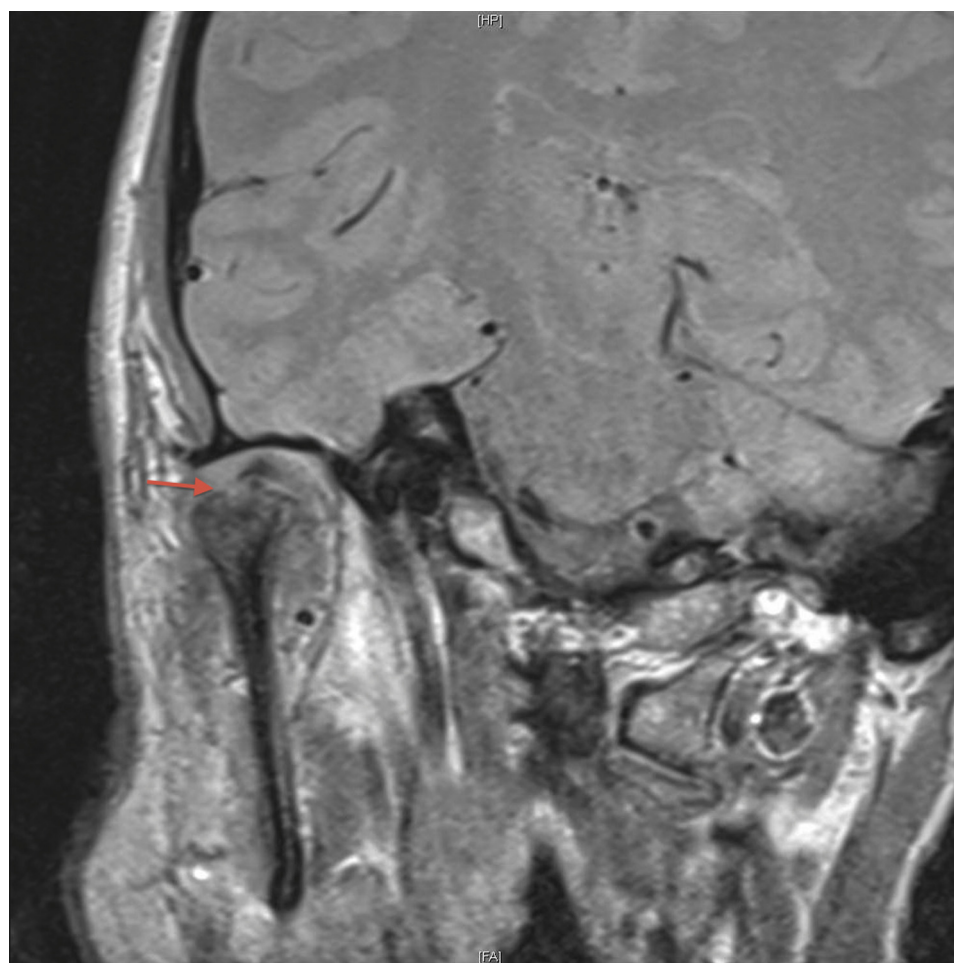


FIGURE 5. Case 2. Maxillofacial contrast-enhanced T1-weighted magnetic resonance image on day 141 shows osteoarthritic changes (bony erosion and inferior subluxation of the condylar head and medial dislocation of the temporomandibular joint disc) (arrow).

Lohiya and Dillon. Septic Arthritis of Temporomandibular Joint. *J Oral Maxillofac Surg* 2015.

cases indicates that it is probably not related merely to age. Leighty et al² described a case in which treatment delay led to osteomyelitis requiring total TMJ arthroplasty in an 18-year-old woman. Bounds et al¹⁴ and Hekkenberg et al¹⁵ described similar cases requiring condylectomies.

The present cases illustrate the insidious patterns of SATMJ and associated diagnostic challenges. Meticulous clinical history and examination, CT and MRI, and surgical exploration are important. To avoid serious complications, SATMJ should be considered in all patients with preauricular pain, trismus, or malocclusion when the common causes (eg, trauma, myalgia, osteo- or rheumatoid arthritis) are ruled out. Clinicians should be prepared to expand the diagnostic alternatives if patients do not respond as expected to the initial working diagnoses.

References

- Mayne JG, Hatch GS: Arthritis of the temporomandibular joint. *J Am Dent Assoc* 79:125, 1969
- Leighty S, Spach D, Myall R: Septic arthritis of the temporomandibular joint: Review of the literature and report of two cases in children. *Int J Oral Maxillofac Surg* 22:292, 1993
- Gayle EA, Young SM, McKenna SJ: Septic arthritis of the temporomandibular joint: Case reports and review of the literature. *J Emerg Med* 45:674, 2013
- Cai X, Yang C, Zhang Z: Septic arthritis of the temporomandibular joint: A retrospective review of 40 cases. *J Oral Maxillofac Surg* 68:731, 2010
- Kluppel L, Bernabé F, Primo B: Septic arthritis of the temporomandibular joint. *J Craniofac Surg* 23:1752, 2012
- de Oliveira N, de Souza M, Sawazaki R: Temporal abscess after third molar extraction in the mandible. *Oral Maxillofac Surg* 16:107, 2012
- Mardinger O, Rosen D, Minkow B: Temporomandibular joint involvement in malignant external otitis. *Oral Surg Oral Med Oral Pathol Oral Radiol Endod* 96:398, 2003
- Hyung-Mo K, Tae-Wan K, Ju-Hong H: Infection of the temporomandibular joint: A report of three cases. *J Korean Assoc Oral Maxillofac Surg* 37:510, 2011
- Enomoto A, Uchihashi T, Izumoto T: Suppurative arthritis of the temporomandibular joint associated with bisphosphonate: A case report. *J Oral Maxillofac Surg* 70:1376, 2012
- Kito S, Hirashima S, Yoshioka I: A case of chronic infectious arthritis of the temporomandibular joint associated with osteomyelitis without malocclusion. *Open Dent J* 4:29, 2010
- Sembronio S, Albiero M, Robiony M: Septic arthritis of the temporomandibular joint successfully treated with

- arthroscopic lysis and lavage: Case report and review of the literature. *Oral Surg Oral Med Oral Pathol Oral Radiol Endod* 103:e1, 2007
12. Loubele M, Bogaerts R, Van Dijck E, et al: Comparison between effective radiation dose of CBCT and MSCT scanners for dento-maxillofacial applications. *Eur J Radiol* 71:461, 2009
13. Goldschmidt MJ, Butterfield KJ, Goracy ES, et al: Streptococcal infection of the temporomandibular joint of hematogenous origin: A case report and contemporary therapy. *J Oral Maxillofac Surg* 60:1347, 2002
14. Bounds GA, Hopkins R, Sugar A: Septic arthritis of the temporomandibular joint: A problematic diagnosis. *Br J Oral Maxillofac Surg* 25:61, 1987
15. Hekkenberg RJ, Piedade L, Mock D, et al: Septic arthritis of the temporomandibular joint. *Otolaryngol Head Neck Surg* 120:780, 1999