

Radiological and clinical features of basal ganglia infarction in tuberculous meningitis

P. S. TANG and L. C. K. LOW

Department of Paediatrics, Queen Mary Hospital, Pokfulam, Hong Kong

Abstract A patient with choreoathetosis and dystonia who had computerized tomography evidence of basal ganglia damage resulting from tuberculous meningitis is presented. It is important to distinguish these extrapyramidal movements from fits, and the observation of such movements in a clinical setting of meningitis should alert physicians to the diagnosis of tuberculous meningitis.

Key words: basal ganglia infarction; extrapyramidal movements; tuberculosis meningitis.

Although signs of neurological dysfunction are frequently encountered in patients during the course of bacterial meningitis, extrapyramidal movement disorders in such patients are rarely reported in the literature.¹ The clearest association has been demonstrated with tuberculous meningitis, and extrapyramidal movement disorders have been reported to occur in a frequency varying from 0.5 to 13%.² Cerebral infarcts involving the basal ganglia and internal capsule have been shown to occur in a significant proportion of children with tuberculous meningitis, using computerized tomography (CT) scanning,³ but so far little effort has been made to correlate the clinical signs with the CT findings.^{2,4} We describe here the CT features in a patient with tuberculous meningitis showing extrapyramidal movements.

CASE REPORT

The patient was a Chinese girl aged 4 years who was delivered normally without any neonatal complication. Her early development had been normal and she had been vaccinated according to the local schedule, including BCG vaccination at birth. She was admitted to a private hospital with a 10-day history of fever and vomiting. On the day of her admission, she developed a left sided convulsion that lasted 5 min. A lumbar puncture was performed and examination of the cerebrospinal fluid (CSF) revealed 280 leucocytes/mm³ (90% polymorphonuclear cells and 10% lymphocytes). The CSF protein concentration was elevated and the CSF glucose concentration was low. She was treated with intravenous phenobarbitone (12 mg/kg loading dose, followed by 2.5 mg/kg per 8 h) and ceftazidime. She was transferred to our hospital the next day because of repeated convulsions.

On admission to our hospital she was unconscious but was able to localize and respond to noxious stimuli. She had intermittent involuntary purposeless writhing movements

involving the upper and lower limbs on the left side, together with facial grimacing. She also had a left sided third nerve palsy. The muscle tone was increased in the four limbs and the deep tendon reflexes were brisk. Extensor plantar responses were elicited bilaterally. CT brain scan showed hypodense areas of both caudate nuclei, but no basal meningeal enhancement with contrast or ventricular dilatation were demonstrated (Fig. 1a). Electroencephalogram showed diffuse slowing without epileptic discharges. A lumbar puncture was repeated and the CSF cell count was 47 leucocytes/mm³ (79% polymorphonuclear cells). The CSF protein concentration was 0.73 g/L and that of the CSF glucose was 1.02 mmol/L with a blood glucose level of 4.3 mmol/L. Gram stain and Ziehl-Neelsen stain of CSF smears failed to demonstrate any organisms. The haemoglobin was 12.3 g/dL and the white count was 9600/mm³ with 79% polymorphonuclear leucocytes. The erythrocyte sedimentation rate was 37 mm in the first hour. The Mantoux test was negative but perihilar lymph nodes were demonstrated on the right side on the chest radiograph. *Mycobacterium tuberculosis* was isolated from the sputum 6 weeks later. However, no organisms were isolated from the CSF or urine. Tuberculostearic acid was identified by gas chromatography/mass spectrometry in the CSF taken 3 weeks after presentation (Prof. G. L. French, Prince of Wales Hospital, Chinese University of Hong Kong).

Initial antimicrobial therapy was designed to cover both bacterial (high percentage of polymorphonuclear cells in the CSF) and tuberculous meningitis. The strong clinical suspicion of tuberculous meningitis was based on the presence of basal ganglia infarction on CT and perihilar lymph nodes on the chest radiograph. Only treatment with streptomycin, isoniazid, rifampicin, pyrazinamide and phenobarbitone was continued. Six days after admission, the left sided choreoathetoid movements became less frequent. CT scan with contrast showed ventricular dilatation, hypodense lesion in the right caudate nucleus, and a contrast enhanced lesion in the left caudate nucleus. In the following week, the patient was noticed to have generalized increase in muscle tone (lead pipe rigidity) with intermittent dystonic posturing of limbs, trunk torsion movements, and facial grimacing. A repeat CT brain scan 16 days after admission showed resolution of the lesion on the left caudate nucleus but a contrast enhancing lesion was demonstrated in

Correspondence: L. C. K. Low, Department of Paediatrics, Queen Mary Hospital, Pokfulam, Hong Kong.

P. S. Tang, MB, BS, MRCP, Lecturer. L. C. K. Low, BSc, MB, ChB, FRCP(Edin.), Senior Lecturer.

Accepted for publication 20 July 1989.

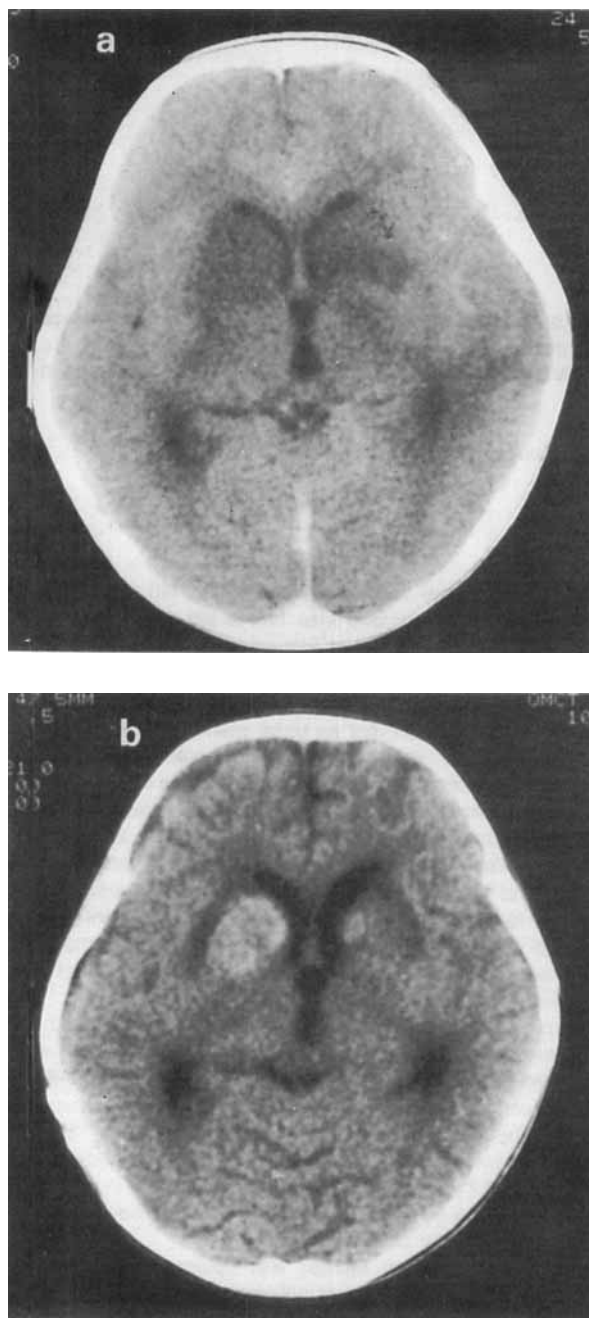


Fig. 1 CT brain scan with contrast (a) on admission and (b) 16 days after admission.

the right caudate nucleus (Fig. 1b). A Rickham reservoir was inserted 10 days after presentation for progressive hydrocephalus, and ventriculoperitoneal shunting was performed 2 weeks later when the meningeal infection was under control (decrease in cell count and normalization of CSF glucose and protein levels).

With antituberculous therapy, there was a gradual normalization of the abnormal CSF findings. The patient regained consciousness 3 weeks after presentation and the third nerve palsy also improved. The patient suffered severe neurological

damage and was found to have visual and hearing impairment. The dystonia and orofacial dyskinesia persisted and there was no response to diphenhydramine (75 mg/day) or benzodiazepines (1 mg/kg per day) and only a partial response to L-dopa at a dose of 20 mg/kg per day. Mild dystonia was still present while on treatment with L-dopa 9 months after her presentation.

DISCUSSION

Extrapyramidal movements have been described in patients with tuberculous meningitis but their association with other forms of bacterial meningitis is less well defined. The basis of the disorder is presumed to be either ischaemic damage to the subputaminal or subthalamic areas and their connections from endarteritis, or vascular compromise from delayed hypersensitivity and immune complex deposition.¹ Contrast enhancement of the basal cistern on CT brain scan is frequently associated with the development of basal ganglia infarction.³ Extrapyramidal movements in patients with tuberculous meningitis may be observed at the time of presentation or may develop in the course of the illness.^{2,4} Our patient initially presented with unilateral choreoathetosis, but bilateral basal ganglia lesions were demonstrated on the initial CT scan. Thus, unilateral development of dyskinesia does not necessarily reflect unilateral basal ganglia damage. Furthermore, dyskinesia may not be evident in patients with basal ganglia damage because the dyskinesia may be masked by the simultaneous presence of other neurological deficit.

Another interesting observation in this patient is that unilateral choreoathetosis progressed to generalized dystonia which persisted despite antituberculous therapy. The dystonia was partially improved by treatment with L-dopa. It is important for clinicians to recognize that extrapyramidal movements like chorea, athetosis, ballismus, and dystonia can occur in the course of tuberculous meningitis, and to be able to differentiate these movements from epileptic seizures. Not only are anticonvulsants ineffective in the treatment of these movement disorders, but anticonvulsants themselves, especially phenytoin, can cause dyskinesia.⁵

The diagnosis of tuberculous meningitis remains a difficult clinical problem because of its insidious presentation. The observation of extrapyramidal movements in a clinical setting of meningitis should alert physicians to such a diagnosis. The presence of lesions in the basal ganglia and contrast enhancement of the basal cistern on CT brain scan should lend further support to such a diagnosis.

REFERENCES

- 1 Burstein L., Breningstall G.N. Movement disorders in bacterial meningitis. *J. Pediatr.* 1986; **109**: 260-4.
- 2 Babikian V.L., Heydemann P.T., Swisher C.N. Extrapyramidal movement in a patient with tuberculous meningitis. *Clin. Pediatr.* 1985; **24**: 113-4.
- 3 Kingsley D.P.E., Hendrickse W.A., Kendall B.E., Swash M., Singh V. Tuberculosis meningitis: role of CT in management and prognosis. *J. Neurol. Neurosurg. Psychiatry* 1987; **50**: 30-6.
- 4 Riela A., Roach E.S. Choreoathetosis in an infant with tuberculous meningitis. *Arch. Neurol.* 1982; **39**: 596.
- 5 Krishnamoorthy K.S., Zulneraitis E.L., Young R.S.K., Bernad P.G. Phenytoin-induced choreoathetosis in infancy: case report and a review. *Pediatrics* 1983; **72**: 831-3.