

Delayed leg weakness due to peri-lesional neural degeneration in a patient with intracerebral haemorrhage: case report

Sung Ho Jang¹ · Jeong Pyo Seo¹

Received: 21 May 2015 / Accepted: 11 July 2015
© Belgian Neurological Society 2015

Keywords Apraxia · Intracerebral hemorrhage · Hemiparesis · Stroke

Introduction

Stroke is often accompanied by neural degeneration [1]. Many studies have reported on Wallerian degeneration that started immediately after neuronal injury at acute stage of stroke [1–3]. Wallerian degeneration is a process characterized by degeneration of the nerve axon and its myelin sheath distal to the neural injury in the central and peripheral nervous system. By contrast, little is known about peri-lesional neural degeneration in stroke patients.

In the current study, we report on a patient with an intracerebral hemorrhage (ICH), who showed delayed leg weakness associated with peri-lesional neural degeneration.

Case report

A 59-year-old, right-handed female presented with right hemiplegia, which occurred at the onset of a spontaneous ICH in the left corona radiata and basal ganglia and subdural hematoma in the left frontal area. She underwent

decompressive craniectomy and removal of hematoma at the department of neurosurgery of a university hospital. She had no arteriovenous malformation or other vascular pathology in the MR angiography. She had a history of brain CT-guided stereotactic drainage of hematoma due to a spontaneous ICH in the left corona radiata and basal ganglia, and intraventricular hemorrhage 10 months ago; however, her motor function of the right side had recovered completely at 6 months after onset. At 4 weeks after onset of the second ICH, she was transferred to the rehabilitation department of the same university hospital for rehabilitation. Brain MR images scanned at 4 weeks after onset of the second ICH showed a leukomalactic lesion in the left corona radiata and parietotemporal lobes (Fig. 1a).

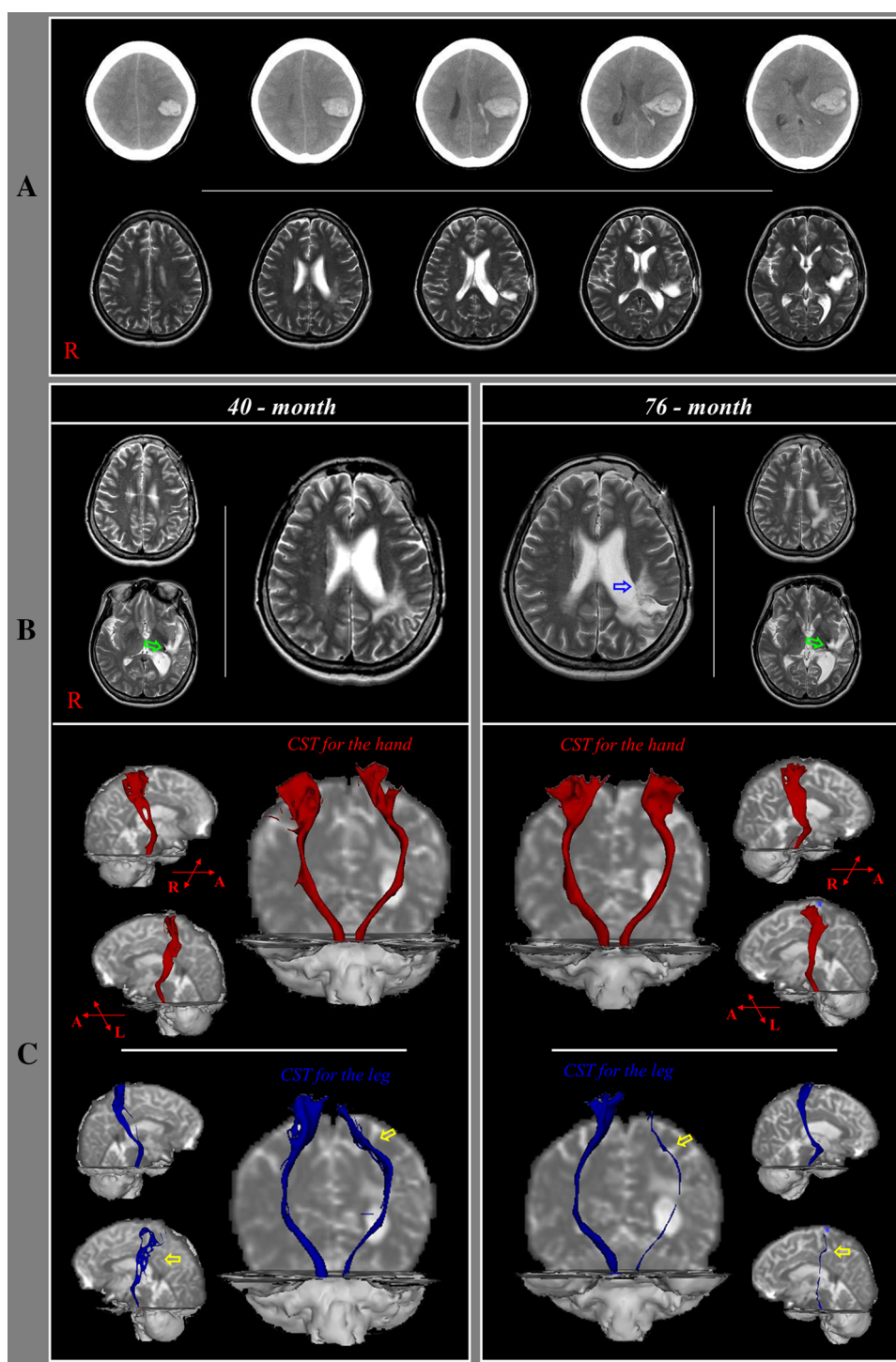
Motor function of the affected side was measured using the Medical Research Council (MRC) scale. She presented with complete paralysis of the right upper and lower extremities at onset of the second ICH and had recovered as much as MRC (4⁺) for the right upper extremity and MRC (4) for the right lower extremity at 4 months after onset. As a result, she was able to perform all activities of daily living and walk independently. At 48 months after onset of the second ICH, she started to slip and fall down intermittently and showed slow aggravation with passage of time with fluctuation. The motor function of the right extremities had not changed, except for the right ankle, which was impaired from 4 to 2 as MRC of the right ankle dorsiflexor. The weakness of the right leg was slowly aggravated until 76 months after onset: the hip flexor; 4 → 2⁺, the knee extensor; 4 → 2⁺, and the ankle dorsiflexor; 2 → 2⁻. T2-weighted brain MR images at 76 months after onset of the second ICH showed extension of the leukomalactic lesion to adjacent white matter anteriorly. However, no abnormality was observed on the electromyography study for both lower extremities

✉ Jeong Pyo Seo
raphael0905@hanmail.net

Sung Ho Jang
strokerehab@hanmail.net

¹ Department of Physical Medicine and Rehabilitation, College of Medicine, Yeungnam University, 317-1, Daemyungdong, Namku, Taegu 705-717, Republic of Korea

Fig. 1 CSTs for hand and leg are identified by choosing fibers passing through both regions of interest (ROIs). Seed ROI is placed on the ponto-medullary junction on the color map (*blue portion* of the anterior ponto-medullary junction). A target ROIs for hand and leg are placed on the primary motor cortex based on known anatomy (hand: the precentral knob; leg: mediodorsal portion). **a** Brain CT images at onset show spontaneous intracerebral hemorrhage in the left corona radiata and basal ganglia, and subdural hematoma in the left frontal area. T2-weighted brain MR images at 4 weeks after onset of the second ICH show a leukomalactic lesion in the left corona radiata and fronto-temporal areas. **b** T2-weighted brain MR images (*upper*) at 40 months after onset of the second ICH show extension of the leukomalactic lesion to the posterior white matter of the left lateral ventricle and a medially similar lesion compared with 4-week brain MR images. T2-weighted brain MR images at 76 months after onset of the second ICH show extension of the leukomalactic lesion to adjacent white matter anteriorly (*blue arrow*). In addition, the hemosiderin deposition is observed (*green arrows*). **c** On both 40- and 76-month DTT, the integrity of the CSTs was well preserved in both hemispheres. However, on 76 month-DTT, the left CST had become thinner compared with 40-month DTT (*yellow arrows*)



(Table 1). The patient provided informed consent, and the study protocol was approved by our institutional review board.

Diffusion tensor image scanning was performed two times (40 and 76 months after onset of the second ICH) using a six-channel head coil on a 1.5-T Philips Gyroscan Intera unit (Hoffman-LaRoche, Ltd, Best, the Netherlands) by single-shot echo-planar imaging using a navigator echo.

Imaging parameters were as follows: matrix = 128×128 matrix, field of view = $221 \times 221 \text{ mm}^2$, TR = 10,726 ms, TE = 76 ms, SENSE factor = 2, EPI factor = 67 and $b = 1000 \text{ s/mm}^2$, NEX = 1, and slice thickness = 2.3 mm. Diffusion-weighted imaging data were analyzed using Oxford Centre for Functional Magnetic Resonance Imaging of the Brain (FMRIB) Software Library software (FSL; www.fmrib.ox.ac.uk/fsl).

Table 1 Changes of motor function of right extremities and diffusion tensor tractography parameters

Duration from the onset of second ICH	Onset	40 months	48 months	76 months
MRC				
Shoulder abductor	0	4 ⁺	4 ⁺	4 ⁻
Elbow flexor	0	4 ⁺	4 ⁺	4 ⁻
Finger flexor	0	4 ⁺	4 ⁺	4 ⁻
Hip flexor	0	4	4	2 ⁺
Knee extensor	0	4	4	2 ⁺
Ankle dorsiflexor	0	4	2	2 ⁻
DTT parameters				
Fractional anisotropy	Lt CST for the hand	0.318	–	0.323
	Lt CST for the leg	0.312	–	0.317
Tract volume	Lt CST for the hand	1861	–	1863
	Lt CST for the leg	543	–	294

ICH intracerebral hemorrhage, *MRC* Medical Research Council, *DTT* diffusion tensor tractography, *CST* corticospinal tract

On both 40- and 76-month diffusion tensor tractography (DTT), the integrity of the corticospinal tracts (CSTs) was well preserved in both hemispheres. However, on 76-month DTT, the left CST for the leg had become thinner compared with the 40-month DTT. The tract volume of the left CST for the leg was decreased from 543 to 294 (Table 1).

Discussion

In this study, we think that the delayed weakness of the right leg in this patient could be ascribed to peri-lesional neural degeneration, for the following reasons. The patient showed delayed weakness of the right leg, which started at 48 months after onset of the second ICH; we found that the malactic lesion of the left corona radiata was extended. The extended area of the left corona radiata corresponded to the leg somatotopy of the CST [4]. We confirmed that the leg somatotopy of the left CST had degenerated because the left CST for the leg had become thinner on 76-month DTT compared with 40-month DTT.

As a result, we assumed that the CST for the right leg was injured by peri-lesional neural degeneration at the left corona radiata. However, the peri-lesional neural degeneration appeared to have progressed even before 40 months after onset of the second ICH because 40-month brain MRI also showed some extension of the lesion, compared with that of 4 weeks after onset of the second ICH. Regarding the pathophysiological mechanism of peri-lesional neural degeneration in the corona radiata, injury of peri-lesional white matter might occur through a chemical mechanism [5].

In conclusion, we report on a patient who showed delayed leg weakness associated with peri-lesional neural degeneration. We think that the motor weakness of the right leg was the result of injury of the CST for the left leg

caused by peri-lesional neural degeneration. To the best of our knowledge, this is the first study to report on peri-lesional degeneration in stroke patients.

Acknowledgments This work was supported by the National Research Foundation (NRF) of Korea Grant funded by the Korean Government (MSIP) (2015R1A2A2A01004073).

Compliance with ethical standards

Conflict of interest The authors declare that they have no conflict of interest.

Ethical standard This article does not contain any studies with human participants performed by any of the authors.

Informed consent Informed consent was obtained from all individual participants included in the study.

References

1. Yu C, Zhu C, Zhang Y, Chen H, Qin W, Wang M, Li K (2009) A longitudinal diffusion tensor imaging study on Wallerian degeneration of corticospinal tract after motor pathway stroke. *Neuroimage* 47(2):451–458. doi:10.1016/j.neuroimage.2009.04.066
2. Thomalla G, Glauche V, Koch MA, Beaulieu C, Weiller C, Rother J (2004) Diffusion tensor imaging detects early Wallerian degeneration of the pyramidal tract after ischemic stroke. *Neuroimage* 22(4):1767–1774. doi:10.1016/j.neuroimage.2004.03.041
3. Werring DJ, Toosy AT, Clark CA, Parker GJ, Barker GJ, Miller DH, Thompson AJ (2000) Diffusion tensor imaging can detect and quantify corticospinal tract degeneration after stroke. *J Neurol Neurosurg Psychiatry* 69(2):269–272
4. Kwon HG, Yang JH, Park JB, Kim MH, Choi SH, Yang DS (2014) Anatomical location and somatotopic organization of the corticospinal tract in the corona radiata of the normal human brain: a diffusion tensor tractography study. *NeuroReport* 25(9):710–714. doi:10.1097/WNR.0000000000000170
5. Chua CO, Chahboune H, Braun A, Dummula K, Chua CE, Yu J, Ungvari Z, Sherbany AA, Hyder F, Ballabh P (2009) Consequences of intraventricular hemorrhage in a rabbit pup model. *Stroke* 40(10):3369–3377. doi:10.1161/STROKEAHA.109.549212