

# Mucor Thrombus

E. L. Scharf<sup>1</sup> · H. J. Cloft<sup>1</sup> · E. Wijndicks<sup>1</sup>

© Springer Science+Business Media New York 2015

## Abstract

**Background** To describe a rare presentation of ischemic stroke secondary to angioinvasive mucormycosis and endovascular retrieval of mycotic thrombus with stenting of the compressed vessel.

**Summary of Case** We report a case of angioinvasive mucormycosis that externally compressed and invaded the internal carotid artery causing ischemic cerebral infarction. A sample of the thrombus was obtained using a stent retriever. Subsequent pathological analysis was shown to be consistent with the diagnosis of angioinvasive mucormycosis. The thrombosed and compressed segment was recanalized with the deployment of a stent.

**Conclusions** The endovascular placement of an expandable stent in the setting of angioinvasive mucormycosis restored good cerebral blood flow in a proximal internal carotid artery occlusion. The patient's aphasia resolved following this intervention. Artifacts of CT angiography may result in the overestimation of acute arterial occlusions. Endovascular carotid stenting may be a palliative measure in the setting of angioinvasive rhino-cerebro-orbital mucormycosis.

## Introduction

Mucoraceae are a family of fungi that contain four genera *Absidia*, *Mucor*, *Rhizomucor*, *anidia*, *Mucor*, *Rhizomucor*, and *Rhizopus* well described as opportunistic pathogens in

humans. Although spores are ubiquitous in the environment, immunocompetent individuals are naturally resistant. Known presentations of mucormycosis include pulmonary, cutaneous, gastrointestinal, renal, rhino-orbital-cerebral, and disseminated fungemia [1]. Immunocompromised individuals are at increased risk for this fungal infection, particularly in the setting of burns, corticosteroid use, hematological malignancy, and solid organ or bone marrow transplant. *Rhizopus* species withstand acidic environments because these species possess aldo-keto reductases [2]. Neurological complications of *mucormycosis* previously described include carotid artery occlusion [3–8], ophthalmic artery occlusion [9], and cavernous sinus thrombosis [10]. This case report describes a rare presentation of carotid occlusion and ischemic stroke that resulted from an angioinvasive *Mucor* thrombus that was retrieved and the occluded vessel was stented.

## Case History

A 56-year-old man with a history of sarcoidosis and multiple myeloma on treatment with lenalidomide and dexamethasone and pulmonary embolism on long-term anticoagulation underwent an MRI for left eye pain and diplopia. On examination, the patient had a left sixth cranial nerve palsy. MRI showed left orbital optic nerve sheath enhancement. Plasmacytoma, infection, and inflammatory pseudotumor were considered in the differential. CSF sampling was non-diagnostic and cultures were negative. The patient was started empirically on high-dose methylprednisolone monthly and voriconazole, with significant symptomatic improvement. The patient underwent cyclophosphamide priming and proceeded to autologous bone marrow transplantation. Day 7 post-transplant his left eye pain recurred and head MRI showed abnormal

---

✉ E. L. Scharf  
scharf.eugene@mayo.edu

<sup>1</sup> Department of Neurology, Mayo Clinic, 200 First Street SW, Rochester, MN 55905, USA

enhancement at the apex along the left cavernous sinus. Over the following week, the patient's vision acutely deteriorated to light perception and repeat MRI of the face and orbit now showed narrowing of the left supraclinoid internal carotid artery. He was scheduled for craniotomy and biopsy of the mass lesion and his low molecular weight heparin was held in advance of his surgery. During the outpatient preoperative evaluation on the day prior to his biopsy, he was found to have acute onset fluctuating aphasia and right hemiparesis. He was transported to the emergency department and NIHSS in the emergency department was noted to be six. He underwent non-contrast head CT with angiography. There were no early signs of cerebral ischemia and CT angiography showed good arterial collateralization through the circle of Willis (Fig. 1a, b). On reconstructed images of CT angiography, the extent of the carotid occlusion appeared to involve the entire left carotid artery (Fig. 2a). He was not a candidate for intravenous thrombolysis because of use of heparin within the last 48 h and known intracranial mass. Platelet count was 91.

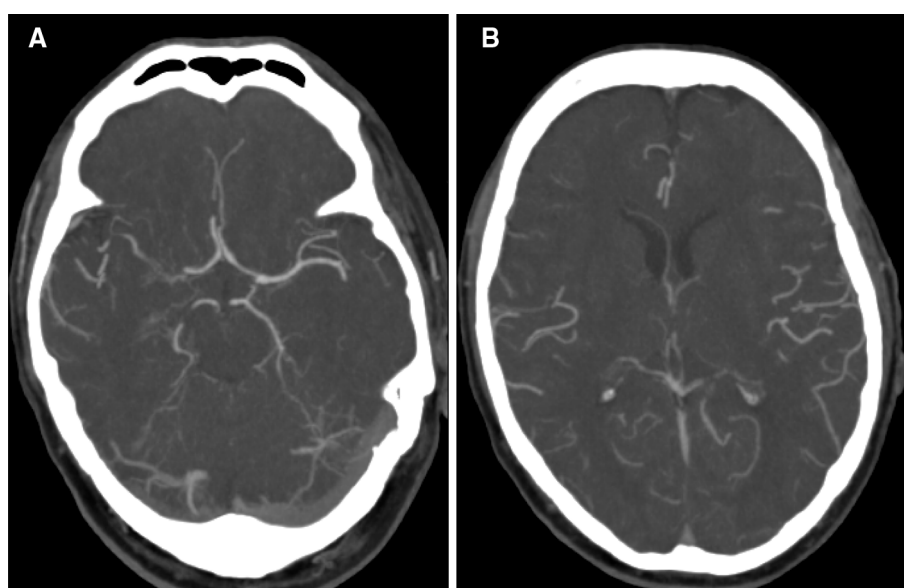
The patient was brought to the angiography suite approximately 3 h after onset of symptoms. Cerebral angiography showed an occlusion in the cavernous segment of the left internal carotid artery (Fig. 2b). A catheter could not be passed into the thrombosed segment which was noted to have a firm texture suggestive of tumor. A Solitaire device was deployed and retrieved across the occluded segment. Flow was briefly restored with persistent narrowing. A small amount of material was retrieved with a stent retriever and sent for pathological analysis. The carotid re-occluded and an enterprise stent was placed to prevent further re-occlusion. Followup left carotid

cerebral angiography after stent placement showed restoration of a small amount of flow but persistent marked narrowing, approximately 70 % (Fig. 3a, b). Post stent angioplasty was deferred as a compromise to respect the concern for vessel fragility and the risk of rupture secondary to the unknown mass. Given the patient's history of malignancy associated hypercoagulability, pulmonary embolism, and recent discontinuation of anticoagulation, post procedurally he was maintained on intravenous unfractionated heparin. He was treated with a loading dose of clopidogrel and aspirin the following morning. Subsequently, intravenous heparin was discontinued and he was maintained on dual antiplatelet therapy to minimize risk of stent thrombosis. Systolic blood pressure was kept below 160 mmHg. Post procedurally his aphasia improved but he had persistent left cranial nerve neuropathy, right facial weakness, and right paresis. Histopathological analysis of the luminal thrombus with silver stain and periodic acid–Schiff stain (Fig. 4) revealed non-septated and broad branching hyphae favoring *Zygomycetes* species. The patient was admitted to hospital and repeat head CT with thin slice sequencing through the sinuses showed a large mucosal enhancement now in the sphenoid sinus that was amenable to sphenoidotomy and biopsy. Fungal culture of this sample confirmed *Rhizomucor* species.

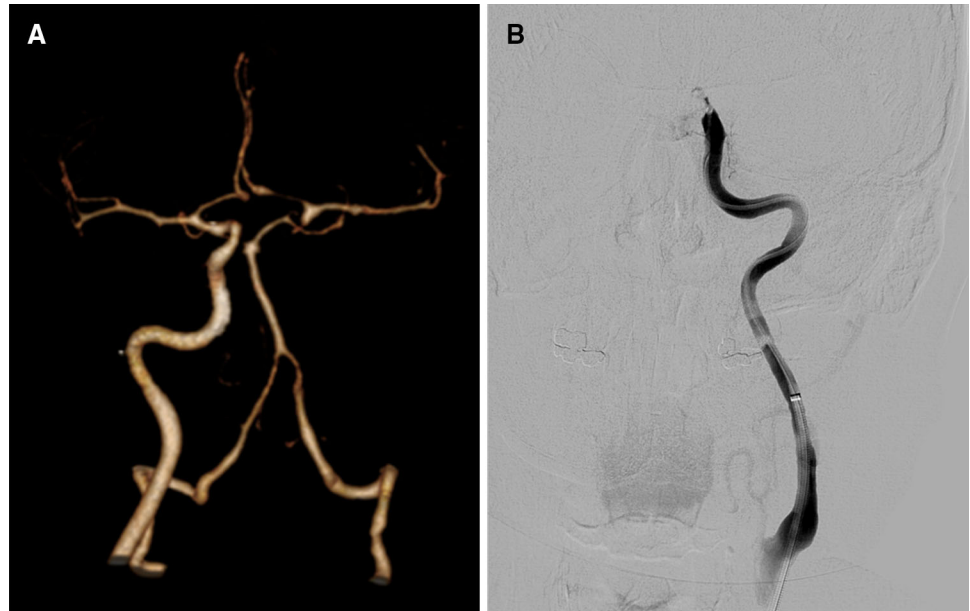
## Discussion

This case, the first to our knowledge, demonstrates the successful stenting of the cavernous segment of the internal carotid artery in the setting of an acute stroke secondary to an angioinvasive fungal infection. The source of the

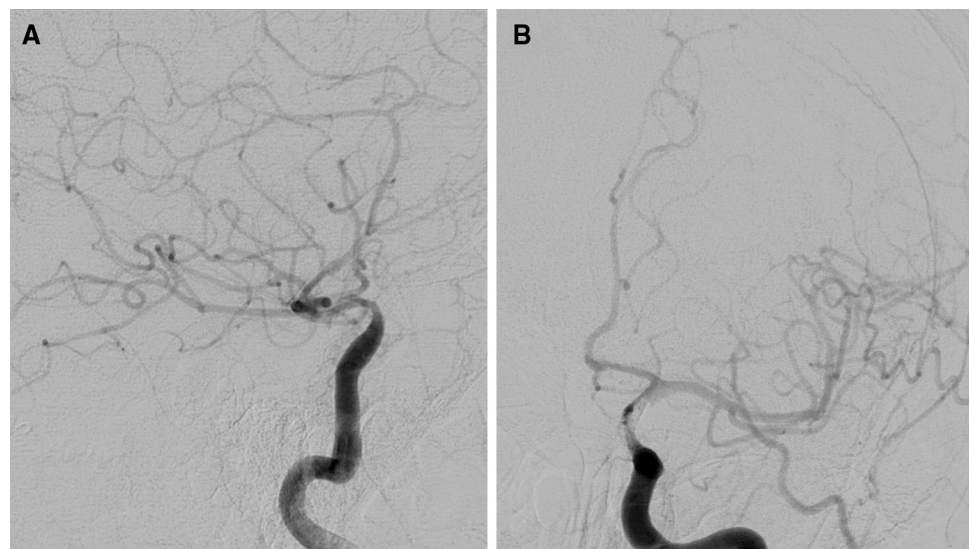
**Fig. 1** **a** Axial-computed tomographic angiography. Arterial collateralization is present through the circle of Willis filling the left middle cerebral artery. **b** Distal branches the left middle cerebral artery show comparable contrast enhancement in comparison to the non-occluded right middle cerebral artery suggesting adequate collateral flow



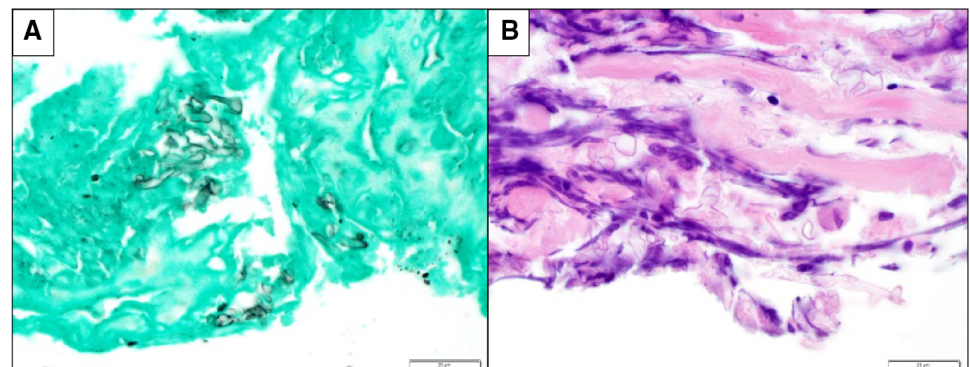
**Fig. 2** **a** Computed tomographic angiography 3-dimensional reformat suggests a total occlusion of the left carotid with collateral filling of the left middle cerebral artery. **b** Digital subtraction angiography completed an hour later shows a focal occlusion of the supraclinoid segment of the left internal carotid



**Fig. 3** Digital subtraction angiography of the left internal carotid artery shows recanalization but persistent stenosis of the supraclinoid segment of the left internal carotid. **a** Right anterior oblique view, **b** left anterior oblique view



**Fig. 4** Histopathological sample of acute thrombus. **a** Grocott's methenamine silver (GMS) shows darkly staining carbohydrate rich fungal cell walls,  $\times 1000$ . **b** Periodic acid-Schiff (PAS) staining shows broad widely branching non-septated hyphae suggestive of *Rhizopus* species,  $\times 1000$



thrombus was likely external compression and cavernous sinus invasion from the known intracranial mass. This is supported by the slowly progressive left cranial neuropathy and left monocular visual loss punctuated by sudden onset right hemiparesis and aphasia. It reasonable to consider proximal embolization from seeded cardiac valves secondary to disseminated fungemia; however, the patient had a normal transthoracic echocardiogram 3 months prior and negative blood cultures 2 months prior to his presentation of acute stroke.

There are several points to consider in this case. First, there was a discrepancy between the size of the carotid occlusion when comparing the images from the CT angiogram and the conventional cerebral angiogram. The reconstructed images of the CT angiogram suggest a total occlusion of the affected internal carotid artery. The actual occlusion found by digital subtraction angiography was focal within the ophthalmic segment. The discrepancy of this “pseudo-occlusion” results from significant delay in contrast uptake in the occluded vessel. A delayed CTA scan might have shown more contrast in distal segments of the occluded artery and more accurately reflected the true location of the occlusion and should be considered if conventional angiography is not available. This particular finding is clinically relevant because a longitudinally extensive total carotid occlusion would normally not be subject to endovascular intervention. Recognition of this potential radiological artifact is critical because it has implications for clinical management.

Second, this case supports recently published data [11–14] on the effectiveness of endovascular management of acute stroke. The patient presented with severe disabling focal neurological deficits and absolute contraindications to intravenous thrombolysis within 6 h of symptoms onset. Perfusion imaging to assess for ischemic penumbra was deferred in this case. This decision was justified because the initial head CT did not show a large region of ischemia, there was good collateral flow, perfusion imaging would have resulted in additional delay, and it would not have changed the clinical management. In this case, the head CT and angiography provided enough evidence to pursue endovascular management of acute stroke. Although the NIHSS was six, the patient was found to have an acute large vessel occlusion. The discrepancy between his clinical exam and radiographic findings underscores the importance of arterial collateralization in acute stroke. The degree of arterial collateralization present on CT angiography served well as a proxy for perfusion. Importantly, the CT angiogram showed patent anterior communicating collateral circulation of the left ACA and MCA. Thus, in a carotid occlusion with excellent collateral flow distally, the interventionalist must be cognizant of the risk of creating an embolic occlusion of an otherwise patent anterior

cerebral and middle cerebral arteries when manipulating the clot.

Finally, the nature of the thrombotic occlusion, a luminal invasion, and external compression from an aggressive fungus added significant complexity to the management. Intracranial arterial stenting was justified because of the persistent narrowing and re-occlusion of the affected artery. The results of the SAMMPRIS Trial [15] for endovascular intra-arterial stenting do not apply in this case because the patient would have been excluded for known progressive neurological signs within 24 h prior to enrollment, the patient had no known prior intracranial stenosis, the patient had a history of therapeutic anticoagulation, and most importantly the patient’s large vessel occlusion was secondary to an invading fungal mass and not intracranial atherosclerosis. Therefore, palliative stenting was appropriate based on plausible clinical reasoning. As a result of the stenting, the patient regained language function which had positive impact on his quality of life. Surgical debridement of the infection was not offered after review of the patient’s comorbidities and consideration of the intracranial extension of the infection. In consultation from an infectious disease specialist he received caspofungin which was discontinued secondary to liver toxicity. He was next treated with liposomal amphotericin which resulted in cytopenias and he became transfusion dependent. The patient discharged to hospice and died 1 month after hospital admission.

## References

1. Roden MM, Zaoutis TE, Buchanan WL, et al. Epidemiology and outcome of zygomycosis: a review of 929 reported cases. *Clin Infect Dis*. 2005;41:634–53.
2. Anand VK, Alemar G, Griswold JA Jr. Intracranial complications of mucormycosis: an experimental model and clinical review. *Laryngoscope*. 1992;102:656–62.
3. Al-Otaibi F, Albloushi M, Alhindi H, Timms MS. Carotid artery occlusion by rhinoorbitocerebral mucormycosis. *Case Rep Surg*. 2012. doi:10.1155/2012/812420.
4. Anaissie EJ, Shikhani AH. Rhinocerebral mucormycosis with internal carotid occlusion: report of two cases and review of the literature. *Laryngoscope*. 1985;95:1107–13.
5. Bae MS, Kim EJ, Lee KM, Choi WS. Rapidly progressive rhino-orbito-cerebral mucormycosis complicated with unilateral internal carotid artery occlusion: a case report. *Neurointervention*. 2012;7:45–9.
6. Delbrouck C, Jacobs F, Fernandez Aguilar S, Devroede B, Choufani G, Hassid S. Carotid artery occlusion due to fulminant rhinocerebral mucormycosis. *Acta Otorhinolaryngol Belg*. 2004;58:135–40.
7. Gelston CD, Durairaj VD, Simoes EA. Rhino-orbital mucormycosis causing cavernous sinus and internal carotid thrombosis treated with posaconazole. *Arch Ophthalmol*. 2007;125:848–9.
8. Simmons JH, Zeitler PS, Fenton LZ, Abzug MJ, Fiallo-Scharer RV, Klingensmith GJ. Rhinocerebral mucormycosis complicated by internal carotid artery thrombosis in a pediatric patient with

- type 1 diabetes mellitus: a case report and review of the literature. *Pediatr Diabetes*. 2005;6:234–8.
9. Song YM, Shin SY. Bilateral ophthalmic artery occlusion in rhino-orbito-cerebral mucormycosis. *Korean J Ophthalmol*. 2008;22:66–9.
  10. Ramanand Y, Sidhu TS, Jaswinder K, Sharma N. An atypical presentation of cavernous sinus thrombosis. *Indian J Otolaryngol Head Neck Surg*. 2007;59:163–5.
  11. Berkhemer OA, Fransen PS, Beumer D, et al. A randomized trial of intraarterial treatment for acute ischemic stroke. *N Engl J Med*. 2015;372:11–20.
  12. Goyal M, Demchuk AM, Menon BK, et al. Randomized assessment of rapid endovascular treatment of ischemic stroke. *N Engl J Med*. 2015;372:1019–30.
  13. Saver JL, Goyal M, Bonafe A, et al. Stent-retriever thrombectomy after intravenous t-PA vs. t-PA alone in stroke. *N Engl J Med*. 2015;372:2285–95.
  14. Campbell BC, Mitchell PJ, Kleinig TJ, et al. Endovascular therapy for ischemic stroke with perfusion-imaging selection. *N Engl J Med*. 2015;372:1009–18.
  15. Chimowitz MI, Lynn MJ, Derdeyn CP, et al. Stenting versus aggressive medical therapy for intracranial arterial stenosis. *N Engl J Med*. 2011;365:993–1003.