


# Accepted Manuscript

Surgical Management of Giant Intracranial Arteriovenous Malformations: A Single Center Experience over 32 years

Kevin A. Reinard, MD, Aqueel H. Pabaney, MD, Azam Basheer, MD, Scott B. Phillips, MD, Max K. Kole, MD, Ghaus M. Malik, MD



PII: S1878-8750(15)00921-3

DOI: [10.1016/j.wneu.2015.07.051](https://doi.org/10.1016/j.wneu.2015.07.051)

Reference: WNEU 3079

To appear in: *World Neurosurgery*

Received Date: 21 January 2015

Revised Date: 20 July 2015

Accepted Date: 20 July 2015

Please cite this article as: Reinard KA, Pabaney AH, Basheer A, Phillips SB, Kole MK, Malik GM, Surgical Management of Giant Intracranial Arteriovenous Malformations: A Single Center Experience over 32 years, *World Neurosurgery* (2015), doi: 10.1016/j.wneu.2015.07.051.

This is a PDF file of an unedited manuscript that has been accepted for publication. As a service to our customers we are providing this early version of the manuscript. The manuscript will undergo copyediting, typesetting, and review of the resulting proof before it is published in its final form. Please note that during the production process errors may be discovered which could affect the content, and all legal disclaimers that apply to the journal pertain.

**Highlights**

- Lack of unified guidelines make treatment of gAVMs a difficult undertaking
- Surgery will continue to play an important role in the management of gAVMs
- Complications related to treating select gAVMs may be lower than reported in ARUBA
- Advanced, multimodal therapeutic approaches can reduce gAVM-related mortality

**Surgical Management of Giant Intracranial Arteriovenous Malformations:****A Single Center Experience over 32 years**

Kevin A. Reinard, MD,<sup>1</sup> Aqueel H. Pabaney, MD,<sup>1</sup> Azam Basheer, MD,<sup>1</sup> Scott B.

Phillips, MD,<sup>2</sup> Max K. Kole, MD,<sup>1</sup> Ghaus M. Malik, MD<sup>1</sup>

From the <sup>1</sup>Department of Neurosurgery, Henry Ford Hospital, Detroit, Michigan, USA;

<sup>2</sup>Division of Neurological Surgery, Brooks Army Medical Center, San Antonio, Texas,

USA

**Address correspondence and reprint requests to:**

Aqueel H. Pabaney, MD

Department of Neurosurgery, K-11

Henry Ford Hospital

2799 W. Grand Blvd

Detroit, Michigan 48202

Phone: 313-916-1094

Fax: 313-916-7139

Email: apabane1@hfhs.org

Key Words: Embolization; giant intracranial arteriovenous malformations (gAVMs);

hemorrhage; management; microsurgery

Running Title: Surgical management of gAVMs

**Abstract**

*Objective:* Treatment of giant intracranial arteriovenous malformations (gAVMs) is a formidable challenge for neurosurgeons and carries significant morbidity and mortality rates compared to smaller AVMs. In this study, we reviewed the treatments, angiographic results, and clinical outcomes in 64 patients with gAVMs who were treated at Henry Ford Hospital between 1980 and 2012.

*Methods:* The AVM database at our institution was queried for patients with gAVMs ( $\geq 6$  cm) and data regarding patient demographics, presentation, AVM angioarchitecture, and treatments were collected. Functional outcomes as well as complications were analyzed.

*Results:* Of the 64 patients, 33 (51.6%) were female and 31 (48.4%) were male, with an average age of 45.7 years ( $SD \pm 15.5$ ). The most common symptoms on presentation were headaches (50%), seizures (50%), and hemorrhage (41%). The mean AVM size was 6.65 cm (range, 6 to 9 cm). Only 6 AVMs (9.4%) were located in the posterior fossa. The most common Spetzler-Martin (SM) grade was V, seen in 64% of patients. Of the 64 patients 42 (66%) underwent surgical excision, 10 (15.5%) declined any treatment, 8 (12.5%) were deemed inoperable and followed conservatively, 2 (3%) had stand-alone embolization, 1 (1.5%) had embolization prior to stereotactic radiosurgery (SRS), and 1 (1.5%) received SRS only. Complete obliteration was achieved in 90% of the surgical patients. Mortality rate was 19% in the surgical cohort as compared to 22% in the observation cohort ( $p = 0.770$ ).

*Conclusion:* Treatment of gAVMs carries significant morbidity and mortality; however, good outcomes are attainable with a multimodal treatment approach in carefully selected patients.

## INTRODUCTION

Intracranial arteriovenous malformations (AVMs) are one of the most challenging pathologies encountered by cerebrovascular surgeons (1). Management of AVMs is a daunting task as multiple variables such as patient demographics and presentation, neurological status, angioarchitecture of the AVM (arterial feeders, nidus size, venous drainage, associated aneurysms or varices), availability of multimodality resources, expertise of the surgeon or endovascular specialist, and most importantly patient desires must be taken into consideration for any effective treatment algorithm. The optimal treatment strategy for cerebral AVMs remains controversial (2), especially in light of recent findings from the first randomized trial of unruptured AVMs (ARUBA [A Randomized trial of Unruptured Brain AVMs]) (3). The results of this trial may change the accepted treatment paradigm and challenge the premise that unruptured AVMs should even be treated (4).

Microsurgery continues to play a role, albeit controversial, in the treatment of AVMs despite remarkable advances in radiosurgery and endovascular techniques (5–12). By definition giant AVMs (gAVMs) measure at least 6 cm in diameter and are categorized, at minimum, as Spetzler-Martin grade III lesions (13). They typically have high-flow, deep venous drainage, and extend into eloquent areas and as a result are associated with higher rates of postoperative complications even in young, healthy patients (14,15). Although endovascular embolization of gAVMs serves as a useful adjunct (16), complete cure is achieved infrequently and may have to be supplemented with surgical excision or radiosurgery (9,17–19).

In this paper, we report the senior author's (G.M.M.) experience with 64 patients **harboring** gAVMs and outcomes over a span of 32 years.

## **METHODS**

In accordance with the Henry Ford Hospital Institutional Review Board (**IRB #8179**), we searched our AVM database from 1980 to 2012 and identified 64 patients with gAVMs who were evaluated and treated at our institution. In all patients, gAVMs were diagnosed as nidus size greater than 6 cm on the basis of available magnetic resonance imaging (MRI) studies as well as mid-arterial phase digital subtraction angiography (DSA). Electronic medical records were searched to gather patient demographic data including age, gender, symptoms on presentation, and presence or absence of intracerebral hemorrhage (ICH) on computed tomography (CT) scan. We also collected information about the location of the AVM nidus, arterial feeders and venous drainage, as well as the presence of flow-related aneurysms (feeding artery, intranidal, or venous). Spetzler – Martin (SM) grading scale (20) was applied to all patients to assess surgical risk. Patients underwent 6-vessel cerebral angiography post-treatment, and the results were examined to assess obliteration status at the end of treatment. Medical records were screened to assess patients' functional status prior to treatment, immediately post treatment, and later in the follow-up period. A modified Rankin score (mRS) was assigned for each interval, and the duration of follow-up was noted.

For statistical analyses, Chi-square tests were performed to assess the association between clinical variables and treatment options rendered and functional outcomes.

Furthermore, we performed a survival analysis. All testing was done at 0.05 level using SAS version 9.4.

## RESULTS

Our institutional review revealed 64 patients evaluated for gAVMs between 1980 and 2012 (**Table 1**), with an average age of 45.7 years ( $\pm 15.5$ ). There were 33 (51.6%) female and 31 (48.4%) male patients. The most common presenting symptoms were headaches (32/64, 50%), seizures (32/64, 50%), followed by hemorrhage (26/64, 41%), diplopia (2/64, 3%), ataxia (1/64, 1.6%), tinnitus (1/64, 1.6%), and altered mental status (1/64, 1.6%). In our series, the AVM was located in the left cerebral hemisphere in 26 patients (40.6%), in the right cerebral hemisphere in 32 (50%) patients, and in the cerebellar hemispheres in 6 (9.4%) patients. Of the 58 AVMs (91%) located in the supratentorial compartment, 19 (33%) were fronto-parietal, 11 (19%) were parieto-occipital, 7 (12%) were parieto-temporal, 5 were purely frontal, 4 were fronto-temporal, 3 were purely temporal, 2 were purely parietal, 2 were located in the Sylvian fissure, 2 were in the corpus callosum, 1 was located in the occipital lobe, 1 was temporal-occipital, and 1 was confined to the basal ganglia (**Table 2**). Only 3 (4.7%) patients had a single arterial territory feeder. Eighteen (28%) patients had flow-related aneurysms while 8 (12.5%) had venous aneurysms. The average size of the AVM nidus was 6.65 cm (range 6.0 – 9.0 cm). Of the 64 gAVMs, only 1 (1.6%) was classified as SM grade III, 22 (34.4%) as SM grade IV, and the majority as SM grade V (41, 64%). Of the 6 (9.4%) cerebellar lesions, half were located in the cerebellar hemispheres and half were located in the vermis; the majority of the posterior fossa gAVMs (67%) included the deep cerebellar nuclei.

Twenty-six (41%) patients underwent surgical resection without prior embolization, whereas 16 (25%) underwent microsurgical extirpation after partial embolization of their gAVM. Overall, 42 (66%) patients underwent microsurgical excision. Two (3%) patients were treated with embolization only. Stereotactic radiosurgery (SRS) was performed on two patients (3%), one of which underwent pre-SRS embolization. Ten patients (15.6%) declined any treatment and we elected to observe the eight patients (12.5%) with inoperable lesions (i.e. basal ganglia involvement, large bilateral lesions involving the corpus callosum, and arterial supply from deep perforators). Except for the seven patients (11%) who died while hospitalized, all patients underwent postoperative cerebral angiogram to assess AVM obliteration status. Follow-up angiograms were not performed in patients who did not receive treatment either because they harbored inoperable lesions or because they opted for medical management (18 patients total, 28%). Of the 39 patients who had a postoperative angiogram, 35 had complete obliteration of their gAVM (90%) and only 4 (10%) had partial obliteration with residual AV shunting. Of the 4 patients with incomplete obliteration, 2 had received SRS, 1 received stand-alone embolization, and 1 underwent microsurgical resection. Only 1 patient out of the 42 who had surgical resection (2.4%) had residual AV shunting on postoperative angiogram.

Patients were followed-up for a mean of 73.73 months ( $\pm 98.25$ ). On presentation, the mRS of the entire cohort was as follows: 1 (1.5%) patient had mRS of 0, 27 (42%) had mRS of 1, 19 (30%) had mRS of 2, 17 (26.5%) had mRS of 3, and no patients had mRS of 4-5. At the earliest follow-up (< 3 months after initial encounter), the mRS of all patients, irrespective of whether they received treatment or not, changed to the following:



no patients had mRS of 0, 5 (8%) had mRS of 1, 15 (23%) had mRS of 2, 19 (30%) had mRS of 3, 13 (20%) had mRS of 4, 3 (5%) had mRS of 5, and 9 (14%) had mRS of 6 (died). At long-term follow-up (> 3 months after initial encounter), 4 additional patients had died and the mRS of the remaining cohort was as follows: 3 (5%) patients had mRS of 0, 5 (8%) had mRS of 1, 11 (17%) had mRS of 2, 17 (26%) had mRS of 3, 3 (5%) had mRS of 4, and 2 (3%) had mRS of 5. Ten patients (15%) were lost to follow-up (**Figure 1**). Four (22%) of the patients who did not receive any treatment died as compared to 9 (19.6%) who underwent either microsurgical resection (8 patients) or stand-alone embolization (1 patient). Overall mortality rate was 20% (**Table 3**).

To assess whether the advent of new endovascular micro-catheters or liquid embolic agents had an impact on our patient outcomes, we divided our series into *early* (1980 – 2000) and *late* (2000 – 2012) surgical groups. Thirty (71.4%) patients underwent surgery prior to 2000, while 12 (28.6%) had microsurgical resection after 2000. Within the *early* cohort, 25 (83.3%) patients had surgery without embolization and 5 (16.7%) had preoperative embolization. In contrast, 11 (92%) patients in the *late* cohort had preoperative embolization with only 1 (8%) undergoing surgery without prior embolization. Overall, only 4 (13.3%) patients had good outcomes (mRS  $\leq$  2) (21) in the *early* group at long-term (> 3 months) follow-up. Good outcomes improved to 58.3% in the *late* group at long-term follow-up ( $p < 0.001$ ). Comparison of the *early* and *late* surgical groups also revealed that poor outcomes (mRS > 3) (22) declined significantly in our series from 86.7% before 2000 to 41.7% after 2000 ( $p < 0.001$ ) (**Figure 2**).

To better elucidate whether the surgical group exhibited a different survival pattern at different time intervals as compared to the observation group, we also

performed a survival analysis using Kaplan-Meier methods. For the surgical group, four patients died within 30 days of treatment and 1 died between 1 and 2 months post treatment. The 1, 5, and 10 year overall survival rates for patients with surgery were 89%, 72%, and 63% respectively while for patients without surgery the rates were 88%, 80%, and 66%. The difference in overall survival rates was not significant ( $p = 0.330$ , log-rank test) (**Figure 3**).

### ILLUSTRATIVE CASES

*Case 5:* A 20-year-old, right-handed male presented to our emergency department with acute onset headaches, speech difficulty, and weakness. On examination, he was awake, dysphasic, and had right hemiparesis with strength of 2/5 on the Medical Research Council (MRC) scale (23). Initial head CT revealed intraventricular hemorrhage (IVH) and minimal subarachnoid hemorrhage (SAH) (**Figure 4A**). An external ventricular drain (EVD) was placed. Cerebral angiography revealed a 7.4 cm, left parietal gAVM involving the motor and premotor areas (**Figure 4B**). The arterial supply to the gAVM was from branches of the left middle cerebral artery (MCA) and the anterior cerebral artery (ACA). The venous drainage was superficial to both the transverse and superior sagittal sinuses as well as deep into the vein of Galen (SM grade V). Preoperative embolization was performed over three different sessions using N-butylcyanoacrylate (NBCA), which led to a moderate reduction in the AVM's size (**Figure 4C**). The patient was taken to the operating room several days after the last embolization session for microsurgical extirpation of the gAVM (**Figure 4D**). Postoperative angiography revealed complete AVM resection with no evidence of arteriovenous shunting (**Figure 4E**). In the

recovery phase, the patient had slight improvement of his right hemiparesis and near complete resolution of his dysphasia. He developed postoperative seizures that were well controlled with one medication. At his last office visit seven years after surgery, he had completed a college degree and was able to drive independently.

*Case 20:* A 23-year-old, right-handed male presented to our emergency department after he was found unconscious following an episode of visual flashes suggestive of a seizure. Neurological examination was unremarkable. Initial imaging studies revealed a right temporal-occipital gAVM with no evidence of hemorrhage (**Figure 5A**). Cerebral angiography confirmed a 7-cm right temporal gAVM. Arterial feeders arose from the MCA and the posterior cerebral artery (PCA). The venous drainage was superficial through veins of Labbé and Trolard and deep through the basal vein of Rosenthal (SM IV) (**Figure 5B and 5C**). The patient underwent staged preoperative embolization and arterial feeders from the MCA and the PCA were successfully occluded using Onyx-18 and Onyx-34. Postembolization angiogram continued to show vigorous filling of the AVM (**Figure 5D**). He was then taken to the operating room for surgical removal of the gAVM. Microsurgical dissection was initiated at the superior margin of the AVM just below the Sylvian fissure and continued circumferentially around the gliotic margin until the entire AVM was excised. Postoperative angiogram revealed complete resection of the AVM (**Figure 5E**). Following his treatment, the patient developed a left superior quadrantonopsia; however, he became seizure-free. At the last follow-up visit, three years following surgery, his visual field defect had persisted but did not influence his daily functioning.

*Case 37:* A 42-year-old male was referred to our department in the mid-1980s after imaging performed for persistent headaches and a new onset left hemiparesis revealed a ruptured AVM (**Figure 6A**). Neurological examination revealed right-sided hemiparesis, 3/5 on MRC scale. Cerebral angiogram demonstrated an 8-cm, right frontal-parietal-occipital gAVM with arterial feeders from the ACA, MCA, and PCA as well as perforating branches of the right anterior choroidal (ACh) and lenticulostriate arteries (LSt). Contralateral ACA and LSt also supplied blood to the AVM. Venous drainage was both superficial and deep with an associated large venous aneurysm (SM V) (**Figure 6B-E**). Without preoperative embolization, the patient underwent microsurgical resection. Intraoperatively, severe bleeding was encountered from the deep perforating vessels that retracted into the white matter. Commando resection of AVM was performed (24). The patient suffered from recurrent ICH in the postoperative unit, possibly secondary to consumptive coagulopathy, and died a few days later.

*Case 13:* A 28-year-old right-handed male presented initially to his primary care physician with complaints of right temporal headaches and progressive left-sided weakness for 2 years. On examination he was found to have mild left hemiparesis, 4/5 on the MRC scale. MRI of the brain revealed minimal SAH and a gAVM with diffuse nidus (approximately 6 cm) in the right basal nuclei, internal capsule, and insular cortex with mass effect on the ipsilateral ventricle (**Figure 7A and 7B**). Cerebral angiography revealed an arterial supply primarily from the LSt, the ACA, and the MCA (SM V) (**Figure 7C**). Given the eloquent location and the diffuse angioarchitecture of the AVM, no treatment was offered. At his last follow-up visit 3 months after the initial diagnosis, the patient continued to have headaches with stable left hemiparesis.

## DISCUSSION

The incidence of AVMs is 1-1.4 cases per 100,000 persons with an overall annual rate of hemorrhage that is approximately 2% to 4% in untreated patients (25). Recent, large-scale, pooled analyses have corroborated these findings and estimated the annual hemorrhage rate to be 3% (26). Female sex, advanced age, subcortical location, prior rupture history, deep venous drainage, and association with intracranial aneurysms are independent risk factors that could increase the risk of hemorrhage (26–28). While headache, focal neurologic deficits, and seizure activity are common presenting symptoms, nearly 50% of all AVMs result in hemorrhages that cause permanent neurologic morbidity and mortality in 30% of the adult population (11).

AVMs with nidus measuring 6 cm or more in maximum diameter are considered *giant* AVMs (13). By virtue of size alone these are classified according to the Spetzler-Martin (SM) grading scale as grade III or higher and because most harbor deep venous drainage and are proximal to eloquent structures, they may be considered formidable and “inoperable” lesions by even experienced neurosurgeons (29).

Only a few reports have focused on the natural history of gAVMs exclusively because these lesions are most commonly presented as a small subset in larger case series (25,26,30,31). Therefore, the natural history of gAVMs remains unclear and is further confounded by conflicting evidence regarding AVM size and relative risk of hemorrhage. Fulst and Kelly found no correlation between AVM size and risk of hemorrhage (32). Crawford et al followed 217 unruptured AVMs and reached the same conclusion (33). Zhao and colleagues found an annual hemorrhage rate of 1.4% in 40 patients with

gAVMs (34). In a retrospective cohort of 73 patients with SM grade IV and V AVMs, Han et al noted a 1.5% hemorrhage rate (35). Stefani and colleagues in Toronto prospectively followed 390 patients with *large* AVMs for an average of 3.1 years and concluded that large AVMs bleed more frequently than small lesions (Odds Ratio, OR 2.5) (36). Hernesniemi et al. reported an annual hemorrhage rate of 3.5% for AVMs larger than 5 cm (37) and Laakso et al reported an annual hemorrhage rate of 3.3% in a cohort of 63 patients who harbored SM IV and V AVMs (38). Other studies have suggested that the rate of hemorrhage in unruptured gAVMs is approximately 10% to 20% in the first five years and the rate of rupture could increase dramatically to 50% after 20 years (33,34,37,39).

Because of the foregoing, and in conjunction with the absence of evidence-based guidelines, the management of gAVMs remains a controversial and formidable challenge that is best undertaken with caution and at neurovascular centers with multimodal capabilities dedicated specifically to the treatment of gAVMs. At our institution, every patient harboring a giant vascular malformation is presented to a panel of cerebrovascular surgeons, endovascular specialists, neuro-interventionalists, and stroke neurologists at a weekly vascular conference. It has generally been our practice to consider patients with significant hemorrhage, progressive neurological deficits, intractable seizures or headaches, hemodynamic steal phenomenon, large pre- or intra-nidal aneurysms, or venous outflow restrictions for intervention. After taking into consideration each patient's desire and only if the vascular board has rendered a consensus opinion for treatment do we go ahead with intervention. Since pre-operative embolization has

significantly improved our outcomes, all patients considered for microsurgical resection undergo pre-operative embolization.

Microsurgical resection, in select cases, can offer durable and high cure rates with immediate elimination of future hemorrhage risk (5,34,40). Preoperative endovascular embolization using particle or liquid embolic materials may potentially make surgical excision of these AVMs less daunting by reducing operative time and decreasing blood loss (10,41). However, endovascular interventions can rarely treat gAVMs completely and must be followed by surgical extirpation or radiosurgery (9,34). The goal of managing AVMs should always be complete obliteration regardless of the AVM grade, because partially treated AVMs present a substantially higher risk of hemorrhage (35,42,43).

Several authors have reported their experience with the surgical management of gAVMs. Spetzler and Martin reported a series of 20 patients with gAVMs managed with staged embolization and surgical resection. Complete excision was accomplished in 18 of these patients (44). Han et al., however, in a series of 73 patients with SM IV and V AVMs had an overall hemorrhage rate of 1.5% per year. Their final recommendation was that high-grade AVMs should be followed expectantly (35). In a series of 90 patients Hernesniemi et al. reported on 15 patients with AVMs greater than 5 cm in diameter (44). Of these patients, 5 had excellent outcomes, 6 had moderate disabilities, 1 had a severe disability, 1 died, and 2 were lost to follow-up (45). Chang and Steinberg presented their cohort of 53 patients harboring gAVMs that were treated with surgery, embolization and radiosurgery. About 70% of their patients were cured but morbidity and mortality rates reached 30% (31). Recently, Zhao and colleagues reported surgical outcomes for 40

patients with gAVMs. Half of the patients developed complications in the immediate postoperative period, 23.3% had a neurological deficit at last follow-up, and 10% of the patients died (34).

Endovascular techniques have proved valuable adjuncts in the management of cerebral AVMs. Successful embolization can partially occlude the AVM and make possible the surgical resection of an otherwise inoperable lesion (10,41). Associated aneurysms can also be occluded by endovascular means prior to addressing the AVM surgically (46). Additionally, radiosurgery following AVM embolization has been successfully undertaken for the treatment of large AVMs with reasonable success (19). However, despite significant advances, endovascular interventions can rarely achieve complete AVM obliteration and may need to be supplemented with surgery or radiation. According to a recent meta-analysis, morbidity and mortality related to endovascular procedures for definitive AVM treatment occurred in 6.6% of patients (range, 0%–28%) (47).

Radiation therapy, in the form of radiosurgery and hypofractionated radiotherapy, has also played a significant role in the treatment of AVMs. Single-fraction SRS has proven effective in treating AVMs with nidus volumes less than 14 cm<sup>3</sup> or 3 cm in diameter, with complete occlusion rates reported at 72% to 96% (48–51); however, larger lesions have resulted in lukewarm results (52–54). Several studies have demonstrated that both non-obliteration and complication rates rise when AVMs exceed 10 cm<sup>3</sup>. Pan et al. followed 240 patients with AVMs treated by gamma knife radiosurgery and found that only 25% of patients with large AVMs ( $\geq 15$  cm<sup>3</sup>) were cured with single-dose SRS. When treatment of large lesions was compared to that of smaller lesions,



patients with larger lesions suffered more adverse radiological effects including permanent neurological deficits (55). Hypofractionated stereotactic radiotherapy (HSRT), 4-7 Gy/fraction for 4-6 weeks for a total of 28-42 Gy, has also been utilized for treatment of inoperable gAVMs that cannot be effectively and safely treated with single-fraction SRS. Comparison of radiographic outcomes between SRS and HSRT has shown no inferiority of AVM obliteration rate with HSRT (56). More recently, Lawton and colleagues reported their experience with 16 patients harboring high-grade AVMs that were treated with volume-staged radiosurgery for downsizing the AVM followed by microsurgical excision. They were able to cure 93.8% of patients with 19% morbidity and mortality (57). Endovascular embolization followed by SRS has also been used for medium and large size AVMs (19). The premise behind the use of pre-radiosurgical embolization is to reduce the effective size of AVM nidus and make it more manageable for radiosurgery. Unfortunately, several studies have shown that overall outcomes as well as obliteration rates are worse in patients undergoing embolization prior to radiosurgery (58). Plausible explanations for this paradox are the possibility that radio-opaque materials may scatter radiation and result in decreased radiation absorption by the nidus vessels, and that the altered flow dynamics may not only increase the difficulty of planning for radiosurgery but also the rates of hemorrhage following embolization. Interestingly, however, Veznedaroglu et al. reported increased rates of obliteration in patients with large AVMs undergoing embolization prior to fractionated stereotactic radiotherapy (59). Because of the senior author's (G.M.M.) experience with microsurgical resection of AVMs, our institution has not been a major referral center for radiosurgical treatment of AVMs, and this is evidenced by the two patients who

underwent SRS in our series. As a result, we cannot effectively make conclusions about the impact of radiation therapy on our patients with gAVMs.

Although the cohort presented in this report comprises 64 patients only, careful analysis of our findings could provide important lessons. *First*, the gAVMs in our series most commonly involved the frontal, parietal, and occipital lobes, which has important implications (**Table 2**). Regardless of the laterality of the AVM, resection of gAVMs from the parietal lobe will invariably lead to motor, visual, or neuropsychological deficits unlike lesions located purely in the frontal lobe, and this fact should be discussed at length with the patient prior to beginning any treatment. As seen in **Figure 1**, the functional independence of several patients declined after treatment, reflecting the high risk associated with any treatment of AVMs, especially with high-grade lesions, a fact that is corroborated by other reports (60) and may push the clinician to consider alternatives to microsurgery such as SRS (61). *Second*, complete obliteration rates did not differ significantly between supratentorial AVMs of various SM grading. In contrast, the lowest complete obliteration rates in our series were observed in lesions located in the cerebellum (**Table 4**). Nearly 70% of patients harboring posterior fossa gAVMs presented with ICH. Three of the patients with posterior fossa gAVMs (50%) died after intervention as compared to the only 6 patients (10%) with supratentorial gAVMs who died after any intervention. It is also important to note that five patients (83.3%) with infratentorial gAVMs had poor outcomes ( $mRS \geq 3$ ) underscoring that the posterior fossa AVMs may have a more ominous natural history (62) as compared to their supratentorial counterparts and, perhaps, should be considered as an entirely separate entity. *Third*, the rates of complete obliteration were highest when a combination of preoperative

embolization and microsurgical excision was utilized to treat AVMs (**Table 5**). Complete obliteration was achieved in 94% of cases when embolization preceded surgery. This rate dropped to 77% when preoperative embolization was not utilized prior to surgery. More importantly, none of the patients who underwent stand-alone embolization or SRS exclusively (or any combination of these two modalities) achieved complete AVM obliteration. Therefore, microsurgery should be considered a viable option if multimodal treatment is entertained and complete cure is the objective. *Fourth*, of the 46 patients who received any mode of therapy (42 microsurgery, 1 SRS, 1 embolization + SRS, and 2 embolization only), 7 (16.7%) died due to complications related to ICH. Mortality rate was 19% for patients who underwent microsurgical resection with or without adjunctive embolization. In contrast, of the 18 patients who did not receive any treatment (8 deemed inoperable, 10 declined any treatment), 4 (22.2%) died as a result of ICH. Our overall mortality rate of 20% is higher than what has been reported in the past by Zhao et al (10.2%) and Chang et al (15%) (31,34). Although the difference in mortality between the treatment and observation groups is not significant (19.6% vs. 22.2%,  $p = 0.810$ ), our observed rate of stroke or death among treated patients was lower than reported in ARUBA and other recent reports questioning intervention for AVMs (3,4). *Fifth*, while endovascular technique have been invaluable adjuncts in the diagnosis and treatment of AVMs since the 1960s (41), advances in catheter angiography as well as liquid embolic agents (Onyx) in the late 1990s and early 2000s revolutionized the treatment of AVMs and ushered in a new era of treatment (41,63). As our experience with microsurgical treatment of AVMs increased, the addition of new micro-catheters and liquid embolic agents augmented our outcomes while simultaneously lowering our overall morbidity and

mortality. This is evidenced by a reduction in our poor outcomes ( $mRS \geq 3$ ) from 86.7% before 2000 to 41.7% after 2000 ( $p < 0.002$ ). Nowadays, all patients considered for surgical obliteration of AVMs routinely undergo catheter angiography with intent to eliminate arterial pedicles and possibly reduce AVM nidus prior to definitive operative intervention. And *sixth*, our survival analysis confirms that microsurgical resection of gAVMs in carefully selected patients does not reduce survival rate by transferring additional harm to patients. Our analysis demonstrates that not all giant AVMs are created equal and, therefore, should not automatically be dismissed as “inoperable” lesions. Rather, healthy young patients with high lifetime risks of rupture should be considered for microsurgical resection of their gAVM with pre-operative embolization because it may offer them a legitimate chance of cure.

It is important to acknowledge several key limitations of our study. We realize that retrospective analyses are fraught with inherent biases such as sampling bias. Because many patients in our analysis received their care prior to 1994 when electronic medical records were implemented at Henry Ford Hospital, information used to calculate mRS for many patients was limited and we had no choice but to rely on telephone conversations with patients or family members to assess functional outcomes. While recent reports have shown mRS scores applied by telephone to be reliable (64), others have questioned the interobserver reliability of mRS in stroke patients altogether (65). We also understand that results from a subset of patients should not be generalized to a larger population. Rigorous meta-analyses are required to reach evidentiary conclusions regarding treatment of high-grade AVMs because randomized controlled trials may not

be ethically feasible. We hope that our results will further our understanding of these complex lesions and help guide the future management of gAVMs.

## **CONCLUSION**

An ongoing challenge for cerebrovascular surgeons will be the development of a management algorithm for patients with giant AVMs that will ensure durable and complete obliteration rates while minimizing patient morbidity. Advances in radiation and endovascular therapy bring hope that new treatment paradigms will emerge, enabling physicians to treat these complicated lesions with uniformity. Until then, decisions on whether to treat giant AVMs should be made on an individual basis and at dedicated cerebrovascular centers with multidisciplinary resources at their disposal including microsurgery.

**REFERENCES**

1. Peschillo S, Caporlingua A, Colonnese C, Guidetti G: Brain AVMs: An endovascular, surgical, and radiosurgical update. *Sci World J* 2014:834931, 2014.
2. Ajiboye N, Chalouhi N, Starke RM, Zanaty M, Bell R: Cerebral arteriovenous malformations: evaluation and management. *Sci World J* 2014:649036, 2014.
3. Mohr JP, Parides MK, Stapf C, Moquete E, Moy CS, Overbey JR, Al-Shahi Salman R, Vicaut E, Young WL, Houdart E, Cordonnier C, Stefani MA, Hartmann A, von Kummer R, Biondi A, Berkefeld J, Klijn CJM, Harkness K, Libman R, Barreau X, Moskowitz AJ, international ARUBA investigators: Medical management with or without interventional therapy for unruptured brain arteriovenous malformations (ARUBA): a multicentre, non-blinded, randomised trial. *Lancet* 383(9917):614–621, 2014.
4. Al-Shahi Salman R, White PM, Counsell CE, du Plessis J, van Beijnum J, Josephson CB, Wilkinson T, Wedderburn CJ, Chandy Z, St George EJ, Sellar RJ, Warlow CP, Scottish Audit of Intracranial Vascular Malformations Collaborators: Outcome after conservative management or intervention for unruptured brain arteriovenous malformations. *JAMA* 311(16):1661–1669, 2014.
5. Theofanis T, Chalouhi N, Dalyai R, Starke RM, Jabbour P, Rosenwasser RH, Tjoumakaris S: Microsurgery for cerebral arteriovenous malformations: postoperative outcomes and predictors of complications in 264 cases. *Neurosurg Focus* 37(3):E10, 2014.

6. Zhao J, Wang S, Li J, Qi W, Sui D, Zhao Y: Clinical characteristics and surgical results of patients with cerebral arteriovenous malformations. *Surg Neurol* 63(2):156–161; discussion 161, 2005.
7. Korja M, Bervini D, Assaad N, Morgan MK: Role of surgery in the management of brain arteriovenous malformations: prospective cohort study. *Stroke J Cereb Circ* 45(12):3549–3555, 2014.
8. Bervini D, Morgan MK, Ritson EA, Heller G: Surgery for unruptured arteriovenous malformations of the brain is better than conservative management for selected cases: A prospective cohort study. *Neurochirurgie* 60(6):327, 2014.
9. Bendok BR, El Tecle NE, El Ahmadieh TY, Koht A, Gallagher TA, Carroll TJ, Markl M, Sabbagha R, Sabbagha A, Cella D, Nowinski C, Dewald JPA, Meade TJ, Samson D, Batjer HH: Advances and innovations in brain arteriovenous malformation surgery. *Neurosurgery* 74 Suppl 1:S60–S73, 2014.
10. Crowley RW, Ducruet AF, McDougall CG, Albuquerque FC: Endovascular advances for brain arteriovenous malformations. *Neurosurgery* 74 Suppl 1:S74–S82, 2014.
11. Rubin BA, Brunswick A, Riina H, Kondziolka D: Advances in radiosurgery for arteriovenous malformations of the brain. *Neurosurgery* 74 (Suppl 1):S50–S59, 2014.
12. Pikus HJ, Beach ML, Harbaugh RE: Microsurgical treatment of arteriovenous malformations: analysis and comparison with stereotactic radiosurgery. *J Neurosurg* 88(4):641–646, 1998.

13. Chang SD, Marcellus ML, Marks MP, Levy RP, Do HM, Steinberg GK: Multimodality treatment of giant intracranial arteriovenous malformations. *Neurosurgery* 53(1):1–11; discussion 11–3, 2003.
14. Ujiie H, Higa T, Hayashi M, Tamano Y, Muragaki Y, Hori T: Surgical management of Spetzler-Martin grade V AVM. *J Clin Neurosci* 9 (Suppl 1):22–25, 2002.
15. Nataraj A, Mohamed MB, Gholkar A, Vivar R, Watkins L, Aspoas R, Gregson B, Mitchell P, Mendelow AD: Multimodality treatment of cerebral arteriovenous malformations. *World Neurosurg* 82(1-2):149–159, 2014.
16. Lv X, Wu Z, Jiang C, Li Y, Yang X, Zhang Y, Zhang N: Complication risk of endovascular embolization for cerebral arteriovenous malformation. *Eur J Radiol* 80(3):776–779, 2011.
17. Ogilvy CS, Stieg PE, Awad I, Brown RD Jr, Kondziolka D, Rosenwasser R, Young WL, Hademenos G, Special Writing Group of the Stroke Council, American Stroke Association: AHA Scientific Statement: Recommendations for the management of intracranial arteriovenous malformations: a statement for healthcare professionals from a special writing group of the Stroke Council, American Stroke Association. *Stroke J Cereb Circ* 32(6):1458–1471, 2001.
18. Ding D, Yen C-P, Starke RM, Xu Z, Sheehan JP: Radiosurgery for ruptured intracranial arteriovenous malformations. *J Neurosurg* 121(2):470-480, 2014.
19. Blackburn SL, Ashley WW, Rich KM, Simpson JR, Drzymala RE, Ray WZ, Moran CJ, Cross DT, Chicoine MR, Dacey RG, Derdeyn CP, Zipfel GJ: Combined endovascular embolization and stereotactic radiosurgery in the treatment of large arteriovenous malformations. *J Neurosurg* 114(6):1758–1767, 2011.



20. Spetzler RF, Martin NA: A proposed grading system for arteriovenous malformations. *J Neurosurg* 65(4):476–483, 1986.
21. Weisscher N, Vermeulen M, Roos YB, de Haan RJ: What should be defined as good outcome in stroke trials; a modified Rankin score of 0-1 or 0-2? *J Neurol* 255(6):667–674, 2008.
22. Sulter G, Steen C, De Keyser J: Use of the Barthel index and modified Rankin scale in acute stroke trials. *Stroke J Cereb Circ* 30(8):1538–1541, 1999.
23. Vanpee G, Hermans G, Segers J, Gosselink R: Assessment of limb muscle strength in critically ill patients: a systematic review. *Crit Care Med* 42(3):701–711, 2014.
24. Torné R, Rodríguez-Hernández A, Lawton MT: Intraoperative arteriovenous malformation rupture: causes, management techniques, outcomes, and the effect of neurosurgeon experience. *Neurosurg Focus* 37(3):E12, 2014.
25. Abecassis IJ, Xu DS, Batjer HH, Bendok BR: Natural history of brain arteriovenous malformations: a systematic review. *Neurosurg Focus* 37(3):E7, 2014.
26. Gross BA, Du R: Natural history of cerebral arteriovenous malformations: a meta-analysis. *J Neurosurg* 118(2):437–443, 2013.
27. Gross BA, Du R: Diagnosis and treatment of vascular malformations of the brain. *Curr Treat Options Neurol* 16(1):279, 2014.
28. Kim H, Al-Shahi Salman R, McCulloch CE, Stapf C, Young WL, MARS Coinvestigators: Untreated brain arteriovenous malformation: patient-level meta-analysis of hemorrhage predictors. *Neurology* 83(7):590–597, 2014.
29. Spetzler RF, Ponce FA: A 3-tier classification of cerebral arteriovenous malformations. Clinical article. *J Neurosurg* 114(3):842–849, 2011.

30. Zhao J, Wang C, Wang S, Li J, Sui D, Zhao Y: Combination of intraoperative embolization with surgical resection for treatment of giant cerebral arteriovenous malformation. *Chin Med J (Engl)* 112(3):273–277, 1999.
31. Chang SD, Marcellus ML, Marks MP, Levy RP, Do HM, Steinberg GK: Multimodality treatment of giant intracranial arteriovenous malformations. *Neurosurgery* 61(1 Suppl):432–442; discussion 442–444, 2007.
32. Fults D, Kelly DL: Natural history of arteriovenous malformations of the brain: a clinical study. *Neurosurgery* 15(5):658–662, 1984.
33. Crawford PM, West CR, Chadwick DW, Shaw MD: Arteriovenous malformations of the brain: natural history in unoperated patients. *J Neurol Neurosurg Psychiatry* 49(1):1–10, 1986.
34. Zhao J, Yu T, Wang S, Zhao Y, Yang WY: Surgical treatment of giant intracranial arteriovenous malformations. *Neurosurgery* 67(5):1359–1370; discussion 1370, 2010.
35. Han PP, Ponce FA, Spetzler RF: Intention-to-treat analysis of Spetzler-Martin grades IV and V arteriovenous malformations: natural history and treatment paradigm. *J Neurosurg* 98(1):3–7, 2003.
36. Stefani MA, Porter PJ, terBrugge KG, Montanera W, Willinsky RA, Wallace MC: Large and deep brain arteriovenous malformations are associated with risk of future hemorrhage. *Stroke J Cereb Circ* 33(5):1220–1224, 2002.
37. Hernesniemi JA, Dashti R, Juvela S, Väärt K, Niemelä M, Laakso A: Natural history of brain arteriovenous malformations: a long-term follow-up study of risk of hemorrhage in 238 patients. *Neurosurgery* 63(5):823–829; discussion 829–831, 2008.

38. Laakso A, Dashti R, Juvela S, Isarakul P, Niemelä M, Hernesniemi J: Risk of hemorrhage in patients with untreated Spetzler-Martin grade IV and V arteriovenous malformations: a long-term follow-up study in 63 patients. *Neurosurgery* 68(2):372–377; discussion 378, 2011.
39. Graf CJ, Perret GE, Torner JC: Bleeding from cerebral arteriovenous malformations as part of their natural history. *J Neurosurg* 58(3):331–337, 1983.
40. Kronenburg A, van Doormaal T, van Eijsden P, van der Zwan A, Leijten F, Han KS: Surgery for a giant arteriovenous malformation without motor deterioration: preoperative transcranial magnetic stimulation in a non-cooperative patient. *J Neurosurg Pediatr* 14(1):38–42, 2014.
41. Heros RC, Morcos JJ: Cerebrovascular surgery: past, present, and future. *Neurosurgery* 47(5):1007–1033, 2000.
42. Reitz M, Schmidt NO, Vukovic Z, Grzyska U, Zeumer H, Westphal M, Regelsberger J: How to deal with incompletely treated AVMs: experience of 67 cases and review of the literature. *Acta Neurochir Suppl* 112:123–129, 2011.
43. Takagi Y, Takahashi JC, Yoshida K, Ishii A, Hashimoto N, Miyamoto S: Surgical treatment of Spetzler-Martin grade III to V cerebral arteriovenous malformations: 10 years experience in Kyoto University. *Neurol Med Chir (Tokyo)* 52(12):852–858, 2012.
44. Spetzler RF, Martin NA, Carter LP, Flom RA, Raudzens PA, Wilkinson E: Surgical management of large AVM's by staged embolization and operative excision. *J Neurosurg* 67(1):17–28, 1987.
45. Hernesniemi J, Keränen T: Microsurgical treatment of arteriovenous malformations of the brain in a defined population. *Surg Neurol* 33(6):384–390, 1990.

46. Platz J, Berkefeld J, Singer OC, Wolff R, Seifert V, Konczalla J, Güresir E: Frequency, risk of hemorrhage and treatment considerations for cerebral arteriovenous malformations with associated aneurysms. *Acta Neurochir (Wien)* 156(11):2025–2034, 2014.
47. Van Beijnum J, van der Worp HB, Buis DR, Al-Shahi Salman R, Kappelle LJ, Rinkel GJE, van der Sprenkel JWB, Vandertop WP, Algra A, Klijn CJM: Treatment of brain arteriovenous malformations: a systematic review and meta-analysis. *JAMA* 306(18):2011–2019, 2011.
48. Colombo F, Benedetti A, Pozza F, Marchetti C, Chiarego G: Linear accelerator radiosurgery of cerebral arteriovenous malformations. *Neurosurgery* 24(6):833–840, 1989.
49. Friedman WA, Bova FJ: Linear accelerator radiosurgery for arteriovenous malformations. *J Neurosurg* 77(6):832–841, 1992.
50. Yamamoto Y, Coffey RJ, Nichols DA, Shaw EG: Interim report on the radiosurgical treatment of cerebral arteriovenous malformations. The influence of size, dose, time, and technical factors on obliteration rate. *J Neurosurg* 83(5):832–837, 1995.
51. Jones J, Jang S, Getch CC, Kepka AG, Marymont MH: Advances in the radiosurgical treatment of large inoperable arteriovenous malformations. *Neurosurg Focus* 23(6):E7, 2007.
52. Coffey RJ, Nichols DA, Shaw EG: Stereotactic radiosurgical treatment of cerebral arteriovenous malformations. Gamma Unit Radiosurgery Study Group. *Mayo Clin Proc* 70(3):214–222, 1995.

53. Friedman WA, Bova FJ, Mendenhall WM: Linear accelerator radiosurgery for arteriovenous malformations: the relationship of size to outcome. *J Neurosurg* 82(2):180–189, 1995.
54. Lunsford LD, Kondziolka D, Flickinger JC, Bissonette DJ, Jungreis CA, Maitz AH, Horton JA, Coffey RJ: Stereotactic radiosurgery for arteriovenous malformations of the brain. *J Neurosurg* 75(4):512–524, 1991.
55. Pan DH, Guo WY, Chung WY, Shiau CY, Chang YC, Wang LW: Gamma knife radiosurgery as a single treatment modality for large cerebral arteriovenous malformations. *J Neurosurg* 93 (Suppl 3):113–119, 2000.
56. Wang H-C, Chang RJ, Xiao F: Hypofractionated stereotactic radiotherapy for large arteriovenous malformations. *Surg Neurol Int* 3(Suppl 2):S105–S110, 2012.
57. Abla AA, Rutledge WC, Seymour ZA, Guo D, Kim H, Gupta N, Sneed PK, Barani IJ, Larson D, McDermott MW, Lawton MT: A treatment paradigm for high-grade brain arteriovenous malformations: volume-staged radiosurgical downgrading followed by microsurgical resection. *J Neurosurg* 2014 Nov 25 [Epub ahead of print].
58. Xu F, Zhong J, Ray A, Manjila S, Bambakidis NC: Stereotactic radiosurgery with and without embolization for intracranial arteriovenous malformations: a systematic review and meta-analysis. *Neurosurg Focus* 37(3):E16, 2014.
59. Veznedaroglu E, Andrews DW, Benitez RP, Downes MB, Werner-Wasik M, Rosenstock J, Curran WJ, Rosenwasser RH: Fractionated stereotactic radiotherapy for the treatment of large arteriovenous malformations with or without previous partial embolization. *Neurosurgery* 62 Suppl 2:763–775, 2008.

60. Zhao B, Cao Y, Zhao Y, Wu J, Wang S: Functional MRI-guided microsurgery of intracranial arteriovenous malformations: study protocol for a randomised controlled trial. *BMJ Open* 4(10):e006618, 2014.
61. Ding D, Yen C-P, Xu Z, Starke RM, Sheehan JP: Radiosurgery for primary motor and sensory cortex arteriovenous malformations: outcomes and the effect of eloquent location. *Neurosurgery* 73(5):816–824; discussion 824, 2013.
62. Abla AA, Nelson J, Rutledge WC, Young WL, Kim H, Lawton MT: The natural history of AVM hemorrhage in the posterior fossa: comparison of hematoma volumes and neurological outcomes in patients with ruptured infra- and supratentorial AVMs. *Neurosurg Focus* 37(3):E6, 2014.
63. Szajner M, Roman T, Markowicz J, Szczerbo-Trojanowska M: Onyx(®) in endovascular treatment of cerebral arteriovenous malformations - a review. *Pol J Radiol* 78(3):35–41, 2013.
64. Savio K, Pietra GLD, Oddone E, Reggiani M, Leone MA: Reliability of the modified Rankin Scale applied by telephone. *Neurol Int* 5(1):e2, 2013.
65. Quinn TJ, Dawson J, Walters MR, Lees KR: Reliability of the modified Rankin Scale: a systematic review. *Stroke J Cereb Circ* 40(10):3393–3395, 2009.

**Figure Captions:**

**Figure 1:** Bar graph illustrating distribution of patient cohort across mRS scores 0 – 6 at the time of presentation, at early (< 3 months), and late (> 3 months) follow-up periods.

**Figure 2:** Flow diagram depicting relative outcomes in patients treated with microsurgery prior to and after the year 2000.

**Figure 3:** Kaplan-Maier survival analysis demonstrating that there was no statistically significance difference in the rates of 1, 5, and 10-year survival between the microsurgical and observation groups.

**Figure 4. A:** Axial CT head obtained at initial presentation showing intraventricular hemorrhage (IVH) in the left lateral ventricle. **B:** Anteroposterior projection of the left ICA injection showing a giant AVM fed by branches of the MCA and ACA and early venous drainage into the superior sagittal sinus and vein of Galen. **C:** Anteroposterior projection of the left ICA injection obtained postembolization, showing persistent filling of the AVM. **D:** Intraoperative picture of the AVM obtained after opening the dura. **E:** Angiogram revealing complete obliteration of the AVM by surgical extirpation.

**Figure 5. A:** Axial T2 – weighted MRI obtained at initial presentation shows multiple flow voids and a large nidus suggestive of a giant AVM located in the right temporal lobe. **B:** Lateral projection of a vertebral artery injection shows a giant AVM fed by branches of the PCA and early venous drainage into the deep system. **C:** Anteroposterior projection of the right ICA injection shows filling of the AVM by the branches of the MCA. **D:** Cerebral angiogram obtained post-embolization shows residual filling of the AVM despite three embolization attempts with Onyx. **E:** Angiogram revealing complete surgical resection of the AVM.

**Figure 6. A:** Axial CT head obtained at initial presentation showing evidence of subarachnoid hemorrhage and a large tangle of vessels in the midline. **B:** Lateral projection of right ICA injection shows a giant AVM fed by branches of the MCA and a large venous aneurysm. **C and E:** Lateral and AP projection of the left vertebral artery injection shows filling of the posterior

compartment of the AVM by the PCA. **D:** Lateral projection of left ICA injection shows filling of AVM fed by ACA.

**Figure 7. A and B:** Coronal and axial T2-weighted M images obtained at time of initial presentation show a giant AVM nidus and multiple flow voids in the right basal ganglia, internal capsule and insula. Appreciate the effacement of the right lateral ventricle caused by the mass effect. **C:** Lateral projection of the right ICA injection shows that AVM is fed primarily by the perforating vessels (lenticulostriate branches) of the ICA, MCA and ACA, making it a challenge to treat it safely by surgical or endovascular means.



Table 1 Patient demographics and AVM characteristics.

Pt.	Age (yrs)	Sex	Present.	Size (cm)	Location	S M	Arterial Feeders	Treat.	Initial mRS	F/u mRS		F/u (mo)	AVM Obliteration	Complication
										Early	Late			
1	64	M	HA, ICH	6	R, P-O	4	A/M/PCA	Sx	1	3	2	177	Complete	Field cut*
2	56	F	ICH, Sz	7	R, F-P	4	ACh, MCA, ThP	NR	3	3	6	36	-	Death 2/2 ICH
3	50	M	Diplopia	6	R, P-O	4	M/PCA	E + Sx	1	1	1	62	Complete	Chronic HA
4	48	F	HA, ICH	7	Vermis	5	A/PICA, SCA	Sx	3	5	6	0	Complete	PVS and WD
5	20	M	ICH	7	L, F-P	5	A/MCA	E + Sx	3	3	3	82	Complete	Aphasia, paresis*
6	54	F	HA, ICH	6	R Sylvian	4	MCA	Sx	1	4	Lost	2	Complete	Field cut, plegia*
7	35	M	Sz	6	L, T-P	5	ACh, MCA	Dec.	2	2	2	89	-	Chronic Sz
8	49	F	HA, ICH	6	L, P-O	5	A/M/PCA	Dec.	3	3	6	480	-	Death 2/2 ICH
9	41	M	Sz	6	L, T	5	ACh, M/PCA	Sx	2	5	Lost	3	Complete	Aphasia, plegia
10	50	M	Sz	7	R, PO, CC	5	M/PCA	NR	2	2	2	268	-	Chronic Sz
11	13	M	Sz	7	L, P, CC	5	A/M/PCA	E + Sx	3	3	3	78	Complete	Paresis
12	64	M	Sz	6	R, F	5	A/MCA	Dec.	1	1	0	126	-	None
13	28	M	ICH, Sz	6	R, BG	5	A/M/PCA	NR	3	3	3	3	-	Paresis
14	41	F	HA	6	L/R, P-O	5	A/M/PCA	NR	1	3	5	312	-	PVS

15	49	M	HA, ICH	7	Vermis	4	SCA	Sx	1	3	3	25	Complete	Truncal ataxia
16	50	M	HA, ICH	8	R, P	4	A/M/P	E + Sx	1	4	3	171	Complete	Paresis
17	17	F	HA, Tin.	9	Cerebell.	5	SCA, PCA	E + Sx	1	6	-	0	Complete	Death 2/2 ICH
18	35	M	HA	6	R, P-O	4	M/PCA	Sx	1	4	3	65	Complete	Field cut, paresis
19	65	F	Sz	6	R, F-P	4	A/MCA	Sx	2	3	3	32	Complete	Paresis
20	23	M	ICH, Sz	7	R, T-O	5	M/PCA	E + Sx	2	2	1	40	Complete	Field cut
21	22	F	Sz	6	L, O	5	A/MCA	SRS	1	2	Lost	3	Partial	Field cut, Sz
22	53	F	HA, ICH	6	R, T-P	5	A/M/PCA	Sx	1	4	3	12	Complete	Field cut, paresis
23	34	M	HA, ICH	6	L, P-T	5	M/PCA	E+ SRS	2	2	2	98	Partial	Sz
24	33	M	HA	6	L, F-P	5	A/MCA, LStr	Dec.	3	2	2	96	-	HA, paresis
25	59	F	HA, Sz	8	R T-P-O	5	A/M/PCA	E + Sx	2	4	3	30	Complete	Paresis
26	30	F	HA	9	R, F-T	4	A/M/PCA	Sx	1	6	-	0	-	Death 2/2 ICH
27	38	F	Ataxia	6	Cerebell.	5	A/PICA, SCA	Sx	2	5	5	7	Partial	PVS 2/2 ICH
28	58	M	SZ	7	L Sylvian	5	M/PCA	Dec.	2	2	2	184	-	Sz
29	20	M	HA, ICH	6	L, F-P	5	A/M/PCA	Sx	1	3	2	16	Complete	Sz
30	27	F	AMS	7	Vermis	4	A/PICA, SCA	NR	1	1	Lost	13	-	Hydrocephalus
31	64	M	ICH, Sz	6	L, T-P	4	A/M/PCA	Sx	2	6	-	0	-	Death 2/2 ICH
32	44	F	SZ	6	L, T-P	4	A/MCA, PChA	E + Sx	1	3	1	181	Complete	HA
33	61	F	HA, ICH	8	L, T	5	M/PCA, AChA	E + Sx	1	2	1	231	Complete	Hydrocephalus

34	85	F	ICH, Sz	6	R, P-O	4	A/PCA	E + Sx	3	2	2	19	Complete	Filed cut, Dpress
35	26	M	HA, ICH	8	R, F-P	5	A/M/PCA	Sx	3	4	Lost		Complete	Plegia
36	58	F	ICH, Sz	7	R, F	4	A/MCA	E + Sx	2	4	3	11	Complete	Paresis
37	42	M	HA, ICH	8	R, F-T-P	5	A/M/PCA	Sx	3	6	-	0	-	Death 2/2 ICH
38	54	F	Sz	8	L, F-P	4	A/M/PCA	NR	2	3	3	253	-	Paresis, Sz
39	39	F	Sz, ICH	6	R, F-P	5	A/M/PCA	E + Sx	3	3	2	27	Complete	Sz
40	62	F	Diplopia	6	R, P-O	5	A/M/PCA	Dec.	2	2	4	240	-	Field cut, plegia
41	43	F	SZ	6	R, P	4	A/M/PCA	E + Sx	1	2	0	75	Complete	None
42	58	F	HA, ICH	7	L, F-P	5	ECA, M/PCA	E only	3	6	-	0	-	Death 2/2 ICH
43	50	F	HA, ICH	8	L, F-P	5	A/M/PCA	E + Sx	3	6	-	0	-	Death 2/2 ICH
44	55	F	SZ	6	R, F-P	5	A/MCA	Dec.	1	6	-	1	-	Death 2/2 ICH
45	65	F	HA, ICH	6	Cerebell.	5	A/PICA, SCA	Sx	1	6	-	1	-	Death 2/2 ICH
46	32	M	ICH	8	R, T	5	ECA, A/PCA	NR	3	4	4	46	-	Plegia
47	75	F	HA, Sz	6	L, P-O	4	M/PCA	Dec.	1	1	Lost	3	-	Sz
48	70	F	Sz	8	L, F-P	5	A/M/PCA	Dec.	1	2	6	120	-	Death 2/2 ICH
49	44	F	HA, ICH	6	L, P-O	5	A/M/PCA	E + Sx	3	4	3	117	Complete	Paresis
50	48	M	HA	6	R, F	4	ECA, M/PCA	Sx	3	6	-	0	-	Death 2/2 ICH
51	47	F	HA	6	L, F-T	5	A/MCA	Sx	2	4	3	123	Complete	Aphasia
52	37	M	HA, Sz	6	R, F-P	5	A/MCA	E + Sx	2	3	Lost	2	Complete	Paresis, Sz
53	46	F	HA, ICH	7	L, P-O	4	A/M/PCA	Sx	3	3	Lost	2	Complete	Field cut

54	38	M	HA, Sz	6	L, F-T	4	MCA, PCA	Dec.	1	2	2	47	-	Sz
55	45	M	HA, Sz	7	L, P-O	5	A/M/PCA	Sx	2	3	3	36	Complete	Paresis
56	28	M	Sz	6	R, F	3	A/MCA	Sx	1	1	0	36	Complete	None
57	47	F	HA	6.5	L, F-P	5	A/M/PCA	Sx	0	4	Lost	3	Complete	Aphasia, paresis
58	46	F	Sz	7.5	R, T-P	5	A/M/PCA	Sx	1	3	Lost	2	Complete	Paresis
59	37	M	Sz	7.0	R, F-P	5	A/M/PCA	Sx	2	4	3	252	Complete	Paresis
60	32	F	HA, Sz	6	R, F-P	5	A/MCA	Sx	2	4	4	18	Complete	Plegia
61	58	M	HA, Sz	6	L, F	4	A/MCA	E only	1	2	1	213	Partial	HA
62	34	M	Sz	6	R, F-P	4	A/MCA	Sx	2	3	3	8	Complete	Paresis
63	66	M	Sz	6.5	R, F-P	5	A/MCA	Sx	1	3	3	10	Complete	Paresis
64	55	M	Sz	7	R, F-P	5	A/MCA	NR	1	2	2	58	-	HA

HA, headache; Sz, seizure; ICH, intracerebral hemorrhage; AMS, altered mental status; Tin, tinnitus; R, right; L, left; F, frontal; T, temporal; P, parietal; O, occipital; Cerebell., cerebellar; CC, corpus callosum; ACA, anterior cerebral artery; ECA, external carotid artery; MCA, middle cerebral artery; PCA, posterior cerebral artery, AICA, anterior-inferior cerebellar artery, PICA, posterior-inferior cerebellar artery; SCA, superior cerebellar artery; AChA, anterior choroidal artery; PChA, posterior choroidal artery; LStr, lenticulostriates; ThP, thalamoperforators; Sx, microsurgery; E, embolization; NR, no treatment recommended; Dec., declined any treatment; SRS, stereotactic radiosurgery; 2/2, secondary to; Dpress, depression; \* denotes unilateral deficit, ie hemianopsia or hemi-paresis/pegia; PVS, persistent vegetative state; WD, withdrawal of care; **bolded** cases are illustrated in text.

**Table 2:** Anatomical distribution of gAVMs in our series.

Location	No.	%
<b>SUPRATENTORIAL</b>		
Frontal	5	8
Frontal-parietal	19	30
Frontal-temporal	4	6
Parietal	2	3
Parietal-occipital	11	17
Parietal-temporal	7	11
Temporal	3	4.5
Temporal-occipital	1	1.5
Occipital	1	1.5
Sylvian	2	3
Corpus Callosum	2	3
Basal Ganglia	1	1.5
<b>INFRATENTORIAL</b>		
Cerebellar Hemisphere	3	5
Vermian	3	5
<b>TOTAL</b>	<b>64</b>	<b>100</b>

**Table 3:** Effects of treatment on functional status of patients with gAVMs.

	<b>mRS 0 – 2</b>	<b>mRS 3 – 5</b>	<b>mRS 6</b>
<b>Before Treatment</b>	34 (74%)	12 (26%)	0
<b>After Treatment</b>	13 (28%)	24 (52%)	9 (20%)

**Table 4:** Correlation between SM grade, surgical obliteration, and complication rates.

\*Percentage of patients who underwent microsurgical extirpation of AVMs.

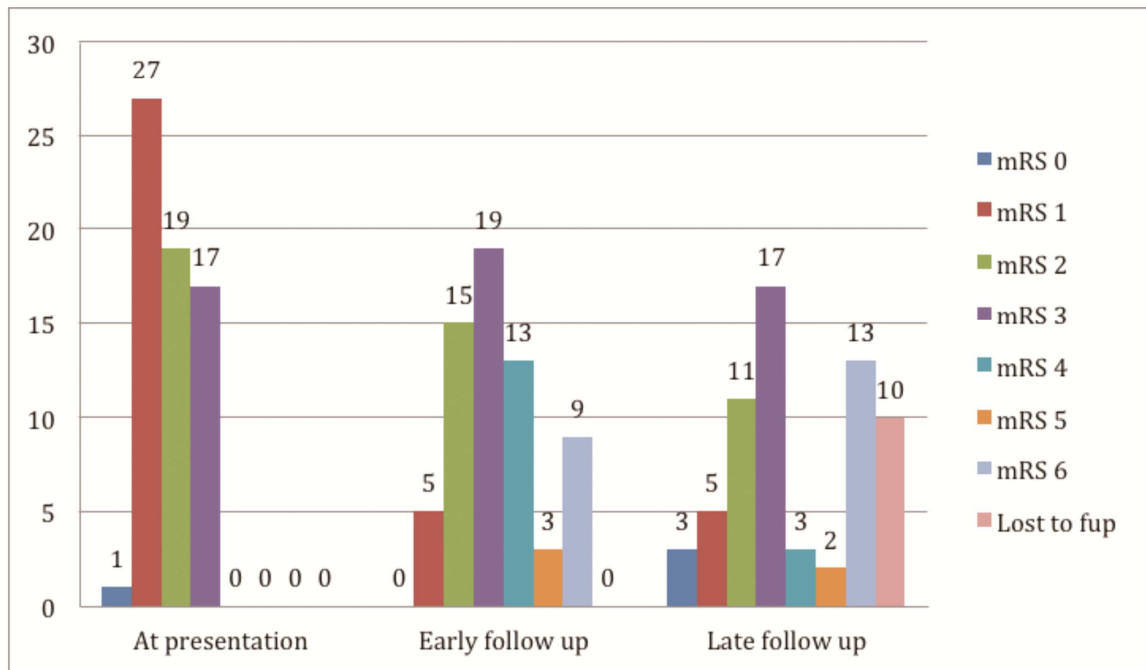
<b>S-M Grade (no. of pts.)</b>	<b>Microsurgery (%)</b>	<b>Complete Obliteration (%)*</b>	<b>Complications (%)*</b>
III (1)	1 (100)	100	0
IV (20)	15 (75)	80	80
V (37)	21 (57)	90	100
Cerebellar AVM (6)	5 (83)	60	100

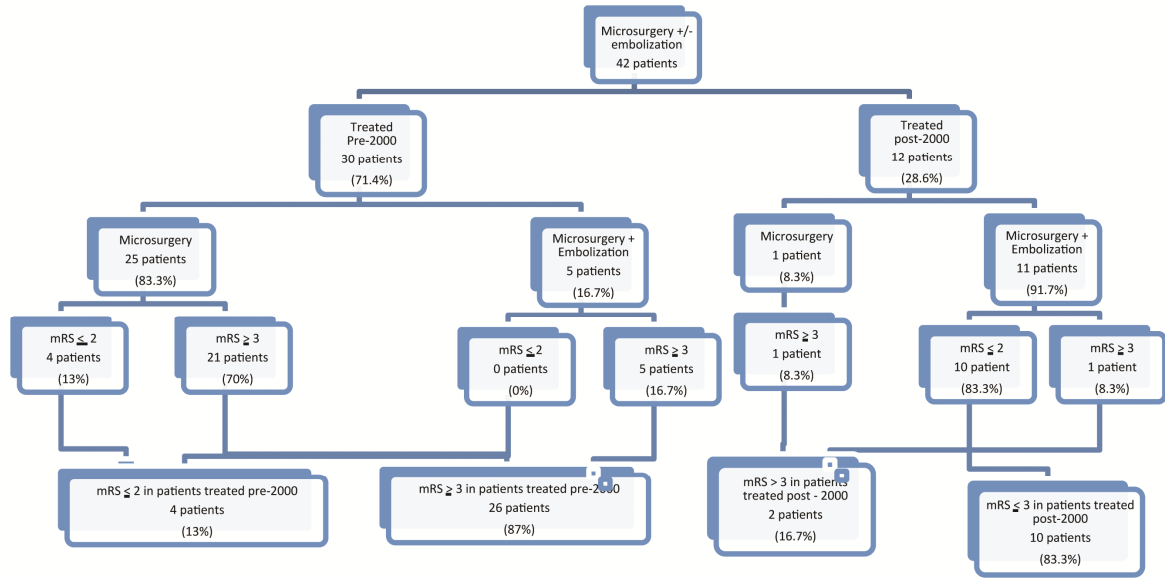
**Table 5:** AVM obliteration rates as well as morbidity and mortality associated with various treatment modalities as compared to conservative management.

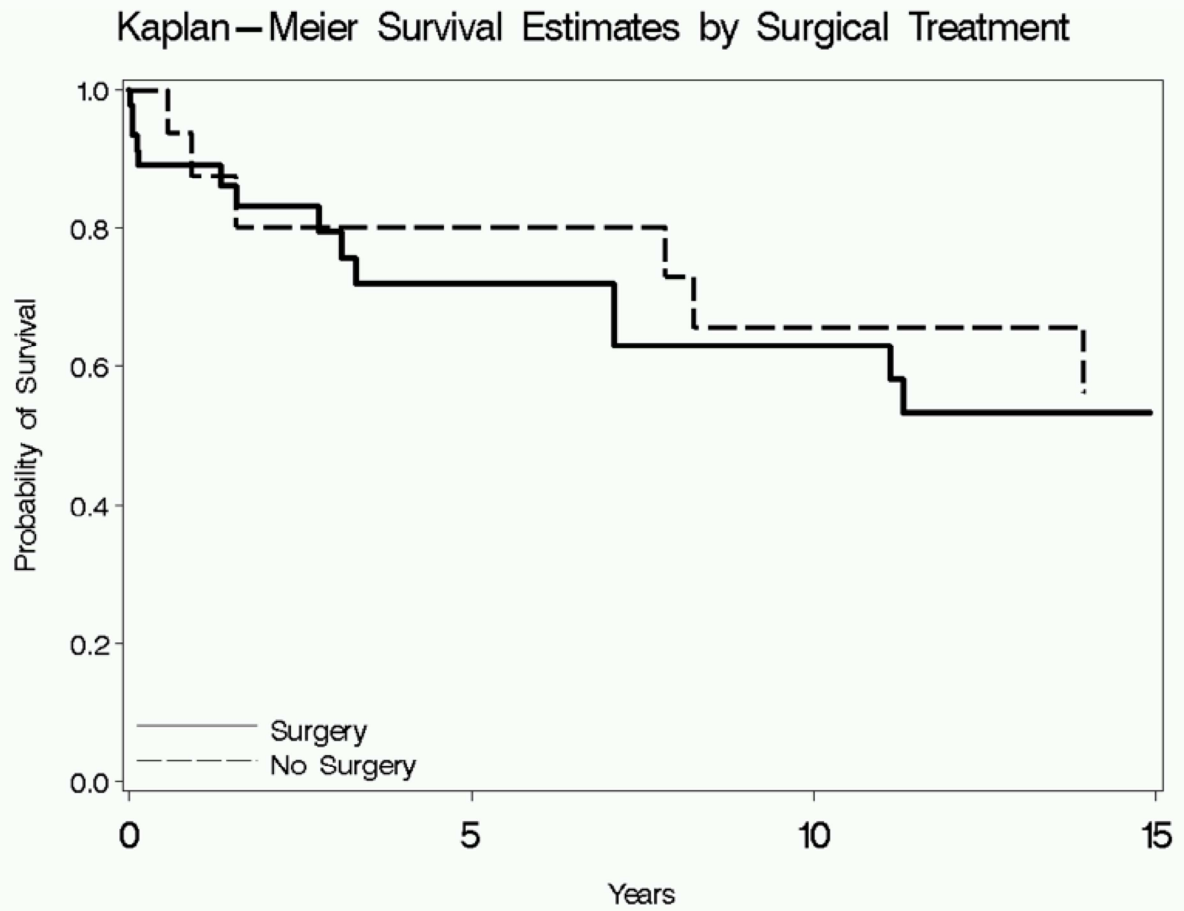
<b>Treatment</b>	<b>No. of pts.</b>	<b>Complete Obliteration (%)</b>	<b>Complications (%)</b>	<b>Death (%)</b>
Surgery only	26	20 (77)	25 (96%)	6 (23)
Embo + Surgery	16	15 (94)	13 (81%)	2 (13)
Embolization only	2	0	2 (100)	1 (50)
Embo + SRS	1	0	1 (100)	0
Radiosurgery	1	0	1 (100)	0
No Treatment	18	N/A	16 (89)	5 (28)



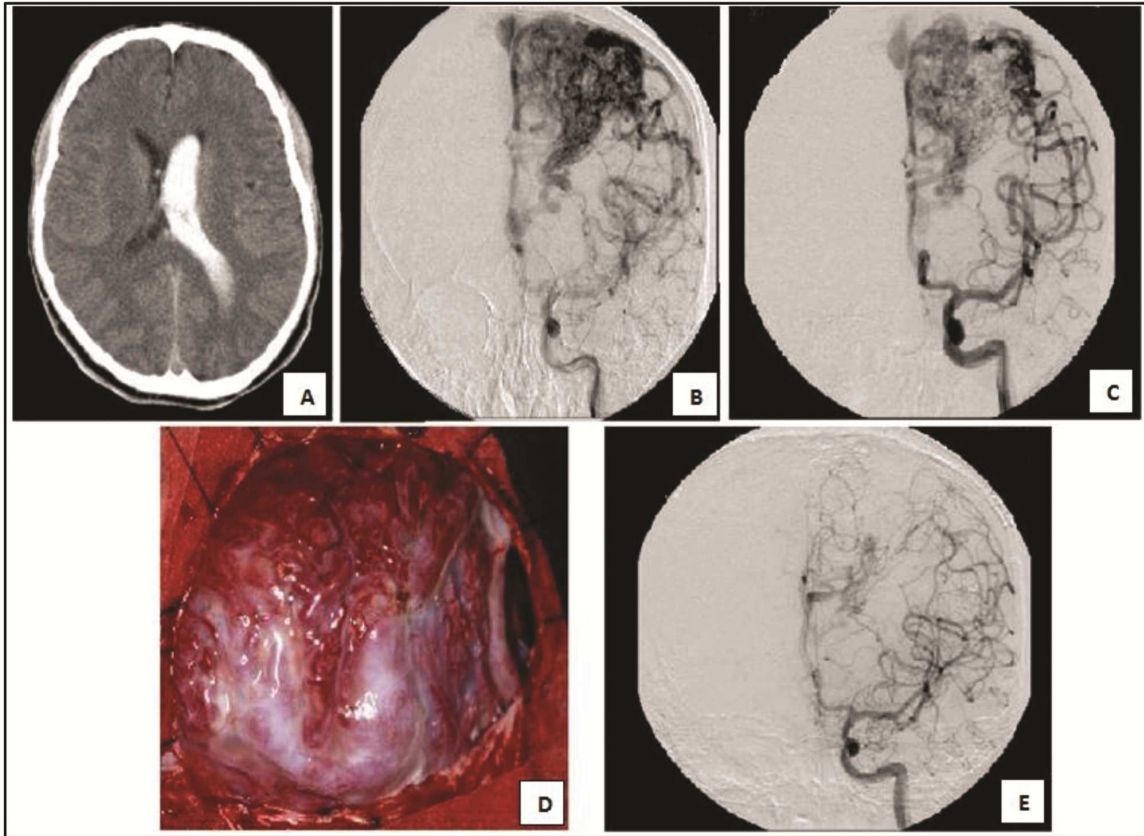
Figure 1



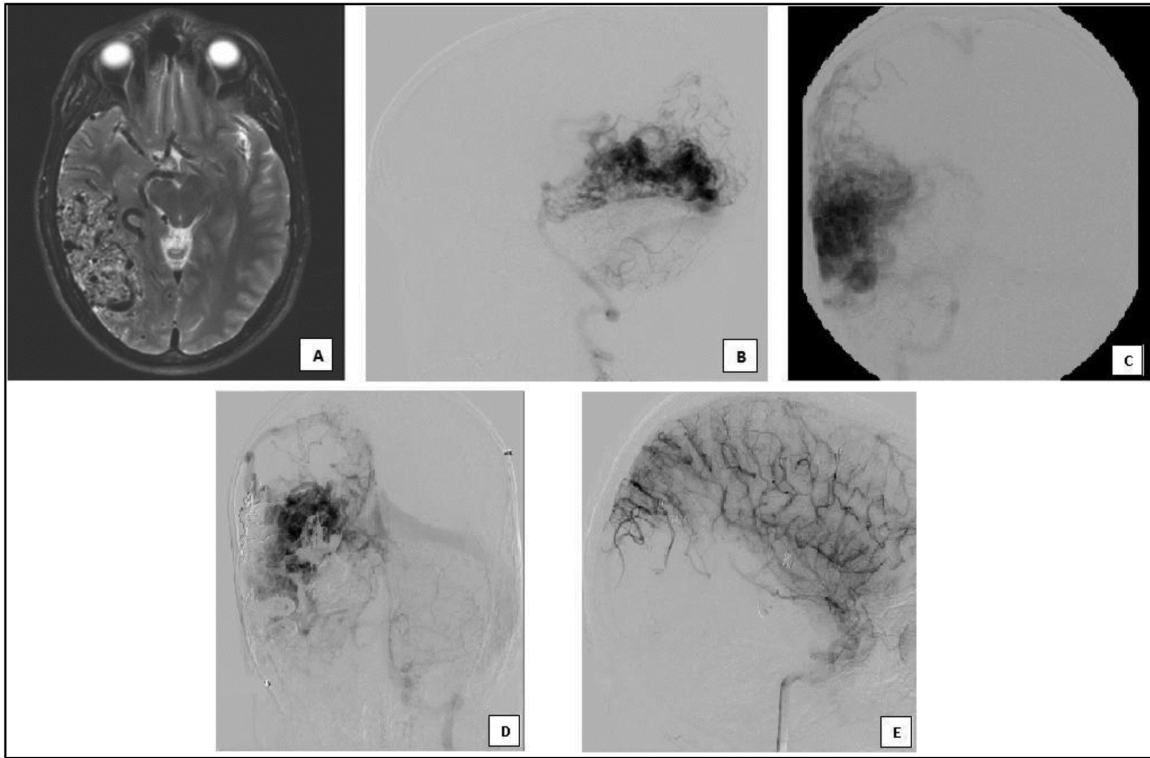




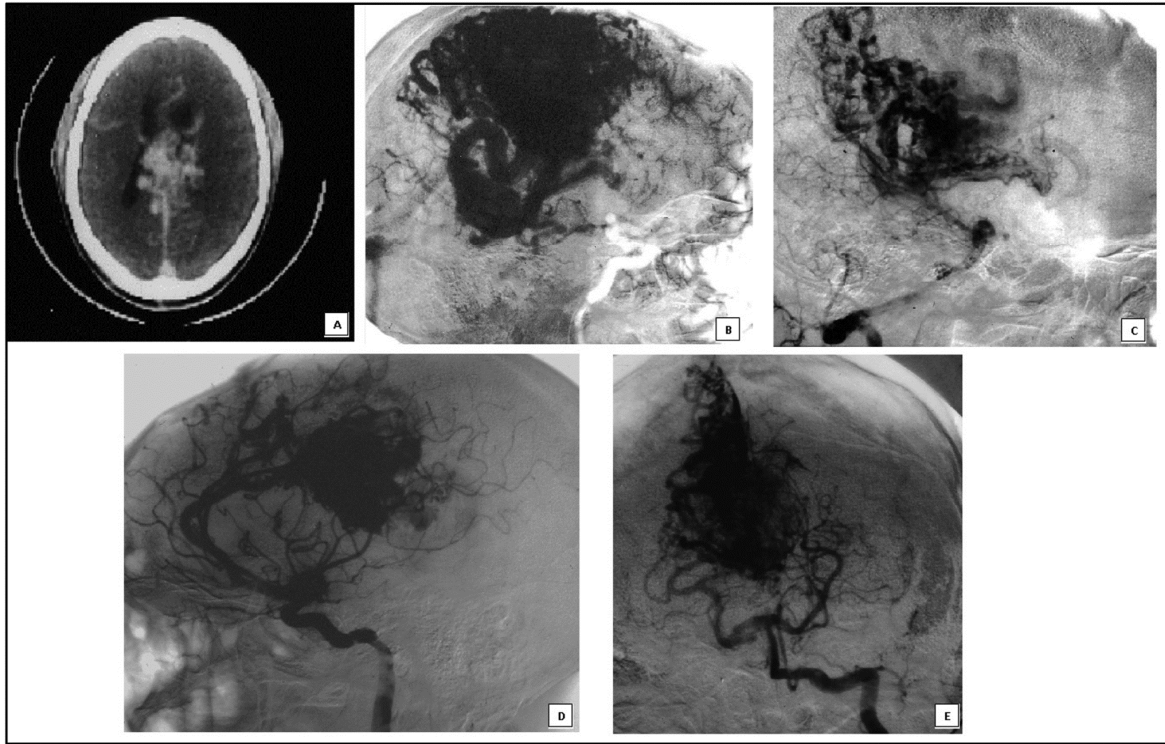
ACCEPTED



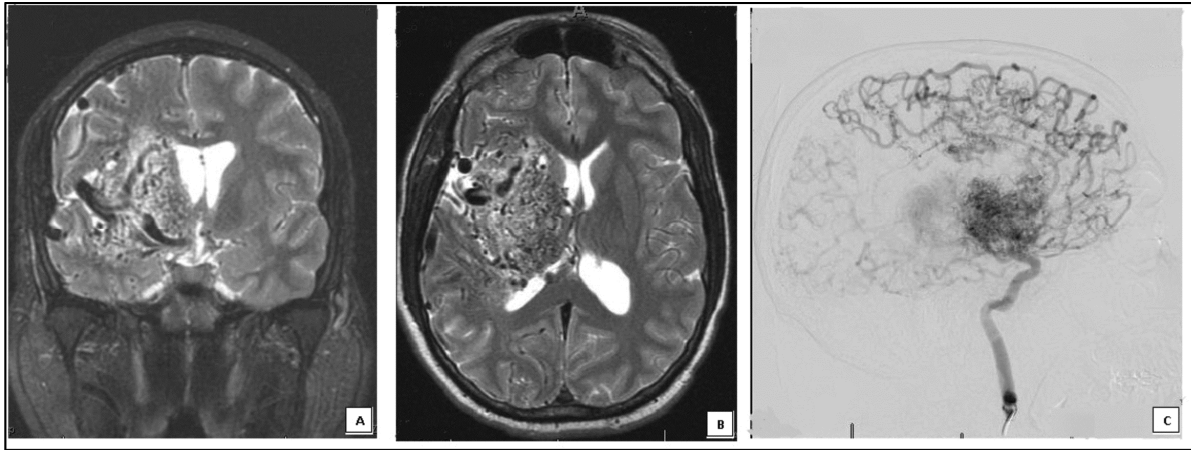
ACCEPTED MANUSCRIPT



ACCEPTED MANUSCRIPT



ACCEPTED MANUSCRIPT



ACCEPTED MANUSCRIPT

**Key words:** Giant arteriovenous malformation, embolization, microsurgery, stereotactic radiosurgery

**Abbreviations and Acronyms:**

ACA: anterior cerebral artery

ACh: anterior choroidal artery

ARUBA: A Randomized trial of Unruptured Brain AVMs

AVM: arteriovenous malformation

gAVM: giant arteriovenous malformation

CT: computed tomography

DSA: digital subtraction angiography

SM: Spetzler-Martin grade

SRS: stereotactic radiosurgery

MRI: magnetic resonance imaging

EVD: external ventricular drain

HRST: hypofractionated stereotactic radiotherapy

ICH: intracranial hemorrhage

IVH: intraventricular hemorrhage

LSt: lenticulostriate artery

MCA: middle cerebral artery

MRC: medical research council

mRS: modified Rankin score

NBCA: N-butylcyanoacrylate

OR: Odds ratio

PCA: posterior cerebral artery

SAH: subarachnoid hemorrhage

SD: standard deviation



**Disclosure Statement:**

The authors confirm there are no conflicts of interest or funding sources to disclose.

Kevin Reinard, MD

Aqueel Pabaney, MD

Azam Basheer, MD

Scott B. Phillips, MD

Ghaus M. Malik, MD