

CASE REPORT

Intracerebral haemorrhage and hemiplegia with heterotopic ossification of the affected hip

M M C O'Brien,¹ T Murray,² F Keeling,² D Williams³

¹Department of Geriatric Medicine, Beaumont Hospital, Dublin, Ireland

²Department of Radiology, Beaumont Hospital, Dublin, Ireland

³Department of Geriatric and Stroke Medicine, Royal College of Surgeons in Ireland and Beaumont Hospital, Dublin, Ireland

Correspondence to

Dr M M C O'Brien,
drnichelleobrien@gmail.com

Accepted 20 July 2015

SUMMARY

We present the case of a 72-year-old woman who developed right hemiparesis following a left frontal intraparenchymal haemorrhage. Three months following initial presentation, the patient noted poorly localised right lower quadrant pain. Following extensive investigations, a diagnosis of heterotopic ossification of the hip was made. We discuss the aetiology and pathogenesis of this uncommon entity, and discuss its relationship to ipsilateral neurological injury. The link with neurological injury can result in a delayed and atypical presentation. Early recognition and treatment are important for those caring for patients with acquired neurological deficits, and permit improved patient outcomes.

BACKGROUND

Spontaneous intracerebral haemorrhage is the second most common cause of stroke and carries a high morbidity and mortality rate. The incidence of intracerebral haemorrhage is approximately 16–33 cases per 100 000.¹ It is widely acknowledged that such patients require to be managed in an intensive care unit whereby the patient's vitals are monitored regularly and managed appropriately. Heterotopic ossification (HO) is a rare phenomenon and has been documented to occur in patients with hemiplegia. We present a case of HO secondary to spontaneous intracerebral haemorrhage, and describe the importance of differentiating this benign entity from other more sinister causes of soft-tissue calcification.

CASE PRESENTATION

A 72-year-old woman presented to a tertiary referral hospital with acute onset dense right-sided hemiparesis. Medical history was significant for type 2 diabetes mellitus, hypertension and depression. Examination on admission revealed hypertension (145/95 mm Hg). National Institute of Health Stroke Score (NIHSS) was 24/34, and Glasgow Coma Scale (GCS) was 11/15. Non-contrast CT of the brain on admission demonstrated a left frontal parenchymal haemorrhage. Medical management was initiated. Four weeks following acute presentation, paroxysmal atrial fibrillation was diagnosed. The patient developed bilateral pulmonary emboli with an associated right heart strain. A temporary inferior vena cava filter was inserted, and anticoagulation was started following resolution of the intraparenchymal haemorrhage. New onset of seizure activity ensued some months postinitial presentation. Repeat imaging demonstrated a new right frontal lobe subarachnoid

haemorrhage. Antiepileptic medication with levetiracetam was started.

Two months postinitial presentation the patient reported poorly localised right iliac fossa pain. Owing to dysarthria and dysphasia, patient history was difficult and site of pain was difficult to elicit. Initial abdominal investigation comprised of a plain film X-ray of the abdomen and an ultrasound abdomen, which were unremarkable. A radiograph of the pelvis was performed, to exclude a pelvic cause of the poorly-localised right flank pain. The pelvic radiograph demonstrated calcification extending from the lateral margin of the acetabulum and proximal femur (figure 1). It was thought that this may be due to heterotopic bone formation or an underlying bony lesion. At this point, a wide differential diagnosis was suggested, included exostosis, osteochondroma, parosteal osteosarcoma and soft-tissue sarcoma. CT of bilateral hips showed extensive calcification/ossification in the soft tissue and gluteal musculature adjacent to the right hip joint (figure 2). It appeared to be separate from the bone except at the most inferior aspect just inferior to the lesser trochanter where it was not seen separately from the surface of the femur. Fluoroscopic bone biopsy was performed, as the history of pain was concerning for malignant transformation.

Alkaline phosphatase (AP) results on admission showed an AP of 60 (ref range; 30–130) which steadily increased over 4 weeks to a peak of 306, remaining at that level for a further month (figure 3). It was

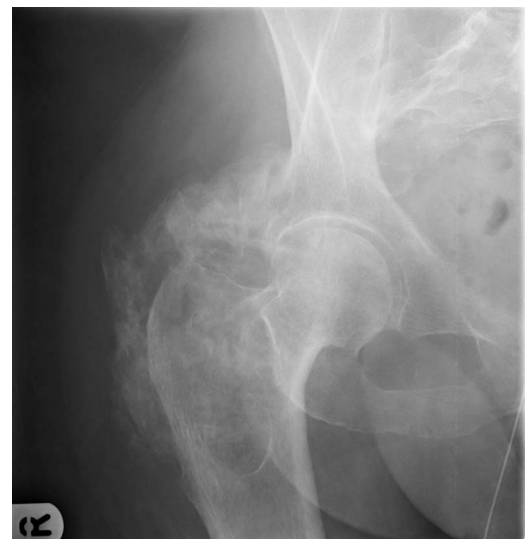


Figure 1 Plain film radiograph demonstrates diffuse calcification surrounding the right hip. The joint itself is preserved.



To cite: O'Brien MMC, Murray T, Keeling F, *et al.* *BMJ Case Rep* Published online: [please include Day Month Year] doi:10.1136/bcr-2015-211467

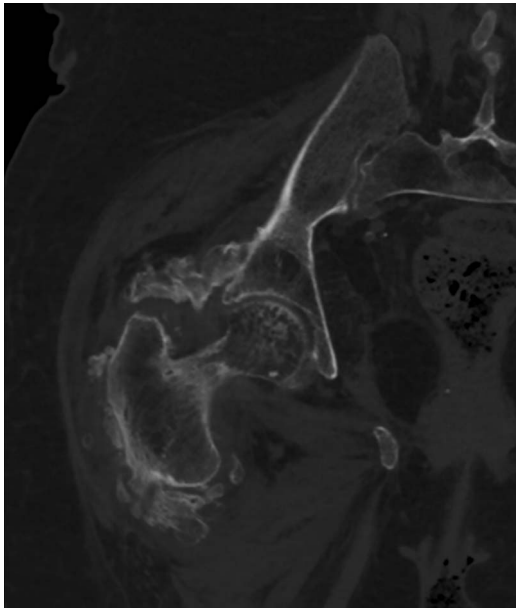


Figure 2 Axial CT demonstrates calcification within the soft tissue extending from the right acetabulum and ischium medially, to the proximal femur laterally.

at that time that investigations into the right iliac fossa and hip pain began. Our patient was treated with analgesia while investigations were undertaken. Slowly over the following 8 weeks, the AP steadily decreased to a level of 120 and remained in the normal range.

The biopsy demonstrated disorganised fibrous tissue and bony fragments within the biopsy, but did not reveal any malignant cells. 99mTechnetium bone scan was performed. Marked increase in radioisotope activity was noted at the right hip (figure 4), corresponding with the site of the known soft tissue ossification and patient symptoms. The remainder of the axial skeleton and the lower limbs were within normal limits. The characteristic differentiating feature in this case was osseous maturation and development of a peripheral corticated rim on imaging.

INVESTIGATIONS

Plain film radiograph demonstrated diffuse calcification surrounding the right hip. The joint itself was preserved.

Figure 3 Alkaline phosphatase (AP) results increased from normal range on admission (ref range; 30–130) to a peak of 306.

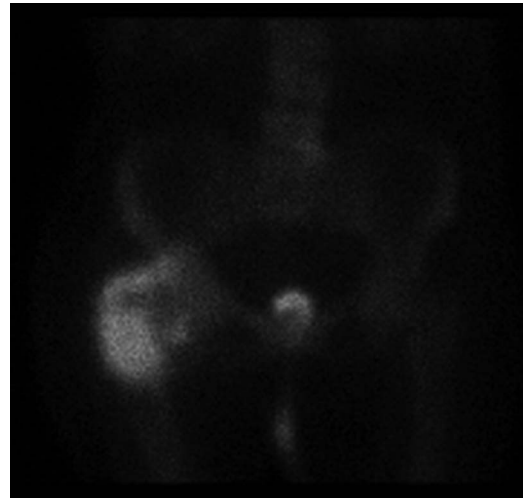
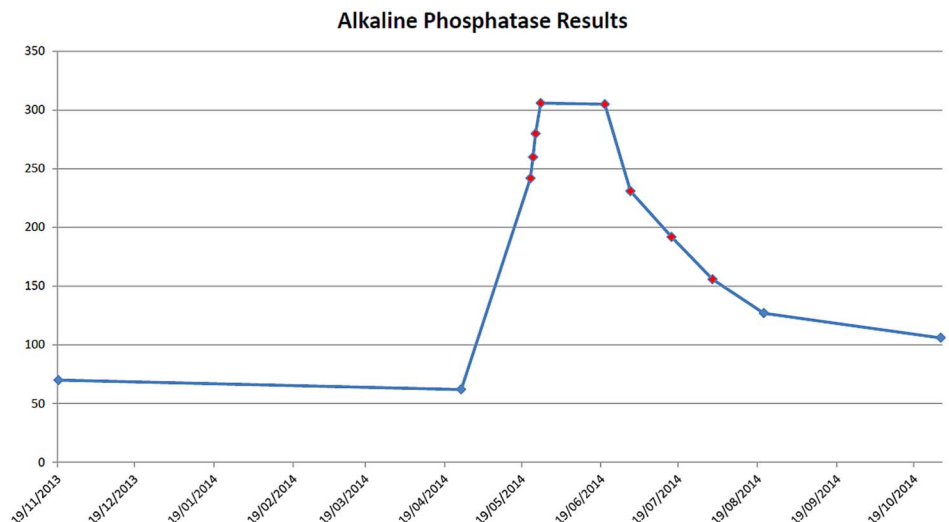


Figure 4 Planar scintigraphic imaging demonstrates increased radioisotope within the right hip and surrounding soft-tissue. Further urinary isotope noted within urinary catheter.

CT demonstrated calcification within the soft tissue extending from the right acetabulum and ischium medially, to the proximal femur laterally.

Planar scintigraphic imaging demonstrated increased radioisotope within the right hip and surrounding soft-tissue. Further urinary isotope was noted within urinary catheter.

DIFFERENTIAL DIAGNOSIS

- ▶ Heterotopic ossification
- ▶ Osteochondroma with malignant transformation into a chondrosarcoma
- ▶ Exostosis
- ▶ Parosteal osteosarcoma
- ▶ Soft-tissue sarcoma

TREATMENT

From a multidisciplinary perspective, this patient was assessed by the stroke rehabilitation team shortly following admission to the stroke unit, with input from nursing, physiotherapy, occupational therapy, speech and language therapy and nutritionists. Rehabilitation continued over the following weeks. On onset of

the right iliac fossa and right hip pain, analgesia was started and investigation ensued. Rehabilitation was intermittently halted due to it causing discomfort to the patient. The patient required assistance of two people for functional movement, when reassessed 3 months later, the same result was noted. A mild passive range of movement exercise programme followed.

Reported management plans for patients with HO include; identifying those at risk and treating prophylactically, surgical intervention, radiotherapy and physiotherapy.

OUTCOME AND FOLLOW-UP

A conservative management plan was adopted in this case with regular analgesia and additional pain relief as required. In addition, a gentle passive range of movement exercise programme was followed. No significant improvement in functional status was noted.

DISCUSSION

HO is the formation of bone in an abnormal site. Generally, lamellar bone forms in the soft tissue surrounding a joint.² It was first described by Patin in 1692³ when working with children diagnosed with myositis ossificans progressive, a rare genetic disorder characterised by the progressive ossification of skeletal muscle. Dejerine and Cellier⁴ described a similar entity in patients with spinal cord injury in the aftermath of World War I. In 1954, it was first documented by Irving and LeBrun in patients with hemiplegia.⁵ HO in post-stroke hemiplegia occurs in 0.5–1.2%.⁶ Its diagnosis is often confused with and mimicked by a number of other conditions including; cellulitis, osteomyelitis, thrombophlebitis, osteosarcoma and osteochondroma. Presentation of HO can be due to pain, palpable mass, fever, decreased range of motion, decreased mobility, inflammation, swelling or effusion. Two forms appear to exist; acquired and hereditary. The acquired form is the more common and can be due to trauma or a neurogenic cause. The inherited form is known as myositis ossificans progressiva.⁷ HO in the acquired form has been documented to be caused by head injuries, stroke, encephalitis, spinal cord injuries, burns or direct muscle trauma.^{2–8} The true aetiology of HO remains unknown. Many hypotheses exist including neuronal control mechanisms⁹ and bone morphogenetic protein transforming mesenchymal muscle cells from fibrous tissue into bone.¹⁰ Suggested contributing factors including prostaglandin E2 (PGE2), osteoblast stimulating factors, hypercalcaemia, hypoxia, changes in sympathetic nerve activity, prolonged immobilisation, remobilisation and disequilibrium of parathyroid hormone and calcitonin.⁷

Diagnosis of HO can be aided by AP screening, use of 24 h prostaglandin E2 (PGE2) urinary excretion, and use of various imaging modalities.⁷ AP can increase early in the process before subsequently decreasing to normal range although this pattern can vary. Urinary prostaglandin E2 has also been documented as an early indicator of HO. The radiological modalities used to diagnose HO include plain film radiography, radioisotope bone scan, CT and MRI. Treatment options for HO include bisphosphonates, non-steroidal anti-inflammatories, radiation therapy and surgery.⁷ A recommended timetable for proposed surgery to areas affected by HO does exist. In cases with acquired neurological deficits, 18 months following development of HO has been suggested.¹¹ Bone scans, AP measurements, patient's symptoms and signs are also useful in determining the optimum surgical timing. There are conflicting viewpoints in the literature regarding the benefits of range of motion exercise in patients with HO. It has been suggested that it may contribute to development,¹² while others state it is a valuable treatment aid.^{13–14}

HO may be more prevalent in acquired neurological deficits than the quoted 0.5–1.2%, given the diagnostic challenges in this cohort of patients. There are several common pathological processes in a hemiplegic limb, notably soft-tissue strain in the setting of contractures, premonitory arthritis, or altered sensation due to stroke.¹⁵ HO should be considered in the correct clinical context, and clinicians dealing with this patient cohort should be aware of this entity.

Learning points

- ▶ Haemorrhagic stroke can be associated with significant morbidity and mortality, it is a debilitating condition.
- ▶ Clinicians should be aware that heterotopic ossification is a condition, which although rare, can occur in patients with hemiplegia due to stroke.
- ▶ Alkaline phosphatase levels, 24 h prostaglandin E2 (PGE2) urinary excretion levels and imaging modalities may be utilised to investigate and diagnose heterotopic ossification.
- ▶ Treatment of heterotopic ossification can include; bisphosphonates, non-steroidal anti-inflammatories, radiation therapy, surgery and physiotherapy.

Contributors Contributors to this case include the listed authors who represent the general medical team and radiology colleagues. Additional contributors include the multidisciplinary team, laboratory and pathology diagnostic staff. MMCO is guarantor of this case report.

Competing interests None declared.

Patient consent Obtained.

Provenance and peer review Not commissioned; externally peer reviewed.

REFERENCES

- 1 Sacco S, Marini C, Toni D, *et al.* Incidence and 10-year survival of intracerebral hemorrhage in a population-based registry. *Stroke* 2009;40:394–9.
- 2 Kocaaga Z, Bal S, Gurgan A. Hemiplegia and heterotopic ossification on the non-paretic extremity: a case report. *J Rehabil Med* 2007;39:500–2.
- 3 Bossche LV, Vanderstraeten G. Heterotopic ossification: a review. *J Rehabil Med* 2005;37:129–36.
- 4 Dejerine A, Cellier A. Para-osteo-arthropathies des paraplegiques par lesion medullaire; etude clinique et radiographique. *Ann Med* 1918;5:497.
- 5 Speed J, Banovac K, Sheridan RL, *et al.* Medscape. Heterotopic Ossification. Medscape. Updated May 28th 2013. <http://emedicine.medscape.com/article/327648-overview>
- 6 Varghese G. Heterotopic ossification. *Phys Med Rehab Clin North Am* 1992;3:407–15.
- 7 Shehab D, Elgazzar AH, Collier BD. Heterotopic ossification. *J Nucl Med* 2002;43:346–53.
- 8 Teasell R. Musculoskeletal complications of hemiplegia following stroke. *Semin Arthritis Rheum* 1991;20:385–95.
- 9 Garland DE. Heterotopic ossification. In: Nickell VL, Botte MJ, eds. *Orthopedic rehabilitation*. New York: Livingstone, 1992:452–69.
- 10 Urist MR, Nakagawa M, Nakata N, *et al.* Experimental myositis ossificans: cartilage and bone formation in muscle in response to diffusible bone matrix-derived morphogen. *Arch Pathol Lab Med* 1978;102:312–16.
- 11 Garland DE. A clinical perspective on common forms of acquired heterotopic ossification. *Clin Orthop* 1991;263:13–29.
- 12 Michelsson JE, Ganroth G, Andersson LC. Myositis ossificans following forcible manipulation of the leg. A rabbit model for the study of heterotopic bone formation. *J Bone Joint Surg Am* 1980;62:811–15.
- 13 Stover SL, Hataqay CJ, Zeiger HE. Heterotopic ossification in spinal cord injured patients. *Arch Phys Med Rehabil* 1975;56:199–204.
- 14 Wharton GW, Morgan TH. Ankylosis in the paralyzed patients. *J Bone Joint Surg Am* 1970;52:105–12.
- 15 Hajek VE. Heterotopic ossification in hemiplegia following stroke. *Arch Phys Med Rehabil* 1987;68:313–14.

Copyright 2015 BMJ Publishing Group. All rights reserved. For permission to reuse any of this content visit <http://group.bmj.com/group/rights-licensing/permissions>.
BMJ Case Report Fellows may re-use this article for personal use and teaching without any further permission.

Become a Fellow of BMJ Case Reports today and you can:

- ▶ Submit as many cases as you like
- ▶ Enjoy fast sympathetic peer review and rapid publication of accepted articles
- ▶ Access all the published articles
- ▶ Re-use any of the published material for personal use and teaching without further permission

For information on Institutional Fellowships contact consortiasales@bmjgroup.com

Visit casereports.bmj.com for more articles like this and to become a Fellow