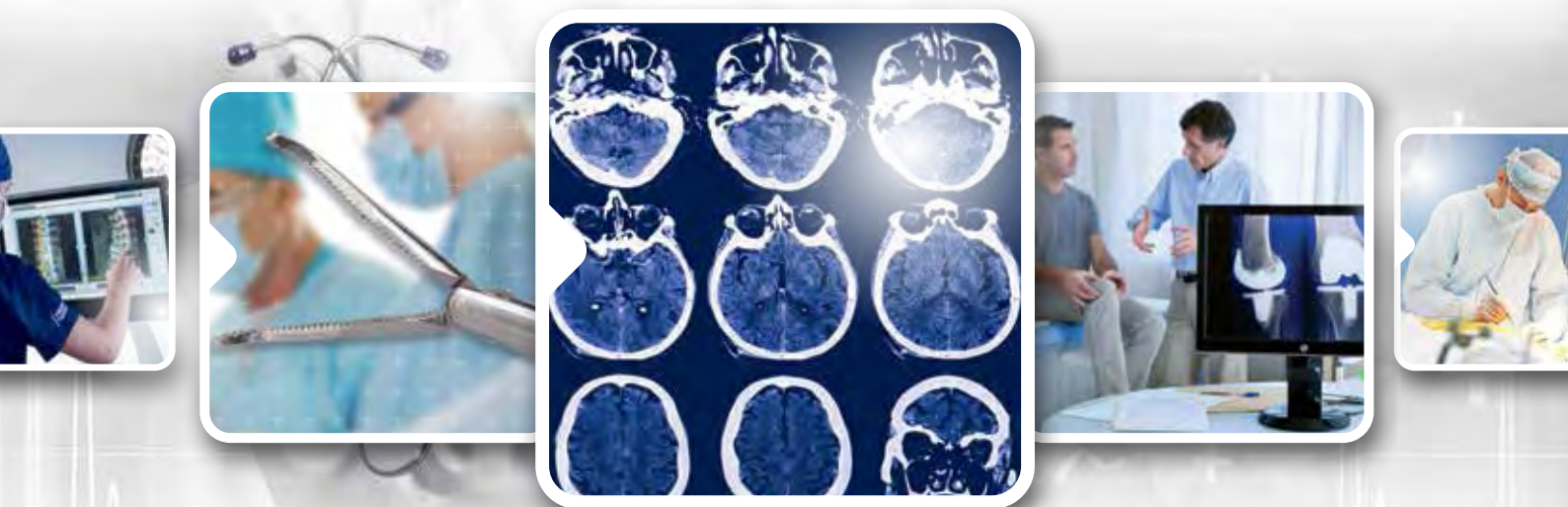

neuroradiology solutions

www.abmedica.it



ab medica s.p.a.
Via nerviano, 31 - 20020 Lainate (MI)
tel +39 02 933051 - fax +39 02 93305400
abmedica@abmedica.it

Rare complication of anterior communicating artery aneurysm coiling: Transient retrograde amnesia

Ravindra B Kamble¹, Veena Sheshadri², Anand Jayaraman³ and BA Chandramouli⁴

Abstract

Amnesia is an unusual and rare complication following endovascular coiling of intracranial aneurysms. We present a case of anterior communicating artery (ACOM) aneurysm in which the patient developed retrograde amnesia following endovascular coiling of the aneurysm. On imaging there was infarct involving bilateral fornices. The patient showed significant clinical improvement on follow up.

Keywords

anterior communicating artery aneurysm, coiling, amnesia, fornix infarct

Introduction

Memory is dependent on important structures like the fornix, hippocampus, thalamus, and mammillary bodies; hence any damage to these structures, such as surgery or trauma, can cause amnesia.^{1,2} Disruption of this memory circuit following endovascular coiling of anterior communicating artery (ACOM) aneurysm leading to memory disturbances is rarely described. We describe a case of retrograde amnesia following endovascular coiling of an ACOM aneurysm with the intention of creating awareness amongst treating physicians of this entity and the need to exercise vigilance, especially while treating posterior circulation and ACOM aneurysms.

Case history

A 56-year-old teacher of Indian origin presented with sudden-onset severe headache followed by vomiting. He was rushed to hospital where a computed tomography (CT) scan and magnetic resonance imaging (MRI) of brain was done which showed an ACOM aneurysm on magnetic resonance (MR) angiogram without subarachnoid hemorrhage. The patient was shifted to our center for further management. He was clinically stable and central nervous system (CNS) examination was grossly normal. The patient did not have any risk factors. He had a history of migraine for the past 15 years. CT angiogram (64-slice Somatom Siemens) was done which showed wide-necked ACOM aneurysm (Figure 1). In view of the classic clinical history of severe headache suggesting sentinel bleed from the aneurysm, the patient was

offered endovascular treatment. Following all the pre-operative investigations (which were normal), the patient underwent endovascular coiling of ACOM aneurysm with Echelon microcatheter (Covideon), Traxcess microguidewire (Microvention), and Axiom coils (Covideon) in flat panel single plane Siemens angiosuite. The patient's activated clotting time (ACT) was kept around 2–2.5 times the baseline by titrating the heparin dose during the procedure (114 baseline and 250 during the procedure) by giving 5000 IU of heparin as bolus. Immediate post-procedure angiogram showed complete occlusion of ACOM aneurysm, however the left anterior cerebral artery (ACA) was not filling from right side injection which was seen filling earlier. The left ACA was seen filling from left injection (Figure 2). The procedure was uneventful except for low blood pressure throughout (systolic 90 with mean of 70). Patient was extubated without any immediate sensory/motor neurological deficits.

After complete recovery from anesthesia, the patient was confused and was repetitively inquiring 'Where am I?', 'Why I am here?' and 'What happened to me?'. Otherwise the patient was alert, conscious, coherent, and speaking relevantly. He was able to remember

¹Department of Radiology, Vikram Hospital, Bangalore, India

²Department of Neuroanesthesia, Vikram Hospital, Bangalore, India

³Department of Psychiatry, Vikram Hospital, Bangalore, India

⁴Department of Neurosurgery, Vikram Hospital, Bangalore, India

Corresponding author:

Ravindra Bhimrao Kamble, Radiology, Vikram Hospital, Millers Road, Bangalore, Karnataka, 560052, India.

Email: dravindra31@rediffmail.com

past events and could also recognize all his relatives who were visiting him.

The opinion of a psychiatrist was sought. The patient was a retired teacher for the last 14 years. He lived with his extended family and reportedly had a good family life without significant social or financial stresses. However, he did report being easily tense, anxious and having a worrier-like pre-morbid personality from a young age, which was corroborated by his wife,

and added that he was easily irritable at times about things that he would neither elaborate nor discuss.

As part of the evaluation, we undertook a neuropsychiatric evaluation the following day using the neuropsychological battery. The patient showed deficits in free recall, verbal and visual learning memory with retrograde amnesia for recent events.

Thus, a working diagnosis of acute stress reaction (ICD-10 F43.2) was made and patient was started on escitalopram, 5mg at night. As his condition did not improve after two days, an MRI scan of the brain (1.5T Avanto Siemens) was done. Routine MRI sequences like diffusion weighted image (DWI) b-0 and b-1000 (time of repetition (TR) 3800, time to echo (TE) 102, band width (BW) 964, field of view (FOV) 230 × 230), T1W (TR 550, TE 8.7, FOV 230 × 230), T2W (TR 5000, TE 126, FOV 208 × 230) and fluid attenuation inversion recovery (FLAIR) (TR 9000, TE 92, TI 2500, FOV 230 × 230) were done, along with time of flight (TOF) MR angiogram (TR 25, TE 7.0, bandwidth 100, FOV 153 × 183). MRI showed lacunar restricted diffusion abnormalities in the bilateral anterior fornix, right side putamen, right peritrigonal region, and left corona radiata (Figure 3). TOF MR angiogram showed normal bilateral anterior cerebral arteries with non-visualization of ACOM aneurysm suggesting complete occlusion (Figure 4). During this post-procedure period, the patient was on intravenous heparin 2500 IU every eight hours (for two days) and after the diagnosis of forniceal infarct, Tab. Ecospirin 150 mg once a day was started. Thus, the final diagnosis of amnesia due to bilateral acute forniceal infarct was made.

After three months of follow-up, the patient had near total recovery. He had a repeat neuropsychological assessment using the same test battery, which showed minimal deficits in verbal fluency and

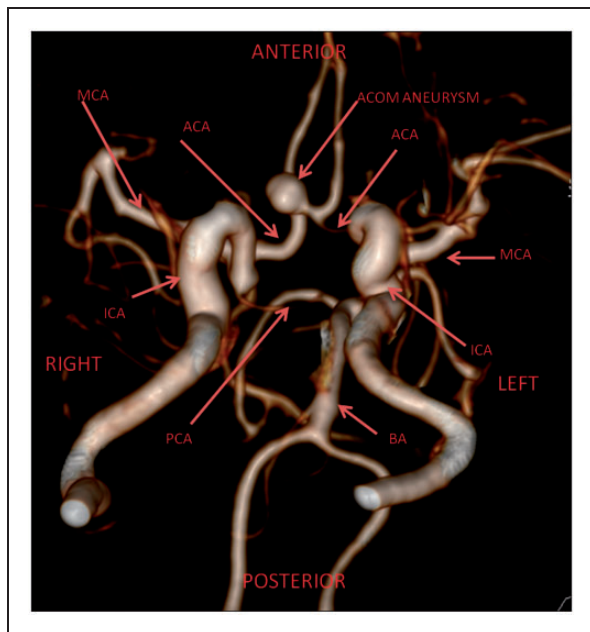


Figure 1. 3D volume rendering computed tomography (CT) angiogram oblique image viewed from inferiorly looking superiorly showing anterior communicating artery (ACOM) aneurysm. The circle of Willis arteries are labeled as shown. MCA - middle cerebral artery, ACA - anterior cerebral artery, PCA - posterior cerebral artery, BA - basilar artery, ICA - internal carotid artery.

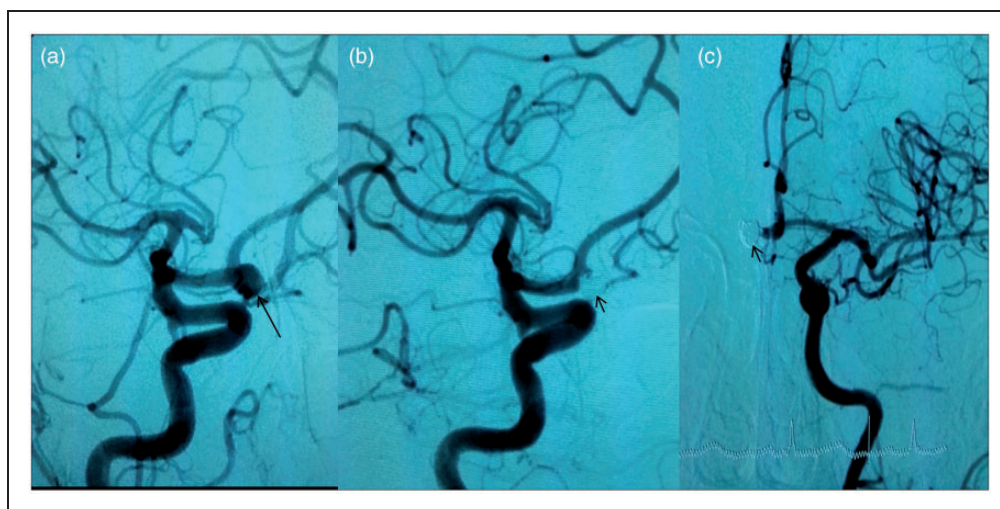


Figure 2. Digital subtraction angiography in right anterior oblique view (a) and (b) showing anterior communicating artery (ACOM) aneurysm in (a) (long arrow) and post-coiling status in (b) (short arrow) showing complete occlusion of the aneurysm. Note that left ACA is not filling from right injection after coiling as seen in (b). Left anterior cerebral artery (ACA) is seen filling separately from left internal carotid artery (ICA) injection as seen in (c) (antero-posterior (AP) view) with coiled ACOM aneurysm (short arrow).

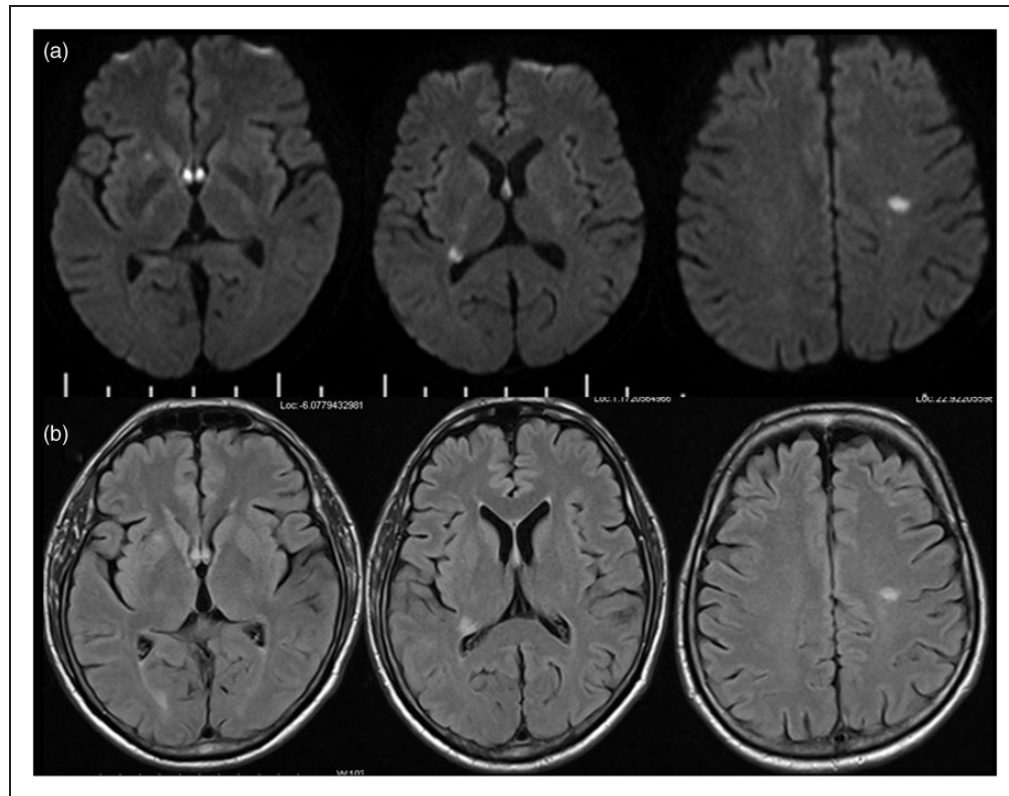


Figure 3. (a) shows restricted diffusion on diffusion weighted image (DWI) in bilateral fornix, right peritrigonal, right putamen and left corona radiata with corresponding fluid attenuation inversion recovery (FLAIR) hyperintensities in (b).

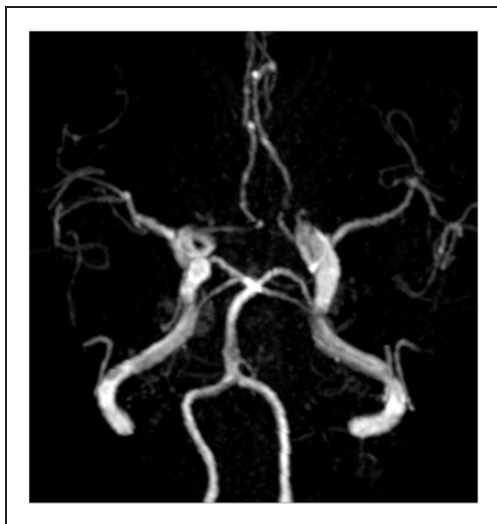


Figure 4. Time of flight (TOF) magnetic resonance (MR) angiogram through Circle of Willis showing normal bilateral anterior cerebral arteries with non visualization of anterior communicating artery (ACOM) aneurysm.

retrograde amnesia. His social skills were back and his premorbid anxiety had also improved. He was unable to remember events in the peri-operative period.

Discussion

Amnesia can occur due to injury to the memory circuit of the fornix and hippocampus with thalamic nuclei

and mamillary bodies following surgery, trauma, or vascular insult.²⁻⁴

Rarely, amnesia is reported following general anesthesia which is usually transient and lasts for few hours and it is called transient global amnesia (TGA).⁵ Various possible mechanisms have been described for TGA such as incompetent internal jugular vein valves causing venous back flow and cerebral congestion.⁶ This venous congestion can occur due to coughing (during/after extubation) or positive end expiratory pressure during anesthesia. Benzodiazepines used in general anesthesia can be another cause for TGA.⁷ Other predisposing factors are migraine, physiological stress and emotional disturbances. Caplan et al. have suggested the association of TGA with migraine due to possible posterior cerebral artery vascular dysfunction.⁸ On imaging, transient global amnesia may show diffusion abnormalities in the splenium and parahippocampal gyrus.⁹

Alexander and Freedman have described 11 cases of amnesia and personality changes following surgical clipping of ruptured ACOM aneurysm due to infarctions in the ACOM territory involving medial forebrain, septum, and anterior hypothalamus.¹⁰

Diffusion tensor imaging has also been attempted in forniceal infarcts following surgical clipping of ACOM aneurysm, wherein the infarcted areas show reduced fractional anisotropy values. However, it was also emphasized that preservation of few fibers of forniceal

bundle, visualized on tractography, may predict the prognosis of these patients with amnesia.¹¹

A few case reports of amnesia following endovascular coiling of the aneurysms are also described recently. Of these, Graff-Radford et al. have shown small medial temporal infarct after coiling of posterior circulation aneurysm as a cause of amnesia and the other case report was following ACOM aneurysm coiling.^{12,13}

Thus, both surgical clipping and endovascular coiling of ACOM aneurysm are known to cause amnesia. The blood supply to the fornix is by 4–10 small medial central arteries which arise from the proximal anterior cerebral artery and sometimes they may arise from the ACOM.¹⁴

Occlusion of these perforators can lead to infarction of the fornix and cause amnesia.⁴ Sometimes the dominant median callosal artery supplies the fornix and damage to this artery can cause similar clinical findings.¹¹

We describe a case of amnesia following coiling of ACOM aneurysm. The amnesia in our patient was typically retrograde amnesia. There was a delay in diagnosis due to the similarity of clinical symptoms to an acute stress reaction. However, subsequent MRI showed small acute infarcts involving bilateral anterior fornices, which explain the amnesia. Although the endovascular coiling procedure was uneventful, post-coiling angiography showed occlusion of aneurysm as well as the ACOM artery, with separate filling of the bilateral anterior cerebral arteries. In our case, probably small medial central artery perforators supplying the fornix were arising from the ACOM, hence occlusion of the ACOM led to bilateral fornix infarct and clinical amnesia. Although, amnesia as a complication of endovascular coiling of ACOM aneurysm is rare, treating physicians must be aware of this condition for two reasons. First, this complication must be explained to the patients in informed consent. Second, one must try to preserve the ACOM by remodeling techniques like balloon or stent-assisted coiling. If the neck is too wide, then probably surgical clipping should be considered in an attempt to preserve the ACOM.

Few other lacunar infarcts that were seen on the MRI, including contralateral corona radiata could be due to emboli from an occluded ACOM to the contralateral anterior cerebral artery.

In conclusion, we recommend preserving the ACOM if possible, to avoid this rare complication while treating ACOM aneurysms.

Funding

This research received no specific grant from any funding agency in the public, commercial, or not-for-profit sectors.

Conflicts of interest

None declared.

References

1. Yasuno F, Hirata M, Takimoto H, et al. Retrograde temporal order amnesia resulting from damage to the fornix. *J Neurol Neurosurg Psychiatry* 1999; 67: 102–105.
2. Hodges JR and Carpenter K. Anterograde amnesia with fornix damage following removal of IIIrd ventricle colloid cyst. *J Neurol Neurosurg Psychiatry* 1991; 54: 633–638.
3. D'Esposito M, Verfaellie M, Alexander MP, et al. Amnesia following traumatic bilateral fornix transection. *Neurology* 1995; 45: 1546–1550.
4. Moudgil SS, Azzouz M, Al-Azzaz A, et al. Amnesia due to fornix infarction. *Stroke* 2000; 31: 1418–1419.
5. Bortolon RJ, Weglinski MR and Sprung J. Transient global amnesia after general anesthesia. *Anesth Analg* 2005; 101: 916–919.
6. Levis SL. Aetiology of transient global amnesia. *Lancet* 1998; 352: 397–399.
7. Ghoneim MM. Transient global amnesia: A cause for post anesthetic memory disorder. *Anesth Analg* 1998; 87: 980–981.
8. Caplan L, Chedru F, Lhermitte F, et al. Transient global amnesia and migraine. *Neurology* 1981; 31: 1167–1170.
9. Ay H, Furie KL, Yamada K, et al. Diffusion-weighted MRI characterizes the ischemic lesion in transient global amnesia. *Neurology* 1998; 51: 901–903.
10. Alexander MP and Freedman M. Amnesia after anterior communicating artery aneurysm rupture. *Neurology* 1984; 34: 752–757.
11. Hattingen E, Rathert J, Raabe A, et al. Diffusion tensor tracking of fornix infarction. *J Neurol Neurosurg Psychiatry* 2007; 78: 655–656.
12. Graff-Radford J, Clapp AJ, Lanzino G, et al. Transient amnesia after coiling of a posterior circulation aneurysm. *Neurocritical Care* 2013; 18: 245–247.
13. Mosimann PS, Saint-Maurice JP, Lenck S, et al. Fornix infarction and Korsakoff dementia after coiling of a large anterior communicating artery aneurysm. *Neurol Clin Pract* 2012; 2: 260–262.
14. Gade A. Amnesia after operations on aneurysms of the anterior communicating artery. *Surg Neurol* 1982; 18: 46–49.