


Accepted Manuscript



A Case of Pediatric Hemorrhagic Brainstem Encephalitis Associated with HHV-7 Infection

A.J. Fay, M.J. Noetzel, S.S. Mar

PII: S0887-8994(15)00323-9

DOI: [10.1016/j.pediatrneurol.2015.06.016](https://doi.org/10.1016/j.pediatrneurol.2015.06.016)

Reference: PNU 8696

To appear in: *Pediatric Neurology*

Received Date: 6 February 2015

Revised Date: 19 June 2015

Accepted Date: 21 June 2015

Please cite this article as: Fay AJ, Noetzel MJ, Mar SS, A Case of Pediatric Hemorrhagic Brainstem Encephalitis Associated with HHV-7 Infection, *Pediatric Neurology* (2015), doi: 10.1016/j.pediatrneurol.2015.06.016.

This is a PDF file of an unedited manuscript that has been accepted for publication. As a service to our customers we are providing this early version of the manuscript. The manuscript will undergo copyediting, typesetting, and review of the resulting proof before it is published in its final form. Please note that during the production process errors may be discovered which could affect the content, and all legal disclaimers that apply to the journal pertain.

Complete Title: A Case of Pediatric Hemorrhagic Brainstem Encephalitis Associated with HHV-7 Infection

Running Title: Case of HHV-7 Hemorrhagic Encephalitis

Authors: Fay, A.J., ^{§#}Noetzel, M.J., [§] and Mar, S.S. [§]

[§] Department of Pediatric Neurology, Washington University, 660 S. Euclid Ave., Campus Box 8111, St. Louis, MO 63110-1093

[#] Corresponding Author, Division of Pediatric Neurology, Washington University, 660 S. Euclid Ave., Campus Box 8111, St. Louis, MO 63110-1093. Tel. (314) 454-6120), e-mail: faya@neuro.wustl.edu.

Keywords: Hemorrhagic Encephalitis, HHV-7, Herpesvirus, Pediatric

Word Count: Abstract 181 words, Manuscript (including abstract) 2,033 words

Abstract

Background

Human herpesviruses (HHV)-6 and -7 have been associated with febrile seizures, and also with encephalitis, the latter predominantly in immunocompromised individuals. Acute hemorrhagic encephalitis is frequently a fatal disease that can occur in the setting of viral infection, or can be a post-infectious phenomenon, often with no cause identified. While hemorrhagic encephalitis has been reported with HHV-6 infection, only a single case has been associated with HHV-7 infection, in an immunocompromised child. The role of immunosuppression is not well established in the management of this rare condition.

Patient Description

We present the case of an 11-year-old boy with hemorrhagic brainstem encephalitis, and extensive infectious and autoimmune testing positive only for HHV-7 in the CSF. The patient had a good recovery after treatment with intravenous immunoglobulin, high-dose steroids, and plasma exchange.

Discussion

This is the first reported case of hemorrhagic brainstem encephalitis with HHV-7 in a previously healthy individual, and adds to existing reports of late-onset HHV-7 infection associated with encephalitis in children. It also underscores that aggressive immunosuppression may be used early in the course of this disorder and may be beneficial for recovery.

Introduction

A wide range of viruses is associated with encephalitis and post-infectious neurological inflammatory disorders, such as Acute Disseminated Encephalomyelitis (ADEM). Related, but more severe, forms of encephalitis include acute hemorrhagic encephalitis, which can occur with a viral infection or as a post-infectious syndrome, and Acute Necrotizing Encephalitis of Childhood, which most often follows influenza A infection. Human herpesviruses (HHV) have been linked to encephalitis, predominantly in cases affecting immunocompromised individuals. While HHV-6 has been linked to hemorrhagic encephalitis in adults, HHV-7 has been implicated in only one case of hemorrhagic encephalitis, in an immunocompromised child following stem cell transplant for leukemia. We present the first reported case of a previously healthy child with acute hemorrhagic brainstem encephalitis associated with HHV-7 infection. In addition, the patient's good recovery suggests that early, aggressive immunosuppression may be helpful in this condition.

Case Presentation

An 11-year-old male with history of migraine headaches presented to the emergency department with intermittent headache, photophobia and vomiting for the past 5 days. He had had no recent fever or symptoms of infection, improved with intravenous medications, and was discharged home. He returned two days later after being found stumbling, confused, and not responding to questions, with left-sided weakness.

Upon examination, he was afebrile with normal blood pressure and heart rate, and was not speaking spontaneously, answering questions, or following commands. He had a decreased gag on the right, but otherwise no lateralizing cranial nerve findings. He had little spontaneous motor activity, but withdrew the right leg more briskly than the left. Deep tendon reflexes were diffusely 3+, with upgoing toes bilaterally. Head computed tomography was normal, but brain magnetic resonance imaging (MRI) obtained the evening of admission, showed multifocal fluid-attenuated inversion recovery (FLAIR) signal abnormalities supratentorially and infratentorially, most prominently involving the brainstem, with diffuse post-contrast enhancement in the pons and a ring-enhancing lesion in the cerebellum (Figure 1a,b). Magnetic resonance angiography (with and without contrast) and venography (without contrast) were normal. Cerebrospinal fluid (CSF) was notable for 27 nucleated cells (lymphocyte predominant), 112 red blood cells, glucose 66, and protein 30 (Table 1). CSF was sent for culture, viral studies, cytology, and flow cytometry, and the patient was started on antibiotics and acyclovir.

The patient was admitted to the Intensive Care Unit (ICU) and intubated for airway protection in the setting of poor mental status, and intravenous immunoglobulin (IVIG) was initiated on the night of admission, pending infectious and cytology results. A repeat MRI of the brain two days following admission showed increase in the pontine lesions with mass effect on the 4th ventricle, and we initiated high-dose IV corticosteroids (hospital day 3). Herpes Simplex Virus (HSV)-1 and -2 viral polymerase chain reaction (PCR) and bacterial culture were negative at this time, as was CSF flow cytometry (cytology returned one day later and was negative). Plasma exchange (5 cycles, every other day) was initiated on hospital day 4, and within two days the patient's mental, respiratory, and neurologic status improved enough to allow extubation. Further work-up for infectious, autoimmune, and paraneoplastic diseases was negative, with the exception of a positive HHV-7 PCR in the CSF (Table 1). HHV-7 PCR in a convalescent CSF specimen was negative, and HHV-7 antibodies were negative in a convalescent serum specimen after plasma exchange. Acute serum was not available for testing.

Figure 1a.

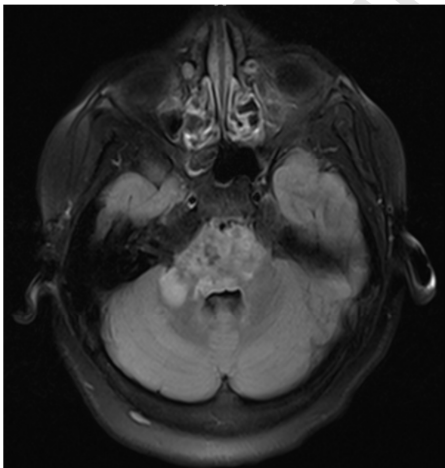


Figure 1b.

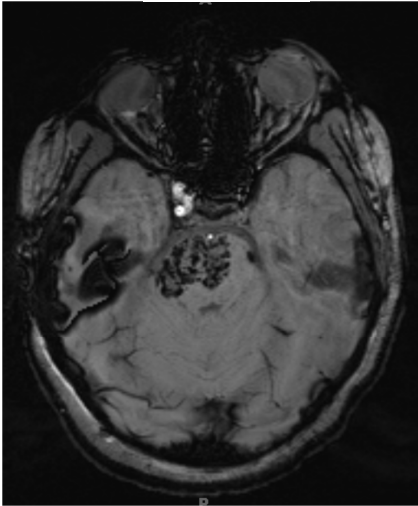


Figure 1c.

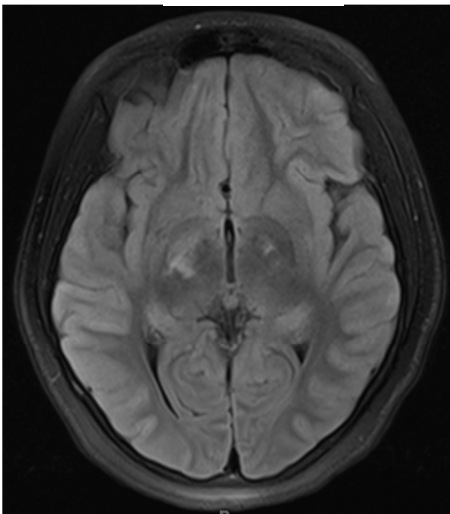


Figure 1d.

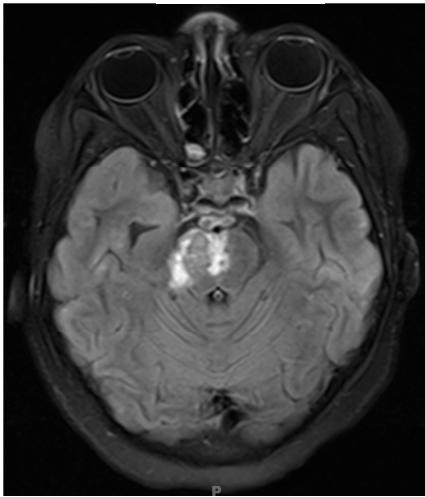
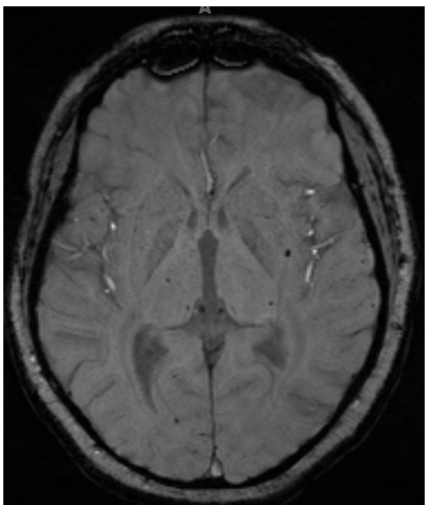


Figure 1e.



During his 10-day intensive care unit (ICU) course, the patient's alertness and spontaneous movements improved, and he was subsequently transferred to the Neurorehabilitation Service. A third MRI two weeks after admission showed resolution of most supratentorial lesions with no new lesions, scattered microhemorrhages, evolving necrosis of the pontine lesions, and no contrast enhancement. The patient's neurological

deficits all improved with inpatient rehabilitation and after discharge home, though he continues to have mild left-sided weakness, ataxia, and dysarthric speech. His Pediatric Functional Independence Measure (WeeFIM) score at discharge was 52, 90 at follow-up 5 months from admission, and 120 (out of 126 total) at his most recent follow-up 10 months after admission.

Discussion

Hemorrhagic brainstem encephalitis represents a severe end of the spectrum of para-infectious, inflammatory encephalomyelitis, which includes hemorrhagic ADEM, acute necrotizing encephalomyelitis of childhood, and acute hemorrhagic encephalitis (Hurst's disease). Other considerations in the case of our patient would include central nervous system vasculitis or hemorrhagic conversion of ischemic stroke, though his lesions did not show a diffusion restriction pattern characteristic of multifocal infarcts. While herpes simplex virus, type 1 is well known to cause hemorrhagic injury, particularly to the temporal lobes, there are also reports of hemorrhagic encephalitis associated with HHV-6, particularly in immunocompromised patients (post-organ transplantation, especially),¹ and varicella zoster virus.² In addition, hemorrhagic metastases or a primary brain tumor could produce hemorrhagic brain lesions, though this seemed unlikely based on acute and follow-up imaging, negative cytology, and the patient's steady improvement over time.

Acute hemorrhagic encephalitis, thought to be a severe form of ADEM, occurs most frequently in adults, though there are case reports of children with this aggressive, post-infectious entity.³ MRI features are variable, showing hemorrhagic and non-hemorrhagic lesions in both supratentorial and infratentorial white matter. Outcomes are generally poor, with death often occurring within days or weeks of onset,⁴ and it has been estimated that approximately 70% of survivors have significant neurological sequelae.⁵ However, there are many individual case reports of good recovery with immunosuppressive therapies.⁶ Acute necrotizing encephalopathy (ANE) of childhood, on the other hand, initially reported in Asian children following influenza A infection, tends to cause bilateral, sometimes hemorrhagic, injury to the thalami, but further reports have shown that this illness affects children worldwide and can also be associated with enterovirus infection^{7,8}. A familial form of ANE has been reported in association with mutations in the nuclear pore protein RANBP2.⁹

While HSV-1 and HHV-6 are well known to cause fulminant encephalitis, HHV-7 in the CSF has been reported in isolated cases of encephalitis, including hemorrhagic encephalitis in one post-stem cell transplant patient.¹⁰ However, interpretation of positive HHV-6 and HHV-7 PCR data is complicated by the fact that more than 90% of individuals are infected with these viruses by age 6.¹¹ Schwartz et al.¹² recently published a retrospective cohort of

pediatric patients (almost 3,000) with acute neurological illnesses and a prospective cohort of patients (260) with encephalitis and identified 57 cases of HHV-7 positive PCR in the larger cohort, of which 3 were classified as definite HHV-7 disease and 18 as possible HHV-7 disease. Two of the definite and 7 of the possible cases had encephalitis. Overall, the authors estimate that HHV-7 accounts for 1.3-5.7% of pediatric encephalitis cases.¹⁰ All cases occurred after the age of 6, suggesting that HHV-7 causes neurological illness in children with late infection. The authors defined definite cases as having positive HHV-7 PCR and elevated acute IgG titer against HHV-7. For our case, HHV-7 was positive in the acute CSF specimen and negative in convalescent CSF, but acute serum was no longer available by the time HHV-7 had been identified. A convalescent titer after plasma exchange was negative. Thus, our patient would fit Schwartz et al's categorization of "possible HHV-7 disease." He does, however, fit the age range (average 10.1 years) that the authors identified in their cohort of HHV-7 positive patients with neurological illnesses. The authors did not report any cases of hemorrhagic encephalitis.

Conclusion

This case of an 11 year-old boy with hemorrhagic brainstem encephalitis associated with HHV-7 adds to the accumulating literature about the role of this virus in a broad range of acute neurological illnesses, and is the first reported association of acute hemorrhagic encephalitis with HHV-7 in a previously healthy individual. Despite a delay in diagnosis of several days due to the non-specific presenting symptoms, and despite the severity of his symptoms and imaging findings, the patient showed dramatic improvement in neurological status following aggressive immunosuppression with steroids, plasma exchange, and IVIG. He has continued to recover well one year after discharge with ongoing rehabilitation. Our experience suggests that early immunosuppressive treatment in hemorrhagic encephalitis can be safe and beneficial.

Author Contributions: Dr. Fay provided clinical care to the patient and wrote the manuscript, and Drs. Noetzel and Mar provided clinical care to the patient and helped with editing the manuscript.

Declaration of Conflicting Interests: The authors have no conflicting interests.

- ¹ W.W. Seeley, F.M. Marty, T.M. Holmes, et al. Post-transplant acute limbic encephalitis: Clinical features and relationship to HHV6. *Neurology*, 69 (2007), pp. 156–165.
- ² Gildea D, Cohrs RJ, Mahalingam R, Nagel MA. Varicella zoster virus vasculopathies: diverse clinical manifestations, laboratory features, pathogenesis, and treatment. *Lancet Neurol*. 2009; 8 (8): 731–740.
- ³ Borlot F, da Paz JA, Casella EB, Marques-Dias MJ. Acute hemorrhagic encephalomyelitis in childhood: Case report and literature review. *J Pediatr Neurosci*. 2011 Jan;6(1):48-51. <http://dx.doi.org/10.4103/1817-1745.84408>.
- ⁴ Lann MA, Lovell MA, Kleinschmidt-DeMasters BK. Acute hemorrhagic leukoencephalitis: a critical entity for forensic pathologists to recognize. *Am J Forensic Med Pathol*. 2010 Mar;31(1):7-11.
- ⁵ Stone MJ, Hawkins CP. A medical overview of encephalitis. *Neuropsychol Rehabil*. 2007 Aug-Oct;17(4-5):429-49.
- ⁶ Ryan LJ, Bowman R, Zantek ND, Sherr G, Maxwell R, Clark HB, Mair DC. Use of therapeutic plasma exchange in the management of acute hemorrhagic leukoencephalitis: a case report and review of the literature. *Transfusion*. 2007 Jun;47(6):981-6.
- ⁷ Mastroianni SD, et al. Acute necrotizing encephalopathy of childhood in non-Asian patients: report of three cases and literature review. *J Child Neurol*. 2006 Oct;21(10):872-9. Review.
- ⁸ Tabarki B, et al. Acute necrotizing encephalopathy associated with enterovirus infection. *Brain Dev*. 2013 May;35(5):454-7. <http://dx.doi.org/10.1016/j.braindev.2012.07.001>.
- ⁹ Neilson DE, et al. Infection-triggered familial or recurrent cases of acute necrotizing encephalopathy caused by mutations in a component of the nuclear pore, RANBP2. *Am J Hum Genet*. 2009 Jan;84(1):44-51. <http://dx.doi.org/10.1016/j.ajhg.2008.12.009>.
- ¹⁰ Chan PK, Chik KW, To KF, Li CK, Shing MM, Ng KC, Yuen PM, Cheng AF. Case report: human herpesvirus 7 associated fatal encephalitis in a peripheral blood stem cell transplant recipient. *J. Med. Virol*. 2002 Apr;66(4):493-6.
- ¹¹ Ward KN. The natural history and laboratory diagnosis of human herpesviruses-6 and -7 infections in the immunocompetent. *J. Clin. Virol*. 2005;32(3):183–193.
- ¹² Schwartz KL, Richardson SE, Ward KN, Donaldson C, MacGregor D, Banwell B, Mahant S, Bitnun A. Delayed primary HHV-7 infection and neurologic disease. *Pediatrics*. 2014 Jun;133(6):e1541-7. <http://dx.doi.org/10.1542/peds.2013-3344>.

Figure Legend

Figure 1. MRI images a, b and c are from the third day of hospitalization. There is gadolinium contrast enhancement on T1 weighted images (a) and susceptibility-weighted imaging evidence of hemorrhage in the pons (b), as well as supratentorial FLAIR hyperintensities in the acute phase (c). Images d and e from a convalescent MRI two weeks following the first MRI show evolving pontine necrosis on FLAIR (d) and scattered supratentorial microhemorrhages on susceptibility-weighted imaging (e).

Table 1. Diagnostic Evaluations Sent from Blood and Cerebrospinal Fluid (CSF)

Infectious Studies	Autoimmune Studies	Acute CSF	Convalescent CSF
HHV-7 PCR+	ANA -	112 red blood cells	9 red blood cells
HHV-7 titer - (post-plasma exchange)	ANCA -	27 nucleated cells (88% Lymphocytes, 7% Monocytes, 5% Neutrophils)	3 nucleated cells (100% Lymphocytes)
HSV-1,2 PCR -	Anticardiolipin Ab -	Glucose 66	Glucose 86
VZV PCR -	Lupus Anticoagulant -	Protein 30	Protein 12
EBV PCR -	β 2-Glycoprotein Ab -	No xanthochromia	Lactate 1.9
CMV PCR -	C3 normal		Pyruvate 0.15
HHV-6 PCR -	C4 normal		2 Oligoclonal bands
Arboviral titers -	NMDA Receptor Ab-		IgG Synthesis rate <1
Bartonella titers -	Direct Coombs+		IgG index < 1.00
Mycoplasma titer -	NMO Ab -		No xanthochromia
Toxoplasma PCR -	Paraneoplastic Panel -		
Histoplasma titer -			
Cryptococcal antigen -			
HIV-			
Nasopharyngeal Swab Respiratory Viruses -			