




Official Journal of the European Paediatric Neurology Society



Case Study

Anaplastic astrocytoma mimicking herpes simplex encephalitis in 13-year old girl



Saurabh Talathi ^{a,b}, Neha Gupta ^a, Naresh Reddivalla ^{a,c},
Sergey Prokhorov ^{a,*}, Menachem Gold ^{d,e}

^a Department of Pediatrics, Lincoln Medical Center, Bronx, United States

^b University of Texas, School of Public Health, Houston, TX, United States

^c Children's Mercy Hospital, Kansas City, United States

^d Weill Cornell Medical Center, NY, United States

^e Department of Radiology, Lincoln Medical Center, Bronx, United States

ARTICLE INFO

Article history:

Received 31 December 2014

Accepted 13 July 2015

Keywords:

Anaplastic astrocytoma

HSV encephalitis

Brain tumor

Radiodiagnosis

ABSTRACT

Astrocytoma is the most common childhood brain tumor. Anaplastic astrocytoma (AA) are high grade gliomas (HGG), found very rarely in pediatric patients. AA mainly results from a dedifferentiation of a low grade astrocytoma. Clinical features of supra-tentorial tumors vary according to their anatomic location, biologic aggressiveness and age of the patient. They can be either completely asymptomatic or present with signs of raised intracranial pressure, seizures (about 40% of cases), behavior changes, speech disorders, declining school performance, or hemiparesis. There have been published adult cases of brain tumor misdiagnosed as viral encephalitis. Due to variety of clinical presentations, diagnosis of AA can be challenging. Here we report a case of a 13 year old girl who presented with clinical features suggestive of viral encephalitis, such as fever, headache, dizziness, and first seizure with postictal sleep and prolonged drowsiness. However, her brain MRI findings were consistent with long standing mass effect from the underlying intracranial contents and that coupled with her history of unusual taste led to further investigations and the diagnosis of the AA. In retrospect, this presentation could have been a temporal epileptic aura.

High grade astrocytomas are particularly difficult to treat with a two-year survival rates range from 10% to 30%. The treatment is multimodal with gross total surgical resection of the tumor, followed by radiotherapy with or without nitrosourea-containing chemotherapy regimen. Recent promising results seen with the use of temozolamide in adults has not been yet demonstrated in the pediatric patients. The extent of tumor resection remains the most significant indicator of survival and early recognition of this tumor is essential.

This case report emphasizes the fact that mass lesions in the temporal lobe, including high-grade astrocytoma, should be considered in the differential diagnosis of suspected herpes simplex encephalitis, especially those not responding to therapy. Remodeling of the calvarium adjacent to an intracranial lesion suggests a long standing process.

© 2015 European Paediatric Neurology Society. Published by Elsevier Ltd. All rights reserved.

* Corresponding author.

E-mail address: sproxy113@gmail.com (S. Prokhorov).

<http://dx.doi.org/10.1016/j.ejpn.2015.07.007>

1090-3798/© 2015 European Paediatric Neurology Society. Published by Elsevier Ltd. All rights reserved.

1. Case

A 13-year-old previously healthy girl presented to the pediatric emergency department (ED) with a 2-day history of sore throat, headache, dizziness and fever (T max-101 F). Remainder of the review of systems was normal and there was no history of recent travel or sick contact.

In the ED, the patient's vital signs were as follows: temperature 102 °F, heart rate 102 beats/min, respiratory rate 22 breaths/min, blood pressure 117/80 mm Hg and oxygen saturation of 100% on room air. Her weight was 75th percentile and her height 50th percentile for age. Physical examination was unremarkable. In particular, she had a normal neurological examination with negative meningeal signs and normal fundal exam. While in the ED, she became agitated and started complaining of shortness of breath. Her agitation and hyperventilation were assessed as an anxiety attack. After a dose of Benadryl she briefly fell asleep. However, a few minutes after waking up, she demonstrated a blank stare and was unresponsive. Generalized convulsion 2–3 min in duration ensued, followed by postictal sleep. She received intravenous lorazepam.

Initial laboratory evaluations revealed normal complete blood counts, basic metabolic panel, urine analysis, procalcitonin, C-reactive protein and liver function tests. A urine toxicology screen was negative. Computed tomography (CT) scan showed hypo-attenuation within the right temporal lobe suggestive of edema (Fig. 1). Given the patient's presentation and temporal lobe abnormality on imaging, viral encephalitis was suspected.

Cerebrospinal fluid (CSF) analysis revealed colorless fluid, no red blood cells, 2 white blood cells, glucose 76 mg/dL (blood glucose 99 mg/dL), and protein 39 mg/dL. CSF was sent for culture, Herpes simplex virus (HSV) polymerase chain reaction (PCR), Enterovirus PCR, and West Nile antibody. The patient was hospitalized, blood cultures drawn and empiric antibiotics were started. On the 1st day of hospitalization the patient was without seizure recurrence, afebrile, completely oriented but drowsy. Neurological examination remained grossly normal. Fundoscopy showed sharp discs' margin in both eyes. Due to febrile illness with GCTS, and abnormal CT scan findings in the right temporal lobe, the patient was treated for presumed HSV encephalitis with Acyclovir.

Magnetic resonance imaging (MRI) of the brain, performed on day one of admission, revealed T2 hyperintense signal and cortical swelling within the anterior and medial right temporal lobe, with effacement of the right sylvian fissure and temporal horn. While these findings alone may be consistent with HSV encephalitis, additional findings on the MRI and further history from the parents suggested otherwise (Figs. 2–4). MRI also showed subtle remodeling of the right lateral orbital wall and greater sphenoid wing with medial displacement of the right lateral rectus muscle and mild right exophthalmos. These findings were consistent with long standing mass effect from the underlying brain parenchyma. On additional inquiry, the parents admitted that one month prior the child had complained about repetitive episodes of funny taste in her mouth.

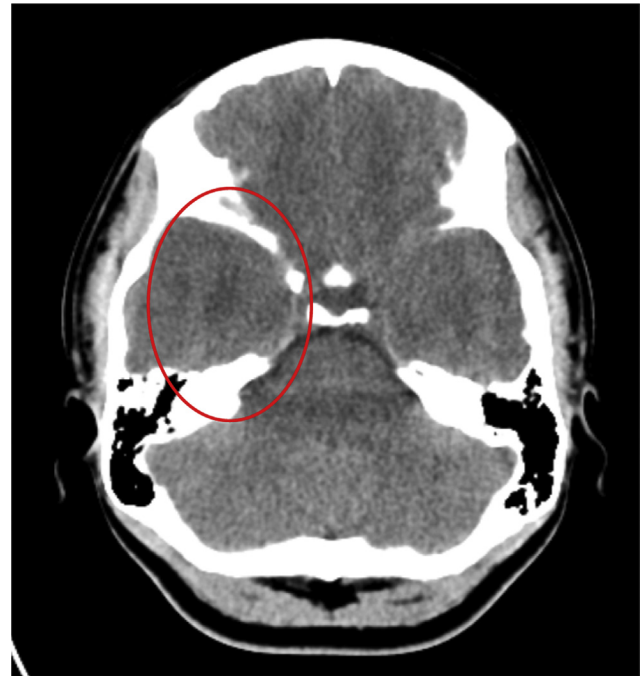


Fig. 1 – Hypoattenuation within the right temporal lobe white matter consistent with edema.

The patient was evaluated by a neurosurgeon and biopsy revealed grade III anaplastic astrocytoma of the right temporal lobe.

The patient received dexamethasone to reduce vasogenic edema associated with the tumor. Three weeks later she underwent extensive resection of the tumor followed by a 6-week course of adjuvant radiotherapy. Subsequently,

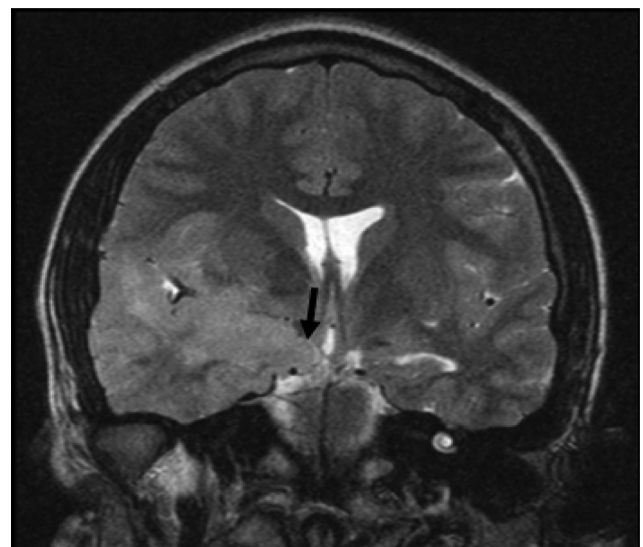


Fig. 2 – Coronal T2 weighted image demonstrates hyperintense signal in the right insula and temporal lobe, involving the cortex and subcortical white matter. There is swelling of the involved brain parenchyma, with effacement of the right Sylvian fissure and temporal horn. Note involvement of the uncus and hippocampus (arrow).

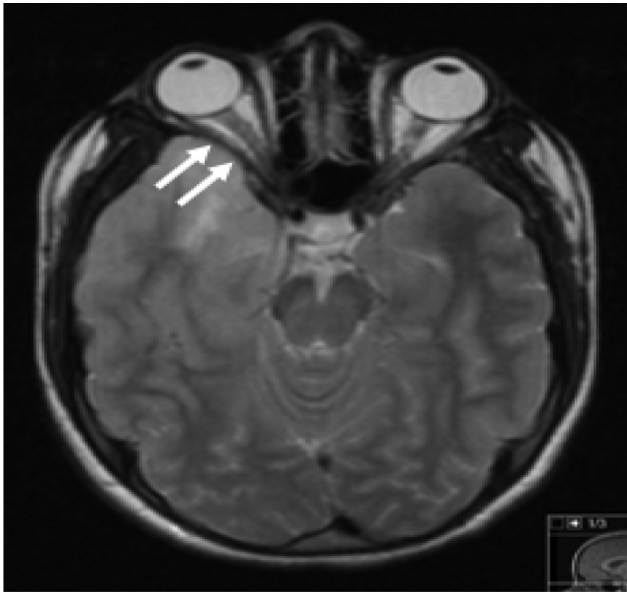


Fig. 3 – Axial T2 weighted image demonstrates hyperintense signal in the right temporal lobe. Note subtle remodeling of the right lateral orbital wall (arrows) with compression of the lateral rectus muscle and mild right exophthalmos. Bone remodeling suggests a long-standing underlying parenchymal process such as an infiltrative glioma.

chemotherapy with temozolamide was initiated. The patient has not had seizure recurrence, including paroxysms of funny taste.

2. Discussion

Astrocytoma is the most common childhood brain tumor, constituting approximately half of all pediatric supratentorial

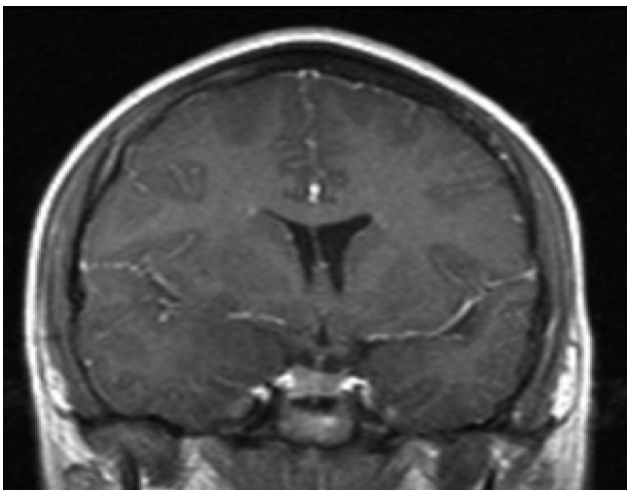


Fig. 4 – Post contrast coronal image demonstrates no abnormal enhancement.

tumors. Anaplastic astrocytoma (WHO grade III), and glioblastoma multiforme (WHO grade IV) are high grade gliomas (HGG). They are rare in pediatric patients, with glioblastomas and anaplastic astrocytomas accounting for 2.8% and 1.9%, respectively, of CNS tumors in children.¹ In contrast to those in adults, high grade astrocytomas in children very rarely evolve from a low-grade astrocytoma.^{2–4} AA mainly results from a dedifferentiation of a low grade astrocytoma, however, de novo development of AA has been reported.⁵

Anaplastic astrocytoma may anywhere in the CNS but most commonly develops in the cerebrum, particularly the frontal and temporal lobes. The brain stem and spinal cord are the next most frequently affected sites, whereas the cerebellum is a distinctly uncommon site. Clinical features of supratentorial tumors vary according to their anatomic location, biologic aggressiveness and age of the patient.⁶ They can be either completely asymptomatic or present with signs of raised intracranial pressure, seizures (about 40% of cases), behavior changes, speech disorders, declining school performance, or hemiparesis.

3. Diagnosis

Due to variety of clinical presentations, diagnosis of AA can be challenging. Our patient presented with clinical features suggestive of viral encephalitis, such as fever, headache, dizziness, and first seizure with postictal sleep and prolonged drowsiness. HSV encephalitis was under consideration with assumption that clinical presentation of the encephalitis can be atypical especially at the onset.⁷ Brain MRI revealed hyperintensity in the right medial temporal lobe which is a common site of HSV infection. However, remodeling of the lateral orbital wall and sphenoid wing is consistent with long standing mass effect from the underlying intracranial contents. In retrospect, this presentation could have been a temporal epileptic aura. The patient also recollected the same taste in her mouth right before the first generalized convulsion. There have been published adult cases of brain tumor misdiagnosed as viral encephalitis.^{8–12} Seizures may precede diagnosis by several months to 1–2 years. In our patient epileptic gustatory auras happened within one month before the first generalized convulsive seizure.

4. Management

High grade astrocytomas are particularly difficult to treat and usually do not respond to even the most aggressive therapies. Two-year survival rates range from 10% to 30% for supratentorial pediatric high grade gliomas.¹³ The treatment is multimodal with gross total surgical resection of the tumor, followed by radiotherapy with or without nitrosourea-containing chemotherapy regimen.¹⁴ Recent promising results seen with the use of temozolamide in adults has not been yet demonstrated in the pediatric patients. The extent of tumor resection remains the most significant indicator of survival.

Lessons for the clinician

Mass lesions in the temporal lobe, including high-grade astrocytoma, should be considered in the differential diagnosis of suspected herpes simplex encephalitis, especially not responding to therapy. Remodeling of the calvarium adjacent to an intracranial lesion suggests a long standing process such as a neoplasm.

Author disclosure

Naresh Reddivalla, MD; Saurabh Talathi, MD, MPH; Neha Gupta, MD; Sergey Prokhorov, MD; Menachem Gold, MD have disclosed no financial relationships relevant to this article. This commentary does not contain a discussion of an unapproved/investigative use of a commercial product/device.

Conflict of interest

Naresh Reddivalla, MD; Saurabh Talathi, MD, MPH; Neha Gupta, MD; Sergey Prokhorov, MD; Avinash Mohan; Menachem Gold, MD have read the article and have no conflict of interest for the same. They have disclosed no financial relationships relevant to this article. This commentary does not contain a discussion of an unapproved/investigative use of a commercial product/device.

REFERENCES

1. Kaatsch P, Rickert CH, Kuhl J, Schuz J, Michaelis J. Population-based epidemiologic data on brain tumors in German children. *Cancer* 2001;92:3155–64.
2. 1975-2009 NCISCSR. Adolescent and young adult cancer by site incidence, survival and mortality.
3. Tanaka S, Meyer FB, Buckner JC, Uhm JH, Yan ES, Parney IF. Presentation, management, and outcome of elderly patients with newly-diagnosed anaplastic astrocytoma. *J Neuro-oncol* 2012 Nov;110(2):227–35. PubMed PMID: 22875708.
4. See SJ, Gilbert MR. Anaplastic astrocytoma: diagnosis, prognosis, and management. *Seminars Oncol* 2004 Oct;31(5):618–34. PubMed PMID: 15497115.
5. Mechtler L. Neuroimaging in neuro-oncology. *Neurol Clin* 2009 Feb;27(1):171–201. ix. PubMed PMID: 19055979.
6. Kleihues P, Sobin LH. World Health Organization classification of tumors. *Cancer* 2000 Jun 15;88(12):2887. PubMed PMID: 10870076.
7. De Tiège Xavier, Rozenberg Flore, Héron Bénédicte. The spectrum of herpes simplex encephalitis in children. *Eur J Paediatr Neurol* 2008;12:72–81.
8. Domingues Renan B, Lakeman Fred D, Pannuti Cláudio S, Fink Maria Cristina D, Tsanaclis Ana Maria C. Advantage of polymerase chain reaction in the diagnosis of herpes simplex encephalitis: presentation of 5 atypical cases. *Scand J Infect Dis* 1997;29(3):229–31.
9. Rees JH, Howard RS. High-grade glioma mimicking acute viral encephalitis -three case reports. *Postgrad Med J* 1999;75:728–43.
10. Bell DJ, Suckling R, Rothburn MM, Blanchard T, Stoeter D, Michael B, et al. Management of suspected herpes simplex virus encephalitis in adults in a U.K. teaching hospital. *Clin Med* 2009 Jun;9(3):231–5. PubMed PMID: 19634384.
11. Solomon T, Michael BD, Smith PE, Sanderson F, Davies NW, Hart IJ, et al. Management of suspected viral encephalitis in adults—Association of British Neurologists and British Infection Association National Guidelines. *J Infect* 2012 Apr;64(4):347–73. PubMed PMID: 22120595.
12. Smithson E, Larner AJ. Glioblastoma multiforme masquerading as herpes simplex encephalitis. *Br J Hosp Med* 2013 Jan;74(1):52–3. PubMed PMID: 23593680.
13. Broniscer A, Gajjar A. Supratentorial high-grade astrocytoma and diffuse brainstem glioma: two challenges for the pediatric oncologist. *Oncologist* 2004;9:197–206.
14. MacDonald TJ, Aguilera D, Kramm CM. Treatment of high-grade glioma in children and adolescents. *Neuro-Oncology* 2011;13(10):1049–58.