

Middle Cerebral Artery Occlusion Presenting as Upper Limb Monochorea

Kazuyuki Noda, MD, PhD,* Sho Nakajima, MD,*† Fuyuko Sasaki, MD,*†
Yoshitaka Ito, MD, PhD,‡ Sumihiro Kawajiri, MD, PhD,* Yuji Tomizawa, MD, PhD,*
Nobutaka Hattori, MD, PhD,† Takuji Yamamoto, MD, PhD,‡
and Yasuyuki Okuma, MD, PhD*

Background: Hemichorea is usually caused by a structural lesion in the contralateral basal ganglia or subthalamic nuclei or it develops as a form of a neurologic complication including hyperglycemia. We report a rare case of a patient who developed choreic movement in the right upper extremity associated with a contralateral middle cerebral artery (MCA) occlusion. *Methods:* A 76-year-old man presented with chorea in the right upper limb, known as monochorea, which occurred after recovery from losing consciousness while standing. He was found to have idiopathic orthostatic hypotension. His diffusion-weighted magnetic resonance imaging did not show signal changes indicative of acute ischemic lesions. A left carotid artery angiogram showed occlusion of the left MCA. ¹²³I-N-isopropyl-4-iodoamphetamine single-photon emission computed tomography of the brain showed marked hypoperfusion in the left MCA territory. His cerebrovascular reserve capacity determined using acetazolamide was relatively decreased in this territory. This decrease in cerebrovascular reserve capacity, however, did not require surgical treatment, such as extracranial-intracranial bypass surgery. *Results:* The recurrence of chorea was not observed after antiplatelet therapy and instruction on how to cope with orthostatic hypotension. *Conclusions:* It is considered that transient hemodynamic ischemia in the right basal ganglia-thalamocortical circuits because of the combination of MCA occlusion and hypotension was the underlying cause of the monochorea in this patient. Vascular imaging studies for early identification of occlusion or severe stenosis of cerebral major arteries should be carried out in patients acutely presenting with chorea, even in the absence of other clinical signs. **Key Words:** Chorea—TIA—middle cerebral artery occlusion—cerebral blood flow.

© 2015 by National Stroke Association

From the *Department of Neurology, Juntendo University Shizuoka Hospital, Izunokuni, Shizuoka; †Department of Neurology, Juntendo University School of Medicine, Bunkyo, Tokyo; and ‡Department of Neurosurgery, Juntendo University Shizuoka Hospital, Izunokuni, Shizuoka, Japan.

Received April 13, 2015; revision received May 30, 2015; accepted June 10, 2015.

Address correspondence to Kazuyuki Noda, MD, Department of Neurology, Juntendo University Shizuoka Hospital, 1129 Nagaoka, Izunokuni, Shizuoka 410-2295, Japan. E-mail: k-noda@juntendo.ac.jp.
1052-3057/\$ - see front matter

© 2015 by National Stroke Association

<http://dx.doi.org/10.1016/j.jstrokecerebrovasdis.2015.06.009>

Case Report

A 76-year-old man was brought to our hospital in an ambulance and admitted to our department after losing consciousness without seizures while standing during work. Two minutes after he lost consciousness, he completely regained consciousness, but he developed an involuntary movement in his right arm. His blood pressure obtained on arrival by the ambulance crew was 120/72 mm Hg. The involuntary movement persisted for 2 hours. Since the age of 56, he had experienced syncope of unknown cause 6 times. He had no family history of movement disorders. He had been diagnosed as having hypertension by his primary care physician, and antihypertensive medications had been administered for 1 year, which he stopped taking on his own 5 months previously. He also had a long history of tobacco smoking, which he quit 5 years previously. Neurologic examination findings were unremarkable except for the monochorea in his right upper limb. His low-density lipoprotein cholesterol level was in the range from 136 to 157 mg/dL (normal range 70-139 mg/dL). No antinuclear antibodies, lupus anticoagulant activity, or anticardiolipin antibodies were detected. No acute infarcts in the basal ganglia or fron-

toparietal lobes were noted on his diffusion-weighted magnetic resonance images (Fig 1, A,B) and apparent diffusion coefficient map (data not shown). Two routine electroencephalograms showed normal findings. His supine blood pressure was 120/70 mm Hg and his blood pressure within 3 minutes of standing was 75/46 mm Hg, with no heart rate change. No M1 portion of the left middle cerebral artery (MCA) was detected in his 3-dimensional angiogram (Fig 1, C). There were no abnormal net-like collateral vessels (moyamoya vessels). Arteriosclerotic changes were postulated to be a cause of the left MCA occlusion on the basis of the presence of arteriosclerotic risk factors. The leptomeningeal anastomosis through the left anterior cerebral artery and posterior cerebral artery supplied the major part of the left hemisphere (Fig 1, D). The cerebral blood flow detected by ^{123}I -N-isopropyl-4-iodoamphetamine single-photon emission computed tomography of the brain was markedly decreased in the left MCA territory (Fig 1, E). The reserve capacity measured using acetazolamide was relatively decreased compared with the right MCA territory (Fig 1, F). His vascular reserve capacity was recorded as more than 10%. He was treated with clopidogrel (75 mg daily) and rosuvastatin (2.5 mg daily). To avoid orthostatic hypotension, we

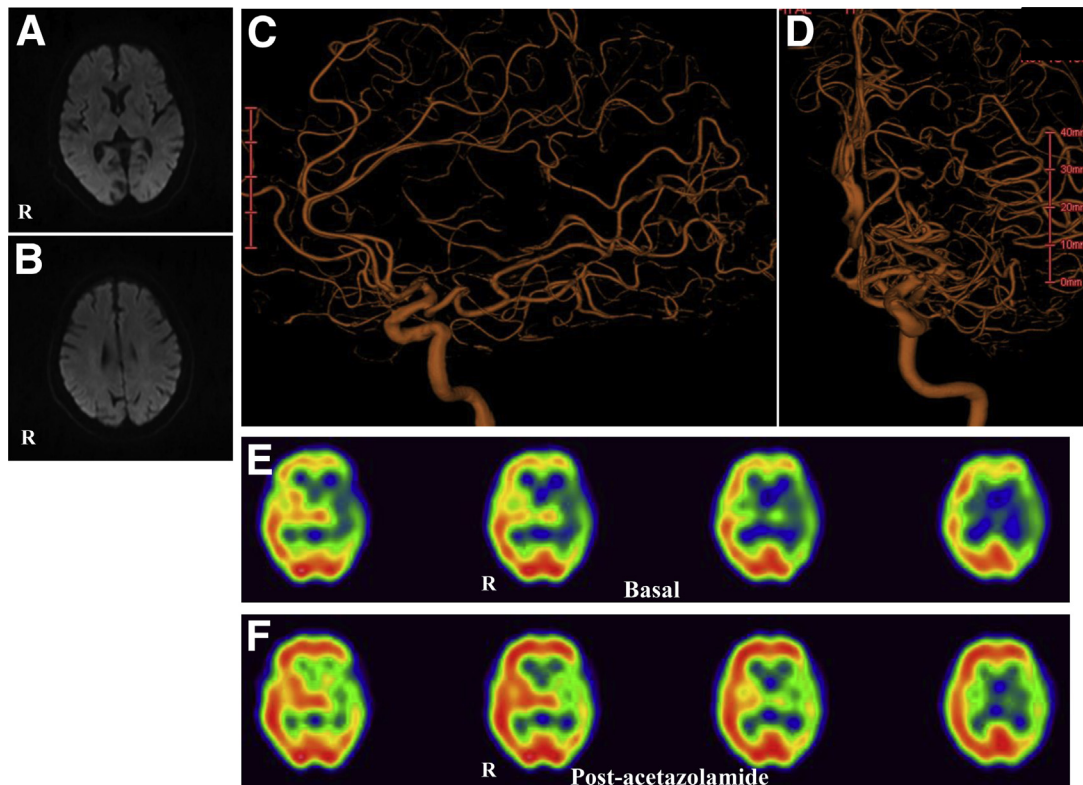


Figure 1. (A and B). Diffusion-weighted magnetic resonance images showing no high signal intensities in the basal ganglia or frontoparietal lobes. (C). Left carotid 3-dimensional angiogram (3D) showing occlusion of left middle cerebral artery (MCA). (D) Left carotid 3D angiogram showing filling of some MCA branches through the left anterior and posterior cerebral artery. (E) Basal perfusion on ^{123}I -N-isopropyl-4-iodoamphetamine single-photon emission computed tomography images showing hypoperfusion in left hemisphere including basal ganglia. (F) After acetazolamide infusion, the cerebral vascular reserve capacity was more than 10%.

recommended that he should wear elastic stockings and avoid prolonged standing. At 6 months, he remained symptom free.

Discussion

Several cases of hemichorea secondary to carotid occlusive disease have been reported.¹⁻⁴ Monochorea caused by MCA occlusion is rare.^{5,6} This case was an unusual form of transient ischemic attack, in which vascular occlusion combined with hypotension resulted in severe focal cerebral hypoperfusion, causing monochorea. Orthostatic hypotension has long been recognized as a risk factor for transient ischemic attack and stroke in the setting of occlusive cerebrovascular disease.^{7,8} Chronic occlusion of the left MCA remained asymptomatic in this patient because of sufficient collateral flow to the MCA territory to maintain normal neural function. Once acute hypotension occurred in addition to this condition, collateral reserve and cerebral autoregulation could not maintain a sufficient cerebral blood flow. Early recognition of chorea as a marker of possible cerebrovascular ischemia may prevent subsequent ischemic events.

References

1. Morigaki R, Uno M, Suzue A, et al. Hemichorea due to hemodynamic ischemia associated with extracranial carotid artery stenosis. Report of two cases. *J Neurosurg* 2006; 105:142-147.
2. Galea I, Norwood F, Phillips MJ, et al. Pearls & Oysters: resolution of hemichorea following endarterectomy for severe carotid stenosis. *Neurology* 2008;71:e80-e82.
3. Pareés I, Pujadas F, Hernández-Vara J, et al. Reversible hemichorea associated with extracranial carotid artery stenosis. *J Neurol Sci* 2011;300:185-186.
4. Littleton ET, Glover N, Tiwari A. Recurrent amaurosis fugax and hemichorea: limb-shaking TIA. *Pract Neurol* 2015; 15:218-220.
5. Irioka T, Ayabe J, Mizusawa H. Hemichorea improved by extracranial-intracranial bypass surgery for middle cerebral artery occlusion. *J Neurol* 2010;257:1756-1758.
6. Kim JM, Kim JS, Cho AH, et al. Angioplasty of middle cerebral artery stenosis improves recurrent hemichorea caused by basal ganglia hypoperfusion. *J Stroke Cerebrovasc Dis* 2006;15:69-71.
7. Dobkin BH. Orthostatic hypotension as a risk factor for symptomatic occlusive cerebrovascular disease. *Neurology* 1989;39:30-34.
8. Cheshire WP Jr, Meschia JF. Postprandial limb-shaking: an unusual presentation of transient cerebral ischemia. *Clin Auton Res* 2006;16:243-246.