

CASE REPORT

Open Access



Case report of a young stroke patient showing interim normalization of the MRI diffusion-weighted imaging lesion

Ann-Christin Ostwaldt^{1*}, Tatiana Usnich², Christian H. Nolte^{1,2}, Kersten Villringer¹ and Jochen B. Fiebach¹

Abstract

Background: In acute ischemic stroke, diffusion weighted imaging (DWI) shows hyperintensities and is considered to indicate irreversibly damaged tissue. We present the case of a young stroke patient with unusual variability in the development of signal intensities within the same vessel territory.

Case presentation: A 35-year-old patient presented with symptoms of global aphasia and hypesthesia of the left hand. MRI demonstrated a scattered lesion in the MCA territory. After rtPA therapy the patient received further MRI examination, three times on day 1, and once on day 2, 3, 5 and 43. The posterior part of the lesion showed the usual pattern with increasing DWI hyperintensity and decreased ADC, as well as delayed FLAIR positivity. However, the anterior part of the lesion, which was clearly visible in the first examination completely normalized on the first day and only reappeared on day 2. This was accompanied by a normalization of the ADC as well as an even further delayed FLAIR positivity.

Conclusion: We showed that interim normalization of DWI and ADC in the acute phase can not only be found in rodent models of stroke, but also in humans. We propose that DWI lesion development might be more variable during the first 24 h after stroke than previously assumed.

Keywords: Magnetic resonance imaging, Acute ischemic stroke, Time course, Normalization

Background

Acute cerebral ischemia can be visualized with MRI diffusion weighted imaging (DWI) within minutes after its onset [1]. It has been suggested that in the majority of human stroke patients DWI positive cerebral ischemia indicate irreversible tissue damage leading to infarction [2]. However, lately reversal of parts of the DWI lesion has been demonstrated in association with early recanalization [3–5]. In animal models the occurrence of interim or sustained normalization of both DWI and apparent diffusion coefficient (ADC) seem to depend on the occlusion times [6, 7]. In contrast to DWI, lesions on fluid-attenuated inversion recovery (FLAIR) are usually seen several hours after stroke onset [8] in humans.

Here we present a case of partial interim normalization of DWI and ADC visualized with serial MRI in a young stroke patient.

Case presentation

A 35 year old female patient was admitted with incomplete global aphasia and a fluctuating slight hypesthesia of the left hand. Her baseline National Institutes of Health Stroke Scale score (NIHSS) was 4 and arterial hypertension was the only vascular risk factor. The patient was repeatedly examined in the MRI 57 min as well as 3.3 h, 5.5 h and 7.6 h after symptom onset, and on the second, third, fifth and 43rd day post-stroke. These data were obtained from the prospective 1000Plus Study (NCT00715533). The patient gave written informed consent. At baseline, the anterior M2 branch of the right middle cerebral artery (MCA) was occluded. DWI showed a scattered lesion affecting the anterior and posterior part of the right MCA territory and perfusion imaging showed a corresponding deficit. Intravenous rt-PA

* Correspondence: aostwaldt@mgh.harvard.edu

¹Center for Stroke Research Berlin (CSB), Charité Universitätsmedizin Berlin, Hindenburgdamm 30, 12200 Berlin, Germany

Full list of author information is available at the end of the article

was administered directly after the first MRI scan. The follow-up examinations showed a patent MCA branch 5.5 h after symptom onset, complete normalization of the perfusion deficit on day 2 and no signs of hemorrhagic transformation. The patient's symptoms had substantially improved, resulting in a NIHSS of 0 at discharge. Infarct size on FLAIR was 31.76 ml at day 5.

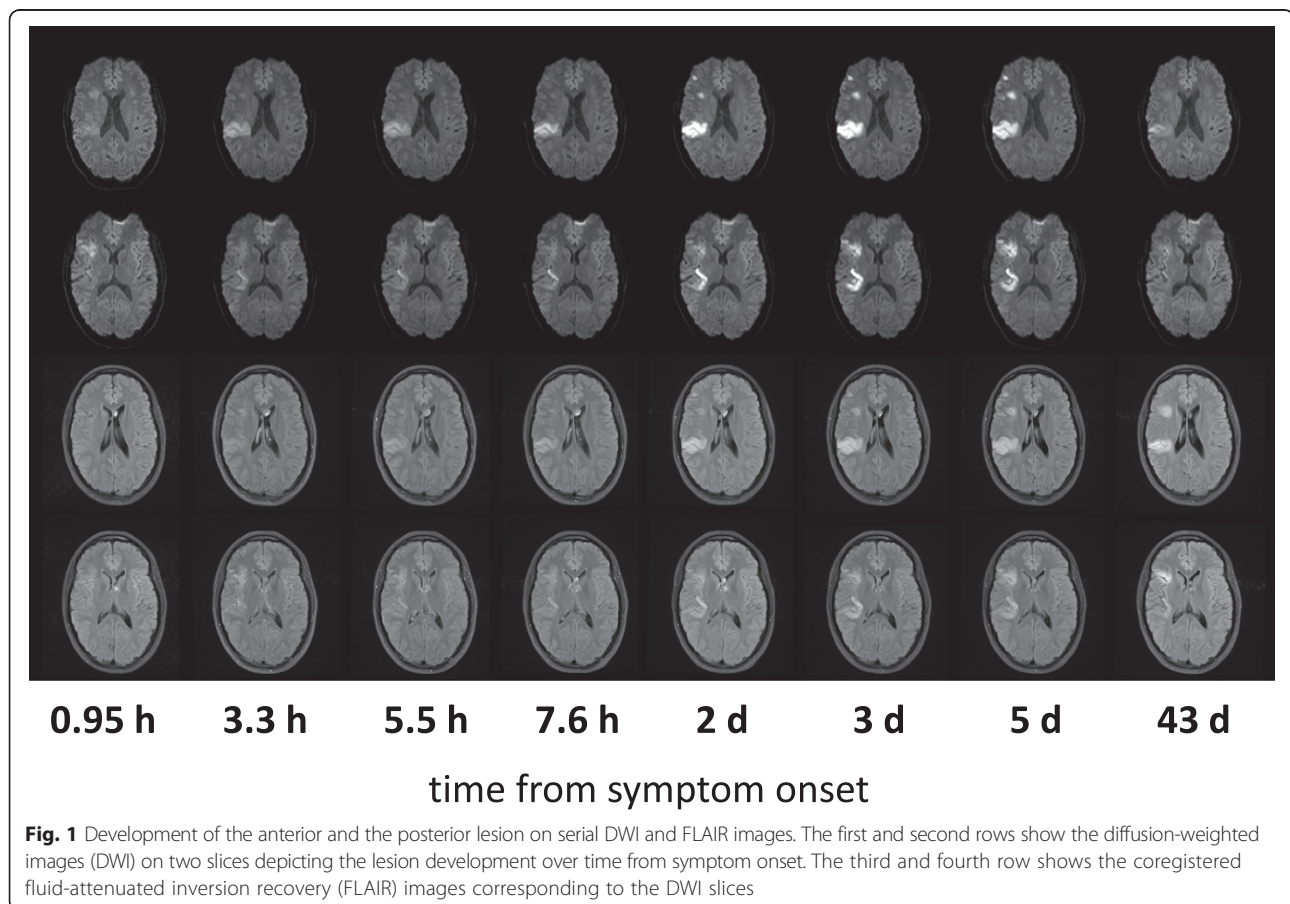
On the first examination 57 min after onset, the anterior part of the lesion was clearly hyperintense on DWI; however, on the second examination at 3.3 h it was not visible any more and did not reappear until day 2 (Fig. 1). For a more detailed analysis of this phenomenon, the image datasets for each time point were coregistered and regions-of-interest (ROIs) for both the anterior and the posterior part of the lesion were created on DWI day 5 images. Signal intensities (rSI) were determined relative to the contralateral side, as previously described [8].

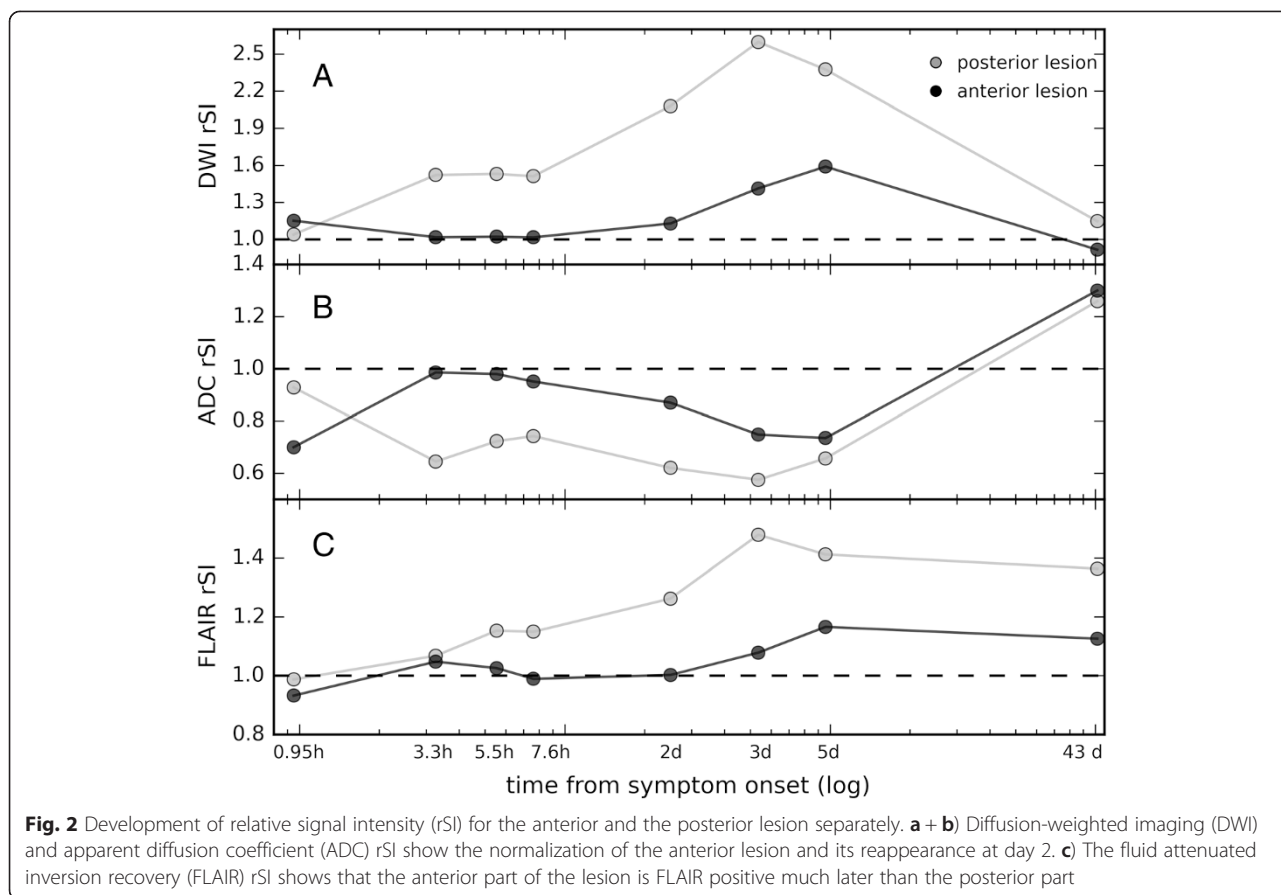
As can be seen in Fig. 2, DWI and ADC rSI values of the anterior lesion normalized for the time period between 3.3 h and 25 h after symptom onset (Fig. 2a-b). Also, the fluid-attenuated inversion recovery (FLAIR) rSI values of the anterior lesion were much lower than the values of the posterior lesion and only at day 3 post-

stroke did the FLAIR rSI in the anterior lesion reach values substantially different from 1 (Fig. 2c).

Conclusions

We demonstrated that the degree and time course of DWI hyperintensities can differ within one lesion in the first day after stroke. To the best of our knowledge, this is the first time that the exact time course of DWI reversal and reappearance was visualized using highly repetitive MRI examinations. Our findings resemble those in rodent models of stroke [6], where lesions normalized on the DWI and ADC after recanalization and reappeared at day 2 after stroke. In stroke patients, reversible DWI hyperintensities have been demonstrated for very small, mainly embolic lesions [9]. Also it has been shown that recanalization (either after intraarterial or intravenous thrombolysis) could evoke DWI lesion reversal in some patients, with parts of lesion showing later reappearance [3–5]. Therefore, we hypothesize, that a possible explanation for the interim normalization of a large part of the initial lesion in our case would be the fast recanalization and reperfusion of the tissue. It therefore seems that the baseline DWI lesion contains tissue with benign oligemia and only cell damage which could not





be prevented will reveal itself on follow-up examinations. It might well be possible, that an interim normalization as observed in our case is more common in stroke patients. However, this will rarely be observed due to lack of MRI follow-ups in clinical routine.

We conclude that DWI lesion visibility might be more prone to fluctuation and variability during the first 24 h after stroke than previously assumed and baseline DWI may include tissue with benign oligemia. Therefore, during interpretation of DWI one has to keep in mind that an interim normalization can occur and which might delay lesion visualization.

Abbreviations

MRI: Magnetic resonance imaging; DWI: Diffusion-weighted imaging; ADC: Apparent diffusion coefficient; NIHSS: National Institutes of health stroke scale; MCA: Middle cerebral artery; ROI: Region-of-interest; rSI: Relative signal intensity; FLAIR: Fluid-attenuated inversion recovery.

Competing interests

The authors declare that they have no competing interests.

Authors' contributions

AO was responsible for analyzing and interpreting the imaging data. She generated the figures and drafted the manuscript. TU and CN were the responsible treating physicians of the patients. TU additionally helped analyzing the data. CN was responsible for the data collection on the clinical side and made contributions to interpretation of the results. KV participated in design and coordination of the study and substantially helped in

interpreting the results and drafting the manuscript. JF was responsible for conception and design of the study and agree to be accountable for accuracy or integrity of the work. All authors read and approved the final manuscript.

Acknowledgements

This research received funding from the Federal Ministry of Education and Research via the grant Center for Stroke Research Berlin (01EO0801 and 01EO1301).

Consent

Written informed consent was obtained from the patient for publication of this case report and any accompanying images. A copy of the written consent is available for review by the editor of this journal.

Author details

¹Center for Stroke Research Berlin (CSB), Charité Universitätsmedizin Berlin, Hindenburgdamm 30, 12200 Berlin, Germany. ²Department of Neurology, Charité Universitätsmedizin Berlin, Hindenburgdamm 30, 12200 Berlin, Germany.

Received: 19 January 2015 Accepted: 14 August 2015

Published online: 25 August 2015

References

1. Moseley M, Cohen Y, Mintorovitch J, Chileuitt L, Shimizu H, Kucharczyk J, et al. Early detection of regional cerebral ischemia in cats: comparison of diffusion-weighted and T2-weighted MRI and spectroscopy. *Magn Reson Med.* 1990;14:330–46.
2. Fiehler J, Fiebich JB, Gass A, Hoehn M, Kucinski T, Neumann-Haefelin T, et al. Diffusion-weighted imaging in acute stroke – a tool of uncertain value? *Cerebrovasc Dis.* 2002;14:187–96.

3. Soize S, Tisserand M, Charron S, Turc G, Ben Hassen W, Labeyrie MA, et al. How sustained is 24-h diffusion-weighted imaging lesion reversal? Serial magnetic resonance imaging in a patient cohort thrombolized within 4.5 h of stroke onset. *Stroke*. 2015;46:704–10.
4. Kidwell CS, Saver JL, Starkman S, Duckwiler G, Jahan R, Vespa P, et al. Late secondary ischemic injury in patients receiving intraarterial thrombolysis. *Ann Neurol*. 2002;52:698–703.
5. Sakamoto Y, Kimura K, Iguchi Y, Shibazaki K, Aoki J. Dramatic changes of a DWI lesion in a patient with acute ischemic stroke treated with IV t-PA. *J Neuroimaging*. 2013;23:228–30.
6. Neumann-Haefelin T, Kastrup A, de Crespigny A, Yenari MA, Ringer T, Sun GH, et al. Serial MRI after transient focal cerebral ischemia in rats: dynamics of tissue injury, blood–brain barrier damage, and edema formation. *Stroke*. 2000;31:1965–72.
7. Li F, Liu KF, Silva MD, Omae T, Sotak CH, Fenstermacher JD, et al. Transient and Permanent Resolution of Ischemic Lesions on Diffusion-Weighted Imaging After Brief Periods of Focal Ischemia in Rats: Correlation With Histopathology. *Stroke*. 2000;31:946–54.
8. Cheng B, Brinkmann M, Forkert ND, Treszl A, Ebinger M, Köhrmann M, et al. Quantitative measurements of relative fluid-attenuated inversion recovery (FLAIR) signal intensities in acute stroke for the prediction of time from symptom onset. *J Cereb Blood Flow Metab*. 2013;33:76–84.
9. Albach FN, Brunecker P, Usnich T, Villringer K, Ebinger M, Fiebich JB, et al. Complete Early Reversal of Diffusion-Weighted Imaging Hyperintensities After Ischemic Stroke Is Mainly Limited to Small Embolic Lesions. *Stroke*. 2013;44:1043–8.

**Submit your next manuscript to BioMed Central
and take full advantage of:**

- Convenient online submission
- Thorough peer review
- No space constraints or color figure charges
- Immediate publication on acceptance
- Inclusion in PubMed, CAS, Scopus and Google Scholar
- Research which is freely available for redistribution

Submit your manuscript at
www.biomedcentral.com/submit

