

CASE REPORT

Isolated brachiocephalic artery dissection presenting as acute stroke

Hariharasudan Mani,¹ Sharat Ahluwalia²

¹Department of Internal Medicine, Marshfield Clinic, Eau Claire, Wisconsin, USA

²Department of Neurology, Marshfield Clinic, Eau Claire, Wisconsin, USA

Correspondence to
Dr Hariharasudan Mani,
dr_harisudan@yahoo.co.in

Accepted 7 August 2015

SUMMARY

Isolated brachiocephalic artery dissection is an extremely rare condition. Its presentation as an acute stroke can pose a significant diagnostic challenge in patients because of its rarity. We present a case of isolated spontaneous brachiocephalic artery dissection presenting as acute cerebrovascular accident. This case also illustrates the treatment dilemma brachiocephalic artery dissection can present, whether to choose antithrombotic/anticoagulation therapy and/or surgery, and also the dilemma in blood pressure management.

BACKGROUND

Spontaneous dissection of the internal carotid and vertebral arteries is a common cause of ischaemic strokes, particularly in children and young adults, accounting for approximately 20% of these strokes.¹ In studies from North America and Europe, the mean age of individuals affected by dissection was 44–46 years;^{1–3} however, isolated spontaneous brachiocephalic artery dissection is very rare. Ischaemic stroke secondary to supra-aortic dissection (SAD) accounts for approximately 10–25% of patients under 50 years of age.⁴ SAD commonly involves the internal carotid artery and, less commonly, the vertebral and common carotid arteries. Common causes of SAD are trauma, sports injuries, neck manipulation and connective tissue or vascular disorders. Brachiocephalic artery dissection is very rare, and few reports exist in the literature.

CASE PRESENTATION

A 41-year-old obese man with undiagnosed hypertension presented to the emergency department for symptoms of ataxia, slurred speech and left facial weakness. He had noticed the symptoms the day before at work, but did not seek immediate medical attention. He sought medical help the next morning because of persistence of the symptoms. Family history was notable for his grandparents having had strokes in their 60s, but the cause was not known. He reported no history of coagulopathy, aortic dissection or connective tissue disorders in his family. He had no history of antecedent trauma. He was a non-smoker and denied using illicit drugs. His blood pressure at presentation was 190/119 mm Hg, and he had frequent premature ventricular contractions on ECG. On examination, he was noted to have left facial asymmetry with upper motor facial palsy. Minimal dysarthria was noted, and no motor or sensory deficits in his extremities were present. There was no presence of

cerebellar signs. On standing, he had a tendency to drift to the left. Brain CT revealed acute ischaemic infarct in the right basal ganglia. He was beyond the window for treatment with recombinant tissue plasminogen activator (rt-PA), so he was treated with aspirin along with anticoagulation with heparin.

INVESTIGATIONS AND TREATMENT

As part of the evaluation, the patient was noted to have a difference in systolic blood pressure of >20 mm Hg between his upper extremities. This prompted further evaluation with angiography of the chest, which revealed isolated brachiocephalic artery dissection on the right with a slight extension into the proximal common carotid artery (figure 1). The thoracic aorta was normal. The patient's other work-up including hypercoagulopathy and echocardiogram revealed no abnormalities. He was treated with heparin anticoagulation and later bridged with Coumadin, to which he responded fairly well. Except for minimal residual dysarthria and facial asymmetry, which was persistent at the time of discharge 4 days later, the patient's overall symptoms improved. He was involved in rehabilitation and is currently being followed through the outpatient department. His dissection is known to have happened spontaneously.

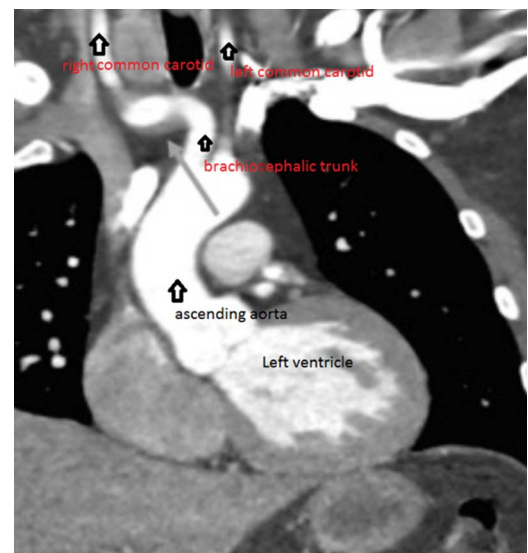


Figure 1 Angiography of the chest showing isolated brachiocephalic artery dissection on the right with a slight extension into the proximal common carotid artery.



To cite: Mani H, Ahluwalia S. *BMJ Case Rep* Published online: [please include Day Month Year] doi:10.1136/bcr-2014-208815

DISCUSSION

Spontaneous dissection of common carotid artery most commonly presents with headache and/or neck pain in 60–90% of patients.^{1–5} Other manifestations include Horner's syndrome, cerebrovascular accidents and subarachnoid haemorrhage. In adults, approximately 2% of ischaemic strokes are caused by cervical artery dissection. In one study of spontaneous cervical artery dissection, cerebral ischaemia was noted in 67% of patients, with transient ischaemic attacks (TIAs) and cerebral infarction in 23% and 56%, respectively.¹

Aortic dissection commonly presents with tearing chest pain;^{6–7} other presenting symptoms include syncope, cerebrovascular accident, aortic insufficiency, cardiac tamponade or heart failure. In one study, up to 10% of patients presented with neurological symptoms, but without chest pain.⁸ SAD is characterised by the presence of an intramural haematoma due to an intimal tear in the artery wall. Subsequent ischaemic stroke is believed to be caused due to the thromboembolism from the intimal tear rather than by haemodynamic factors. Antithrombotic therapy, with either anticoagulation or antiplatelet drugs, along with possible endovascular techniques such as angioplasty or stenting,^{9–10} has been used as treatment for ischaemic stroke and TIA caused by cervical arterial dissection. In theory, anticoagulation may prevent occlusion of a stenotic vessel and minimise distal embolisation. Antithrombotic/anticoagulation is the treatment of choice in such situations, since expansion of the intramural haematoma is rather a theoretical concern.⁴ Type A ascending aortic dissection is a surgical emergency¹¹ and is treated with a surgical graft. Any anticoagulation/antiplatelet is discontinued with involvement of aortic dissection.

There are few reports in the literature of isolated dissection of the brachiocephalic artery presenting with stroke and treated with anticoagulation. In one other reported case of spontaneous brachiocephalic artery dissection, initial improvement with thrombolysis did occur and subsequent worsening was noticed. It was attributed possibly to the flow disturbance from intramural haematoma.⁴ In our case, the patient did have improvement of his symptoms with anticoagulation, although rt-PA was not used. Brachiocephalic artery dissection presents the dilemma of managing either with anticoagulation or surgery, depending on the involvement of the base of the ascending aorta.^{12–13} A pulse deficit or a difference in blood pressure of >20 mm Hg between arms could be a sign of aortic or brachiocephalic artery dissection, although other conditions that could cause this deficit include subclavian artery stenosis or peripheral artery disease.¹⁴ There have been few cases of residual brachiocephalic artery dissection in the setting of post-type A aortic dissection repair;¹⁵ and there have been reports of brachiocephalic artery aneurysm with contained rupture managed by surgical graft.^{12–13}

Increase in blood pressure is a common finding in patients with acute stroke. For patients who will be receiving antithrombotic therapy, it is recommended to decrease systolic blood pressure below 185 mm Hg and diastolic blood pressure below 110 mm Hg. In patients not treated with antithrombotics, decreasing the blood pressure is only recommended in the presence of systolic blood pressure >220 mm Hg or diastolic blood pressure >120 mm Hg, or in the presence of aortic dissection, acute ischaemic coronary disease, or heart failure.¹⁶ In our patient, the blood pressure decreased to 150/82 mm Hg within hours of presentation without treatment. We could not find any guidelines in the literature for managing blood pressure in SAD.

This case represents a rare presentation of brachiocephalic artery dissection and the treatment with antithrombotic and/or anticoagulation therapy as the choice in the absence of aortic involvement. Also, blood pressure targeting still remains controversial given the conflicting conditions such as ischaemic stroke and arterial wall dissection.⁴

Patient's perspective

I can't express enough thanks and gratitude to Dr Mani for all the help and care I was given. I didn't know it was as serious as it turned out. Other doctors have told me I was very lucky Dr Mani found what he did when he did. It may have very well been life saving. So my thanks from the bottom of my heart. I hope my case can be published as something that can help others.

Learning points

- ▶ This case illustrates the potential for spontaneous isolated brachiocephalic artery dissection as a rare but possible cause of stroke.
- ▶ Standard stroke evaluation protocol should still be implemented.
- ▶ A pulse deficit or a >20 mm Hg difference in blood pressure between arms should prompt further evaluation with angiography. Routine CT angiography in all patients with stroke is still not recommended.
- ▶ Anticoagulation and tissue plasminogen activator (rt-PA) with/without antiplatelet is still a reasonable option in such patient presentation.

Competing interests None declared.

Patient consent Obtained.

Provenance and peer review Not commissioned; externally peer reviewed.

REFERENCES

- 1 Lee VH, Brown RD Jr, Mandrekar JN, *et al.* Incidence and outcome of cervical artery dissection: population-based study. *Neurology* 2006;67:1809–12.
- 2 Arnold M, Kappeler L, Georgiadis D, *et al.* Gender differences in spontaneous cervical artery dissection. *Neurology* 2006;67:1050–2.
- 3 Touze E, Gauvrit JY, Moulin T, *et al.*, Multicenter Survey on Natural History of Cervical Artery Dissection. Risk of stroke and recurrent dissection after a cervical artery dissection; a multicenter study. *Neurology* 2003;61:1347–51.
- 4 Sansone T, Baroncelli S, Tozzetti C, *et al.* Challenges in management of ischemic stroke secondary to brachiocephalic artery dissection. *Intern Emerg Med* 2013;8:181–3.
- 5 Mokri B, Sundt TM Jr, Houser OW, *et al.* Spontaneous dissection of the cervical internal carotid artery. *Ann Neurol* 1986;19:126–38.
- 6 Larson EW, Edwards WD. Risk factors for aortic dissection: a necropsy study of 161 cases. *Am J Cardiol* 1984;53:849–55.
- 7 Hagan PG, Nienaber CA, Isselbacher EM, *et al.* The international registry of acute aortic dissection (IRAD): new insights into an old disease. *JAMA* 2000;283:897–903.
- 8 Gaul C, Dietrich W, Friedrich I, *et al.* Neurological symptoms in type A aortic dissection. *Stroke* 2007;38:292–7.
- 9 Donas KP, Mayer D, Guber I, *et al.* Endovascular repair of extracranial carotid artery dissection; current status and level of evidence. *J Vasc Interv Radiol* 2008;19:1693–8.

- 10 Engelter ST, Brandt T, DeBette S, *et al.* Antiplatelets versus anticoagulation in cervical artery dissection. *Stroke* 2007;38:2605–11.
- 11 Nienaber CA, Eagle KA. Aortic dissection: new frontiers in diagnosis and management: part 1: from etiology to diagnostic strategies. *Circulation* 2003;108:628–35.
- 12 Hlhashi S, Yoshida Y, Mitsuoka H. Dissecting aneurysms at the bases of the brachiocephalic artery and the left common carotid artery due to localized dissection of the aortic arch; report of a case. *Kyobu Geka* 2007;60:575–8.
- 13 Hirose T, Tabayashi N, Yoshikawa Y, *et al.* Isolated dissecting aneurysm of the brachiocephalic artery associated with contained rupture. *Gen Thorac Cardiovasc Surg* 2012;60:225–7.
- 14 Clark CE, Taylor RS, Shore AC, *et al.* Association of a difference in systolic blood pressure between arms with vascular disease and mortality: a systemic review and meta-analysis. *Lancet* 2012;379:905–14.
- 15 Neri E, Sani G, Massetti M, *et al.* Residual dissection of the brachiocephalic arteries: significance, management, and long-term outcome. *J Thorac Cardiovasc Surg* 2004;128:303–12.
- 16 Jauch EC, Saver JL, Adams HP Jr, *et al.* Guidelines for the early management of patients with acute ischemic stroke: a guideline for healthcare professionals from the American Heart Association/American Stroke Association. *Stroke* 2013;44:870–947.

Copyright 2015 BMJ Publishing Group. All rights reserved. For permission to reuse any of this content visit <http://group.bmj.com/group/rights-licensing/permissions>.

BMJ Case Report Fellows may re-use this article for personal use and teaching without any further permission.

Become a Fellow of BMJ Case Reports today and you can:

- ▶ Submit as many cases as you like
- ▶ Enjoy fast sympathetic peer review and rapid publication of accepted articles
- ▶ Access all the published articles
- ▶ Re-use any of the published material for personal use and teaching without further permission

For information on Institutional Fellowships contact consortiasales@bmjgroup.com

Visit casereports.bmj.com for more articles like this and to become a Fellow