

Limb-Shaking TIA Presenting as Hemichorea–Hemiballismus: TIA Chameleons Diagnostic Challenge in the Emergency Department

Joaquin Valle Alonso, MD,* Francisco Javier Fonseca del POZO, MD, PhD,†
Jesús Carmona Simón, MD,‡ Saray Valenzuela, MD,§ Francisca Perez Gomez, MD,‡
and Elisa Lopera, MD||

Background: demonstrate the importance of considering limb-shaking syndrome in the differential diagnosis of patients who present to the emergency department (ED) with hyperkinetic movements. *Methods:* In this article, we describe a diagnostic challenge in the ED in which a patient presents with hyperkinetic movements that are initially diagnosed as hemichorea–hemiballismus (HCHB) but are subsequently found to be limb-shaking syndrome with important therapeutic opportunities. *Results:* Following a diagnosis of left carotid obstruction, the patient underwent left carotid endarterectomy 5 days after admission. Six months after surgery, the patient had no further symptoms, and an ultrasound scan and magnetic resonance angiography have confirmed no restenosis. *Conclusion:* Limb shaking is an uncommon form of transient ischemic attack that should be recognized and differentiated from conditions such as focal motor seizures. Recognition will almost invariably indicate carotid artery occlusion, and timely treatment may not only abolish the attacks in patients but also reduce their risk of stroke. HCHB represents a spectrum of hyperkinetic movement disorders varying in the severity of choreic and/or ballistic movements. The presented case includes limb-shaking syndrome in the differential diagnosis and prompts for further investigations to complete the assessment. **Key Words:** TIA—limb shaking—hemichorea–hemiballismus—carotid stenosis—hyperkinetic movements—stroke.

© 2015 by National Stroke Association

From the *Department of Accident and Emergency Medicine, Southport and Ormskirk, NHS Trust, Southport, UK; †Department of Critical Care and Emergency Medicine, Ambulance service, Montoro, Córdoba; ‡Department of Primary Care, Primary Care Health Center, Montoro, Córdoba; §Department of Neurology, Hospital Reina Sofía, Córdoba; and ||Department of Critical and Emergency Medicine, Hospital Valle de los Pedroches, Pozoblanco, Spain.

Received April 25, 2015; revision received June 13, 2015; accepted July 7, 2015.

Address correspondence to Joaquin Valle Alonso, MD, Department of Accident and Emergency Medicine, Southport and Ormskirk, NHS Trust, Southport, UK. E-mail: joa51274@hotmail.com.

1052-3057/\$ - see front matter

© 2015 by National Stroke Association

<http://dx.doi.org/10.1016/j.jstrokecerebrovasdis.2015.07.006>

In general, recognition and diagnosis of hyperkinetic disorders is challenging. Some reviews have subclassified these movements into jerky and nonjerky syndromes. The former comprises myoclonus, chorea, and tics, whereas nonjerky hyperkinetic disorders include tremor and dystonia. “Limb-shaking” episodes are recurrent, involuntary, irregular movements described by patients as shaking, trembling, twitching, or flapping. They are associated with severe carotid artery disease, stenosis, or occlusion of the contralateral artery with exhausted intracranial vasomotor reactivity; hence, these are transient ischemic attacks (TIAs) in the carotid territory reflecting hemodynamic failure. In this article, we

describe a diagnostic challenge in the emergency department (ED) in which a patient presents with hyperkinetic movements which are initially diagnosed as hemichorea–hemiballismus (HCHB) but subsequently diagnosed as limb-shaking syndrome with important therapeutic opportunities.

Case Report

A 61-year-old male patient presented to the ED following a 6-hour history of intermittent involuntary right upper limb movements. His medical history included type II diabetes mellitus, coronary artery disease with percutaneous coronary angioplasty to the right coronary artery 2 years before, and hypertension. His medication history included losartan/hydrochlorothiazide 50/12.5 mg/daily, metformin 850 mg twice a day, bisoprolol 2.5 mg daily, and aspirin 75 mg daily. There was no history of preceding trauma or stroke-related symptoms. The abnormal movements consisted of a brief prodromal dizzy sensation after which the right arm began to shake at a rate of 2–3 Hz followed by periodic involuntary right side hyperkinetic movements and then immediate return to normal function. There was no altered consciousness, no focal neurologic deficit, and no provoking factors were determined. Initial blood tests revealed normal values for white blood cell count and inflammatory markers and a blood glucose of 15.6 mmol/L (281 mg/dL). Other routine blood tests including sodium, potassium, calcium, magnesium, and phosphate concentrations, and thyroid and parathyroid hormone tests were normal as well as liver and kidney functional status. There were no ketones detected in urinalysis, and urine pH was normal. Computerized tomography revealed in the axial plane a small hypodense lesion in left caudate nucleus and periventricular white matter of the left cerebral hemisphere suggesting ischemic etiology (Fig 1).

Initially the patient was considered to have partial seizures and phenytoin infusion was started according to local protocols, and the patient was admitted at the observation ward for treatment; however, continuous abnormal movements persisted despite the treatment with phenytoin infusion. Neurologist on call was requested. The movements were rapid, irregular, involuntary, nonstereotypical, nonpurposeful, resembling writhing movements, nonpatterned with variable speed, involving more proximal muscle groups of the right upper limb, and occasionally the patient incorporated writhing movements into semi-purposeful movement; after twisting his right arm into the air and he would run his hand over his head or wave at the doctors in the ward. The diagnosis of vascular HCHB was initially established. Initial treatment included starting daily clopidogrel 75 mg and haloperidol 3.5 mg. Magnetic resonance imaging (MRI) and carotid ultrasound were requested as outpatient investigations with neurology follow-up. After

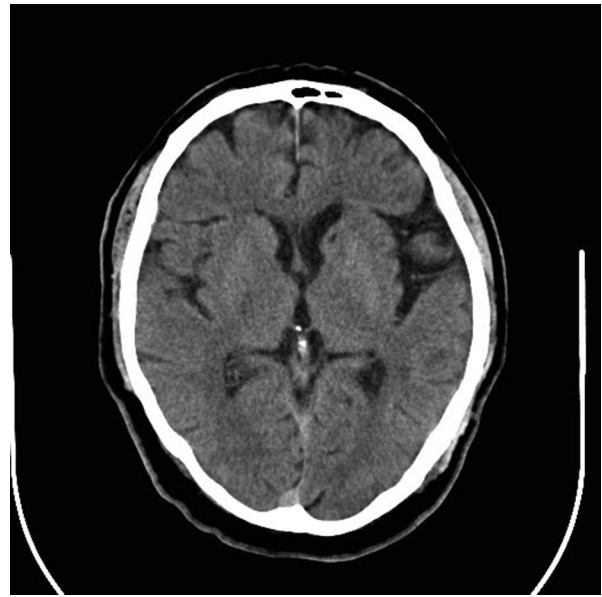


Figure 1. Head computerized tomography showing hypodense areas in the semioval center and left corona radiata, left frontal cortex white matter, left caudate and lenticular nucleus presumably of chronic ischemic hypertensive etiology.

24 hours in the observation ward, the patient was asymptomatic and discharged home; however, 48 hours later, the patient re-presented to the ED complaining of 2 episodes of left-sided visual disturbance. He described the symptoms as “looking through broken glass,” which persisted for 10 minutes, followed by a mild left arm weakness lasting 5 minutes with complete recovery.

The co-occurrence of left hyperkinetic movements with a previous diagnosis of HCHB and 2 episodes consistent

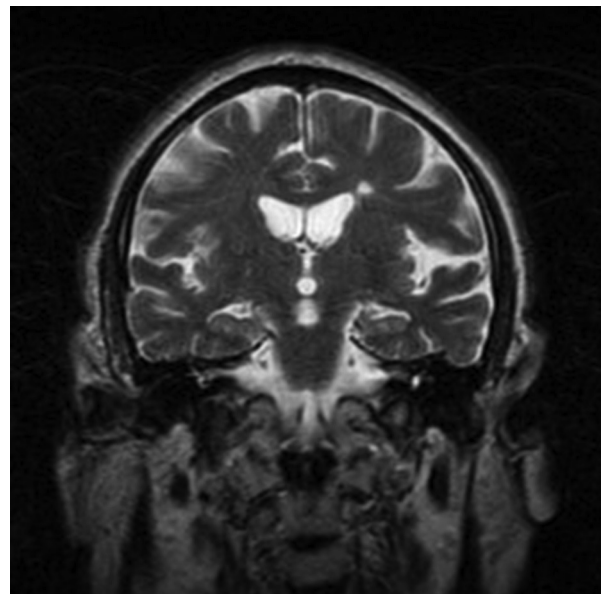


Figure 2. Head magnetic resonance imaging reporting multiple bilateral ischemic lesions and small old infarcts, predominantly subcortical located in the white matter of both hemispheres.

with contralateral amaurosis fugax and right arm weakness implicated 2 distinct anatomic areas in the carotid territory and suggested a different vascular etiology. The patient was admitted under the neurology team and had an urgent computerized tomography of brain which appeared unchanged from the previous scan. An urgent MRI was performed, which showed a hyperintense lesion in periventricular white matter of the left cerebral hemisphere (T2 weighted in the coronal plane) (Fig 2). Ultrasound scan of the carotids (Fig 3) showed 80%-90% left internal carotid artery (ICA) stenosis, and 50% stenosis at the same level in the right ICA. MR angiogram showed that the Circle of Willis was normal and confirmed the carotid obstruction (Fig 4).

This patient had low-flow TIAs, also referred to as “limb-shaking TIAs.” This is an unusual form of TIA that can occur in patients with severe carotid occlusive disease. This type of TIA is often precipitated by postural change and can sometimes be relieved by sitting or lying down. Despite this postural relationship, there is usually no associated postural drop in blood pressure as in the case reported. The final diagnosis was limb-shaking TIA with bilateral carotid obstruction presenting as HCHB. TIA and stroke with atypical presentations that mimic other disease processes may be termed “TIA chameleons,” for like the chameleon, these disguised TIA may change and evolve with time. As low-flow TIAs are asso-

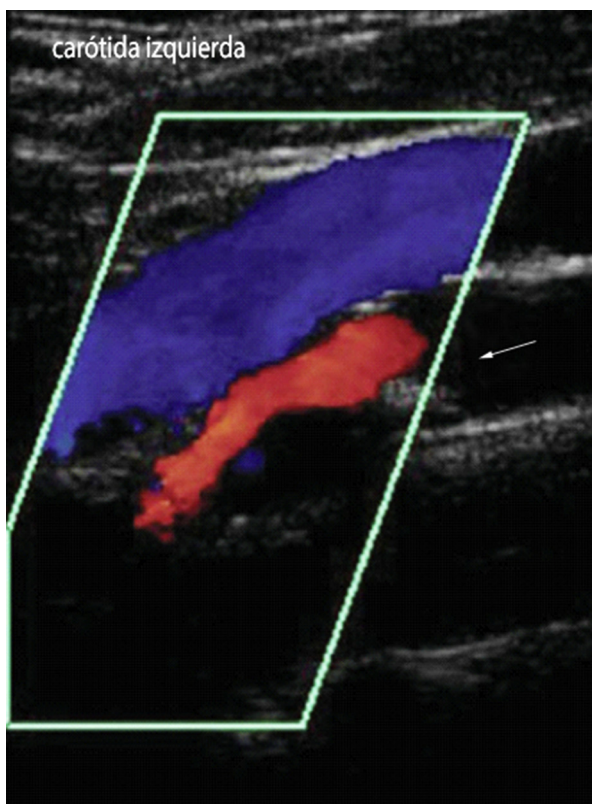


Figure 3. Doppler ultrasound scan of the carotids showed 80%-90% left internal carotid artery stenosis. The arrow is pointing at the left internal carotid artery ICA obstruction showing an 85% stenosis.

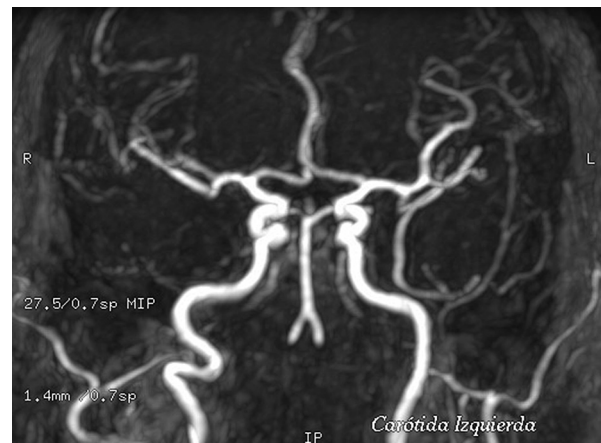

Figure 4. The magnetic resonance angiography describes generalized vascular atheromatosis, and the left internal carotid artery has 2 plaques at the origin with contiguous levels of stenosis.

ciated with carotid occlusive disease, they carry a high risk of stroke. The aim of treatment was 2-fold: to reduce the risk of stroke and to abolish the symptoms, both of which can be achieved by maintaining or improving cerebral blood flow. Management was focused on careful control of blood pressure and urgent surgical revascularization. The patient underwent a left carotid endarterectomy 5 days after admission. Six months after surgery, the patient had no further symptoms; an ultrasound scan and MR angiography have confirmed no restenosis.

Discussion

Vascular hemichorea, or hemiballism, is usually related to an ischemic or hemorrhagic lesion of the basal ganglia and adjacent white matter in the territory of the middle or the posterior cerebral artery.¹ In contrast to classical textbook descriptions of hemiballism, the majority of patients with vascular chorea have lesions outside the subthalamus.² Hemiballism is one of the most dramatic disorders in neurology. It is not frequently seen in the emergency room. Typically, the patient presents with an acute or subacute onset of flinging movements of one side of the body. These tend to occur in both the arm and leg, with variable involvement of the face. Movements often have a rotatory component and predominantly affect proximal muscles. They can be severe enough to cause the patient to strike walls and bedrails, causing bruising and lacerations of the limb. Movements increase with action and stress and are only rarely suppressible for more than a few seconds. They disappear in sleep. Hemichorea refers to movements that are similar in character but lower in amplitude, affecting both the distal and proximal limb. There is probably little pathophysiologic difference between the 1 movement disorders, as they share common etiologies, prognosis, and treatment. In fact, they can often be present in the same patient, with hemiballism

more prominent early in the presentation, and the lower amplitude hemichorea emerging as the disorder resolves.

Hemiballism is the prototypical acute stroke manifestation, and although it is classically believed to be because of involvement of the subthalamic nucleus,³ numerous other localizations have been identified including the caudate nucleus, putamen, and thalamus.^{3,4} Chorea most commonly reflects vascular insults to the striatum, globus pallidus, or thalamus. A clinical–radiological correlation study showed that subthalamic nucleus, caudate, putamen, and cortical lesions contralateral to the affected side were the sites most commonly associated with hemichorea,⁵ a localization that is similar to hemiballism, which is expected given the close phenomenological relationship of the 2 disorders. Both chorea and ballism from vascular insults are usually self-limited and slowly improve over time. A study⁶ of 31 patients with acute caudate stroke showed that that small-artery disease and a cardiac source of embolism are the main causes of caudate ischemic stroke, and ipsilateral ICA disease (>50% stenosis or occlusion, large-artery disease) was the only potential cause of infarct in 2 patients (8%).

Limb-shaking TIA has been described as a rare clinical feature of TIA. Since Fisher⁷ first reported a paroxysmal limb-shaking syndrome associated with carotid stenosis in 1962, a number of scholars have focused on this type of TIA, which manifests as chiefly positive neurologic symptoms unlike the typical negative ischemic manifestations. Limb-shaking TIA is characterized by its brief, stereotyped, and arrhythmic involuntary movements in one or more limb(s) and has been associated with high-grade stenosis or occlusion of the ICA.

There have been case reports of sustained, rather than intermittent, movement disorders related to hypoperfusion. Pareés et al⁸ described a patient presenting with continuous choreiform movement of an arm and leg, and severe stenosis of the contralateral extracranial ICA. Similarly, Morigaki et al⁹ and Galea et al¹⁰ described patients with continuous hemichorea, with resolution of symptoms being either immediate or delayed by up to 6 months following endarterectomy. A more recent case reported a 61-year-old patient with recurrent amaurosis fugax and hemichorea with a final diagnosis of limb-shaking TIA.¹¹ The main differential diagnosis, which was also considered in this patient, is focal motor seizures. Clinically, the main differentiating features between the 2 conditions are lack of Jacksonian march and no facial involvement in limb-shaking TIAs. In addition, limb-shaking TIAs are often associated with postural change, whereas focal motor seizures are not. Electroencephalogram recordings during limb-shaking TIAs do not show epileptic discharges and, if a treatment trial is done, anticonvulsants are usually ineffective.

Regarding the treatment, carotid endarterectomy is the most common therapeutic strategy. It is critical to identify

patients quickly as they benefit from carotid revascularization.^{12–14} Individuals with carotid occlusion and recurrent symptoms may be managed with changes to their antihypertensive medications in an effort to maintain adequate cerebral perfusion.¹⁵ Revascularization by extracranial–intracranial anastomosis has been reported to relieve limb-shaking attacks and can be considered in recurrently symptomatic patients.¹⁶

Limb-shaking TIAs can be confused with motor seizures and jerky movement disorders. The classical phenomenology of limb-shaking TIA is tremor and that of HCHB is chorea. This case presented in ED with chorea rather than tremor, initially misinterpreted in the ED by the evaluating clinician as seizures, subsequently evaluated by neurologist and diagnosed as HCHB of vascular etiology, and after further investigations, an underlying bilateral carotid obstruction was demonstrated.

Conclusions

Suspected TIA is a common diagnostic challenge for physicians in neurology, stroke medicine, emergency medicine, and primary care. It is essential to identify TIAs promptly because of the risk of ischemic stroke, emphasizing the importance of urgent investigation and preventive treatment. In addition, it is also important to identify TIA “mimics,” to avoid unnecessary and expensive investigations, incorrect diagnostic labeling, and inappropriate long-term treatment. We must remain vigilant of situations where TIAs can present unusually, such as in the reported case (TIA chameleons). The most common TIA chameleons are limb-shaking TIAs, TIAs with altered conscious level or other brainstem symptoms, spontaneous limb movements or posturing due to brainstem ischemia, and the capsular warning syndrome.

Limb shaking is an uncommon form of TIA that should be recognized and differentiated from conditions such as focal motor seizures. We add to the literature another case of this rare condition. Recognition will almost invariably indicate carotid artery occlusion, and timely treatment may not only abolish the attacks in patients but also reduce their risk of stroke. TIA chameleons imitate other diseases because of their tempo of onset (eg, gradual progression or stuttering) or have symptoms that do not necessarily implicate an arterial territory. It is uncommon to consider these patients for thrombolysis, but their recognition enables patients to benefit from secondary prevention. Hemichorea–hemiballismus represents a spectrum of hyperkinetic movement disorders varying in the severity of choreic and/or ballistic movements that are uncommon in ED. The presented case includes limb-shaking syndrome in the differential diagnosis and prompts for further investigations to complete the assessment.

References

1. Park SY, Kim HJ, Cho YJ, et al. Recurrent hemichorea following a single infarction in the contralateral subthalamic nucleus. *Mov Disord* 2009;24:617-618.
2. Ghika-Schmid F, Ghika J, Regli F, et al. Hyperkinetic movement disorders during and after acute stroke: the Lausanne Stroke Registry. *J Neurol Sci* 1997;146:109-116.
3. Vidakovic A, Dragasevic N, Kostic VS. Hemiballism: report of 25 cases. *J Neurol Neurosurg Psychiatry* 1994; 57:945-949.
4. Lazzarino LG, Nicolai A. Hemichorea-hemiballism and anosognosia following a contralateral infarction of the caudate nucleus and anterior limb of the internal capsule. *Rev Neurol* 1991;61:9-11.
5. Chung SJ, Im JH, Lee MC, et al. Hemichorea after stroke: clinical radiological correlation. *J Neurol* 2004; 251:725-729.
6. Kumral E, Evyapan D, Balkir K. Acute caudate vascular lesions. *Stroke* 1999;30:100-108.
7. Fisher CM. Concerning recurrent transient cerebral ischemic attacks. *Can Med Assoc J* 1962;86:1091-1099.
8. Pareés I, Pujadas F, Hernández-Vara J, et al. Reversible hemichorea associated with extracranial carotid artery stenosis. *J Neurol Sci* 2011;300:185-186.
9. Morigaki R, Uno M, Suzue A, et al. Hemichorea due to hemodynamic ischemia associated with extracranial carotid artery stenosis. Report of two cases. *J Neurosurg* 2006;105:142-147.
10. Galea I, Norwood F, Phillips MJ, et al. Pearls and Oysters: resolution of hemichorea following endarterectomy for severe carotid stenosis. *Neurology* 2008;71:e80-e82.
11. Littleton ET, Glover N, Tiwari A. Recurrent amaurosis fugax and hemichorea: limb-shaking TIA. *Pract Neurol* 2015;15:218-220.
12. Klijn CJ, Kappelle IJ, van Huffelen AC, et al. Recurrent ischemia in symptomatic carotid occlusion. Prognostic value of hemodynamic factors. *Neurology* 2000; 55:1806-1812.
13. Paty PS, Adeniyi JA, Mehta M, et al. Surgical treatment of internal carotid artery occlusion. *J Vasc Surg* 2003; 37:785-788.
14. Yadav JS, Wholey MH, Kuntz RE, et al. Protected carotid-artery stenting versus endarterectomy in high-risk patients. *N Engl J Med* 2004;351:1493-1501.
15. Leira EC, Ajax T, Adams HP. Limb-shaking carotid transient ischemic attacks successfully treated with modification of the antihypertensive regimen. *Arch Neurol* 1997; 54:904-905.
16. Naylor AR, Rothwell PM, Bell PF. Overview of the principal results and secondary analyses from the European and North American randomized trials of endarterectomy for symptomatic carotid stenosis. *Eur J Vasc Endovasc Surg* 2003;26:115-224.